II. *Observations on the Anatomy and Development of Apteryx.*

By T. JEFFERY PARKER, *B.Sc.*, *F.R.S.*, *Professor of Biology in the University of Otago, Dunedin, New Zealand.*

[PLATES 3–19.]

Received March 20,—Read April 17, 1890.

CONTENTS.

I.—INTRODUCTORY.

THE chief materials for the present investigation consist of a number of embryos of the three common species of *Apteryx* which have come into my possession during the last three or four years. For some time I only succeeded in obtaining two or three specimens of advanced stages, and it was only when I was fortunate enough to secure the services of Mr. RICHARD HENRY, of Lake Te Anau, as collector, that my material became copious enough to be worth working up. Even now my observations are in many respects very imperfect owing to the lack of a sufficient number of specimens, many of the most important stages being represented only by a single embryo.

Since communicating a preliminary note (28)* on the subject to the Royal Society I have found it necessary to extend my investigations, so as to include certain points in the structure of the adult, especially the pterylosis and the characters of the wing, the sternum, shoulder-girdle, and skeleton of the fore-limb, the muscles of the wing, and the brain.

I beg to return my sincere thanks to the Council of the Royal Society for the grant from which the expenses of the investigation were defrayed; to Madame MÜLLER, for a half ripe embryo of *Apteryx oweni*; to Sir WALTER BULLER, for two advanced embryos of *A. bulleri*; to Professor HUTTON, for a wing of the rare *A. haastii*; to Sir JAMES HECTOR, for two skeletons, and for the opportunity of examining the collections in the Colonial Museum, Wellington; to Mr. H. O. FORBES, for similar facilities enjoyed at the Canterbury Museum, Christchurch, and for a skeleton of *A. oweni*, in a very interesting stage of development; to Mr. T. W. KIRK, for valuable help during my work at the Wellington Museum; to Mr. T. F. CHEESEMAN, for two living specimens of *A. bulleri*; to Professor MAX FÜRBRINGER, for a copy of his magnificent work on the anatomy and classification of Birds; to my colleague, Dr. J. H. SCOTT, for valuable help in connection with the literature of the subject; and to my pupil, Mr. J. M. BEATTIE, for working out the percentages in Table B, p. 41.

---

* The figures in brackets refer to the bibliographical list at the end of this paper (p. 117).

It is only right to state that my obligations to my collector, Mr. HENRY, are out of all proportion to the sums paid to him for specimens. It has been of great advantage to me in many stages of the enquiry to have the opportunity of corresponding with so excellent a field-naturalist.

Perhaps I may also be allowed to mention that I have enjoyed the privilege of frequent correspondence with my Father on the subject-matter of my work. My chief hope in connection with the present paper is that it may be deemed worthy to serve as a supplement to the long series of researches on the anatomy of birds to which so many years of his life have been devoted.

II.—GENERAL DESCRIPTION OF THE STAGES EXAMINED.

The embryos hitherto obtained naturally group themselves into ten stages (A to K). An eleventh stage (L) is furnished by a bird a few weeks old, a twelfth (M) by the skeleton of an adolescent specimen, and a thirteenth (N) and fourteenth (O) by odd bones of young birds. The adult may be considered as constituting a fifteenth stage.

The following table gives a list of the specimens examined :—

Stage.	Number of Specimens.			
	A. bulleri.[*]	*A. australis.*	*A. oweni.*	
A	..	1	..	Embryos
B	..	1	..	
C	..	1	..	
D	..	..	1	
E	..	..	1	
F	..	..	1	
G	..	1	1	
H	1	..	1	
I	1	2	..	
K	1	2	..	Time of hatching
L	..	1	..	Several weeks old
M	..	..	1	Skeleton of young specimen
N	..	..	1	Skull and pelvis only of young specimen
O	..	..	1	Loose bones of young specimen
Adult	2[†]	1	..	Entire specimens
	1	3	3	Skeletons

In addition to these I have examined several wings taken from stuffed specimens or skins, and two skeletons the species of which are uncertain. One, in the Wellington Museum, was prepared by the late Dr. F. J. KNOX, who named it

---

[*] This species is better known as *A. mantelli*, but Mr. SHARPE has unfortunately, although no doubt correctly, found it necessary to change its name.

[†] Both these specimens had to be stuffed, so that only certain parts were available for examination.

A. maxima. It appears to be a sub-adult *A. bulleri.* The other I have provisionally referred to *A. haastii* for reasons given hereafter (p. 39).

The chief gaps are between stages C and D and between stages G and H. With these exceptions, the series is fairly complete.

All the embryos were preserved in alcohol. As they had to be removed from the egg by the collector, the employment of special fixing reagents was inadmissible. They were for the most part well preserved, but not sufficiently well for the purposes of exact histological study. For sectioning they were stained *in toto* with borax-carmine, and imbedded in paraffin, serial sections being cut with the Thoma-Jung microtome. MEYER's albumen and glycerine fixative was used. In most cases the sections were cut to a thickness of about $\frac{1}{40}$ to $\frac{1}{70}$ mm.

The embryos were drawn as a whole before cutting, the smaller ones (stages A–C) both as opaque objects and after being rendered transparent by turpentine. All microscopic drawings were made by the aid of ABBE's camera lucida.

Stage A (Plate 3, fig. 1).

The single embryo belonging to this stage corresponds in most respects to a chick of the fourth day.*

The body is so bent upon itself that the posterior cephalic and thoracic regions are approximately parallel to one another, and the end of the curved tail is almost in contact with the top of the head. The cerebral flexure is well marked, the angle between the fore and hind brain being acute. (*Cf.* fig. 17, Plate 4.) The total length of the embryo, measured along the curve of the back from the nostril to the end of the tail, is about 20 mm. In its naturally curved condition it is about 6 mm. across.

The lateral curvature of the body is very much less than in the corresponding stage of the Chick. In the latter, at about the fourth day, a sagittal section of the whole embryo cuts the notochord, mesoblastic somites, myelon, &c., in very various planes. In the present instance nearly the whole of the notochord, except its caudal portion, was displayed in a single section.

The number of mesoblastic somites was difficult to count in the entire embryo, as it was not examined fresh, but by examining in turpentine by transmitted light it could be made out with tolerable certainty to be about forty-four—certainly not fewer than forty-three, nor more than forty-five. That is to say, the total number of segments is already acquired, since the number of vertebræ in the adult skeleton is about forty-five.

The limbs are in a far less advanced condition than in FOSTER and BALFOUR's figure of the fourth day Chick (10, fig. 67). Each (fig. 1) has the form of a flattened,

---

* I have unfortunately no good series of figures of the external form of chick-embryos which could be taken as a standard of comparison. The embryos I have myself obtained differ considerably in point of development from the corresponding ages as described by FOSTER and BALFOUR.

almost semicircular bud, the hind (*H.L.*) being already slightly larger than the fore limb (*F.L.*).

The position of the limbs at this early stage is apparently somewhat unusual. The fore-limb springs from the Wolffian ridge over against the seventeenth to the nineteenth mesoblastic somites (*see* fig. 1, where the sixteenth somite is marked *mes.som.* 16), the hind limb over against the twenty-eighth to the thirty-sixth. In the Chick, according to FOSTER and BALFOUR'S figure, the fore-limb, at a corresponding or slightly later stage, is opposite the tenth to the thirteenth somites, the hind-limb opposite the twenty-third to the twenty-sixth, the total number of somites being forty, or only four fewer than in the present stage of *Apteryx*.

In the adult both of *Apteryx* and *Gallus* the fore-limb lies in the transverse plane of about the sixteenth or seventeenth vertebra, the hind-limb in that of about the thirtieth or thirty-second. Thus while in *Gallus* the limbs undergo, subsequently to the fourth day, a backward shifting equal to the length of about six to eight mesoblastic somites, in an *Apteryx* of the corresponding age the adult position is already attained.

The ontogenetic shifting of the limbs of birds is very generally taken as evidence of a corresponding phylogenetic shifting. If this conclusion is correct—and there seems no reason to doubt it—the fact just described would seem to show that the interval separating *Apteryx* from its hypothetical short-necked ancestor is a wider one than has intervened in the case of *Gallus*. It must be remembered, however, that, according to FÜRBRINGER (11, p. 977), a forward displacement of the limbs occasionally occurs instead of the usual backward displacement, especially in the case of species with degenerating wings.

The first two visceral folds (mandibular, *Mn.*, and hyoid, *Hy.*) are considerably larger than the third, fourth, and fifth (figs. 19-21, *Br.*, 1, 2, and 3). The superior maxillary process was not visible externally, nor can any trace of it be seen in sections; in this respect the resemblance is closer to a Chick of the third than to one of the fourth day (compare 10, figs. 56 and 67).

In the brain the mesencephal (figs. 1 and 17, *Mesen.*) is proportionally smaller than in the Chick in correspondence with the relatively smaller eyes. The auditory sac (*Au.*) has the usual characters, but the nasal sac (*Na.*) agrees in character and position with that of a Chick of the third day; there is no trace of the fronto-nasal process and no overlapping of the nostrils by the lateral projection of the eyes.

The diameter of the allantois (*All.*) was about five-sixths of the length of the head, *i.e.*, of much the same relative size as in a Chick of the fourth day.

The embryo was cut into a complete series of sagittal sections.

Stage B (Plate 3, fig. 2).

This embryo is apparently only a few hours older than that just described, being considerably less advanced than a Chick of the fifth day. Measured across the curve its length is about 7·2 mm.; if straightened out it would measure, from nostril to end of tail, about 24 mm.

The fronto-nasal process has barely begun to form, and there is still no trace of the superior maxillary process. The distinction between the mandibular and hyoid folds is less clear than in the previous stage, owing to the partial obliteration of the furrow between them. In the sections the post-hyoidean clefts (*Cl.* 2) are seen to meet in the middle ventral line (fig. 28), and the hyoidean folds are slightly produced backwards, forming an operculum-like flap (figs. 2, 28, and 29, *Operc.*) over the neck, beneath which there is a transverse crescentic slit (figs. 28 and 29, *Cl.* 1), placing the pharynx in free communication with the exterior. I have no recollection of seeing this condition of things described in any vertebrate embryo, and am disposed to attribute it to an injury, although it is rather difficult to account for the destruction of the delicate median isthmus between the ventral ends of the hyoidean and first branchial folds, placed as it is in a very inaccessible situation, without any corresponding injury to the folds themselves. The third visceral cleft (*Cl.* 3) is still open, but considerably reduced in size; the fourth (*Cl.* 4) is closed.

The allantois (*All.*) is now, as shown by the dotted outline, considerably larger than the head. In other respects there is very little advance.

Sections of this embryo were made parallel to the long axis of the head, with the result of getting longitudinal sections of the anterior cephalic (figs. 22–24), cervical (fig. 33) and middle caudal regions, and transverse sections of the posterior cephalic (figs. 26–31), thoracico-lumbar (figs. 31 and 32), and posterior caudal (fig. 32) regions.

Stage C (Plate 3, figs. 3 and 4).

In this embryo, which corresponds in general features with a Chick of about the sixth day, there is a considerable alteration in form, accompanied by a slight increase in size. The total length from nostril to end of tail, measured along the curve of the back, is now about 30 mm., the greatest length across the curve about 8 mm.

As compared with the previous stages, there is a slight diminution of the cranial flexure, the general axis of the head being now as nearly as possible at right angles to that of the neck.

The fronto-nasal process (figs. 3, 4, 35, and 36, *Fr.Na.P.*) has appeared as a prominent distinctly bilobed elevation, and the nasal sac (*Na.*) has, in consequence, become more deeply set, so as to have the appearance, externally, of a longitudinal slit, and not of an open pit. The superior maxillary process (figs. 3, 4, and 37) is also well developed, but runs much more nearly parallel to the mandibular arch (*Mn.*) than in the Chick.

The first visceral (mandibulo-hyoid) cleft (figs. 3, 4, and 39, *Cl.* 1) has the usual relation; the second, or post-hyoidean clefts (figs. 3, 4, 40, 41, and 42, *Cl.* 2) have a great vertical extent, and nearly meet with one another in the middle ventral line (fig. 40). The backward extension of the hyoidean fold visible in the previous stages has increased so as to form a true operculum (figs. 3, 4, 41, and 42, *Operc.*), which completely covers the third cleft (fig. 42, *Cl.* 3), so that it is invisible in an external view. The fourth cleft lies immediately behind the operculum, and is very probably only exposed by the shrinking of the latter: as in the previous stage it no longer communicates with the exterior.

The retention of so obviously amphibian a character as the opercular fold in the embryo of *Apteryx* appears to be a character of very considerable morphological interest. I have not met with any record of its occurrence in other Sauropsida.

The limbs are no longer mere semicircular buds, but have become elongated and flattened dorso-ventrally, and their distal ends are slightly dilated. The disparity in size between the two pairs of limbs is now very obvious, the rudiment of the wing (*F.L.*) being hardly more than a third the size of that of the leg (*H.L.*).

The specimen was sectioned in the same direction as the last (*cf.* Plate 5).

Stage D (Plate 3, fig. 5).

This embryo was unfortunately much damaged by the collector during removal from the egg. The head was severed from the body, the surface was considerably abraded, and, worst of all, both fore-limbs were destroyed. Measured along the curve of the back it is about 43 mm. from the end of the beak to the end of the tail.

The advance beyond the preceding stage is very marked, avian characters being definitely assumed. The general features correspond fairly with those of an eighth day Chick.

The head is rounded in side view, compressed laterally (Plate 9, figs. 88–92), and produced into a short beak, slightly curved at the tip. Owing to the damaged state of the specimen, I could not be perfectly sure of the position of the nostril, but from a careful examination of the entire embryo, and afterwards of the transverse sections into which it was cut, I feel tolerably certain that it was situated as in fig. 5 (*Na.*), that is, about half way between the base and the tip of the beak.

The visceral clefts have disappeared, with the exception of the first (*Cl.* 1), which now forms the tympano-eustachian passage, and appears externally in its usual position below and behind the eye.

The neck is long and the tail very distinct. The fore-limb, as already mentioned, was destroyed on both sides. I have indicated its position and probable form by a dotted outline (*F.L.*). The hind-limb retains its embryonic position at right angles to the long axis of the trunk, and with its ventral or flexor surface directed mesiad. There is no flexure at either knee or ankle, but the pes is marked out by being broader and flatter than the rest of the limb, and produced dorsally into low ridges, indicating the position of the three principal digits (2, 3, 4). The hallux (1) is an inconspicuous projection on the preaxial border of the foot.

The specimen was cut into a complete series of transverse sections, the head, neck, and trunk being cut separately. Of the hind limbs horizontal sections were taken, *i.e.*, sections parallel to the plane of the digits.

Stage E (Plate 3, figs. 6 and 7).

This very interesting stage is, like the last, represented by a single specimen a good deal damaged during removal from the egg. The head was severed, and the whole surface abraded. The total length is nearly the same as in the last stage.

The trunk has become straighter, but the tail is still large and curved. The head is rounded, and the beak proportionally longer than in the previous stage. The tip of the beak was damaged, so that the position of the nostrils was not apparent in the entire embryo, but sections showed their position to be as indicated in the figure (*Na.*), namely, at the extremity of the beak. Thus the unique position of the external nares in *Apteryx* is established at a comparatively early stage of development.

In the eye the rudiments of the sclerotic plates are obvious, and the opening of the lacrymal canal is visible as a small pit immediately in front of the eye.

The fore-limb is bent at the elbow at a right angle. The manus is a tridactyle paw, being produced distally into three blunt projections, of which the middle one (2) is the largest, while of the other two the third (3), or postaxial, is slightly longer than the first (1), or preaxial, digit.

The hind-limb has also undergone a right-angled flexure at the knee, and at the same time the femur has rotated so that the combined crus and pes—which are still in the same straight line—are directed backwards, having their preaxial border mesial, and their originally dorsal (outer) surface looking downwards and forwards. The muscles of the thigh have undergone a notable development, so that this region of the leg has already its permanent laterally compressed form. The pes is still short, but the second, third, and fourth digits (figs. 7, 2, 3, 4) are well marked out; they are still connected by membrane, so that the foot at this stage is distinctly webbed. The hallux (1) has the form of a short blunt projection on the preaxial border of the tarsal region.

In this embryo the brain was removed, and the base of the skull drawn from above. The head was then imbedded, and sagittal sections of the left side cut until the mesial plane was reached, when it was turned, and the right half cut into transverse sections. The pectoral and pelvic girdles of one side were exposed, sketched *in sitû* and removed, and a complete series of sagittal sections was then made of the trunk. The fore-limbs were then cut horizontally, *i.e.*, parallel to the plane of the digits, one of the hind-limbs horizontally, the other sagittally, *i.e.*, at right angles to the plane of the digits.

Stage F (Plate 3, figs. 8 and 9).

This stage is of great interest as being the first in which the generic characters are fairly assumed; the long beak, with its slightly curved tip, and sub-terminal nostrils

(*Na.*), mark the embryo at once as referable to no other genus than *Apteryx*. From the fact that, as shown by sections, ossification is just about to commence in the larger bones of the limbs and the membrane bones of the skull, the stage may be taken to correspond with a Chick of the eighth or ninth day. The entire length from tip of beak to end of tail is now about 60 mm. The head has attained its maximum relative size.

The form of the head, apart from the beak, and the form and curvature of the trunk, are much the same as in the previous stage, but the tail is relatively smaller, and so are the eyes.

The fore-limb is now an undoubted wing; the second digit (fig. 9, 2) has grown out of all proportion to the first (1) and third (3), which form mere blunt projections on the pre- and post-axial borders respectively.

In the hind-limb the thigh is, as in the adult, hardly distinguishable from the outside, the knee only just appearing beyond the general contour of the body. The mesotarsal flexure has appeared, and the toes are directed ventrad. The tarsal region has elongated considerably; the digits are quite free from one another, and have an almost regularly cylindrical form. There is still no trace of claws. The hallux (1) has undergone a considerable shifting distad, its adult position being nearly attained.

The first rudiments of the feather-papillæ are visible. There is a well-marked dorsal tract (*Dors.Pt.*) extending from the occipital region to the rump; it occupies about the dorsal half of the circumference of both neck and trunk, and divides at the root of the tail-papilla, which is itself quite bare. The dorsal pteryla is continuous on each side with a weak and inconspicuous femoral tract (*Fem.Pt.*), and there is a small but well-marked humeral tract (*Hum.Pt.*).

A dissection of this embryo was made from the left side, and the skull with the brain, the pectoral and pelvic girdles, and the ribs and sternum, were sketched *in sitû*. The head was then disarticulated, the brain removed, and the base of the skull drawn from above and from below; a model of the brain-case was also made in clay. The head was then stained and embedded, and, as in the previous stage, sagittal sections of the left half and transverse sections of the right half were cut. The shoulder and hip girdles and the sternum and ribs of one side were removed and mounted separately, and the trunk then cut into sagittal sections. The wings were sectioned horizontally, while of the legs one was cut into horizontal, the other into sagittal sections.

Stage G (Plate 3, figs. 10 and 11).

One of the two embryos belonging to this stage (*A. oweni*) was found to be crushed quite flat from side to side, apparently by the weight of the superincumbent yolk, the egg having been opened and placed entire in alcohol. The following description applies, therefore, to the specimen of *A. australis*.

From the fact that the shafts of the principal long bones of the leg and the membrane bones of the skull have begun to ossify, this stage may be taken to correspond with a Chick of about the eleventh or twelfth day.

The total length from the tip of the beak to the uropygial papilla is about 90 mm. The form of the head has undergone but little alteration, but the relative length of the beak has increased considerably. Owing to the development of the eyelids the eyes appear much smaller than in the previous stage, the sclerotic plates being completely hidden, as well as the opening of the lacrymal duct. The nictitating membrane has appeared.

The tail is reduced to a small rounded uropygium (figs. 10 and 11, *Upg.*), immediately cephalad of which is a rounded area having its margin depressed below the general level of the region, and devoid of feather papillæ. This area, which is subsequently modified into the lips of the cloaca, has near its anterior margin a deep depression, from which springs a prominent papilla, bearing the cloacal aperture (*Clo.ap.*), towards the posterior (caudal) aspect of its summit.

The wing is relatively slightly smaller than in the previous stage, and has assumed quite the adult form, there being no trace externally of either the first or the third digit.

The legs have undergone a great increase in size ; the digits have lengthened very considerably, and each is now tipped by the rudiment of the horny claw, at the base of which is an annular fold of skin.

The feather papillæ are now very prominent, especially on the rump. A distinct tract has appeared on the dorsal surface of the head, and another on the ventral aspect of the neck extending a short distance on to the pectoral region, and becoming confluent with the humeral tracts (*Hum.Pt.*).

A complete series of transverse sections was made of the head, neck, and trunk of the specimen of *A. australis,* as well as horizontal sections of the wings and feet. In *A. oweni* the skeleton was prepared by dissection.

Stages H–K (Plate 3, figs. 12 and 13).

From Stage H onwards the embryo has practically acquired all the adult characters, except that the feathers are hair-like, the barbs being still enclosed in a sheath of the stratum corneum.

Fig. 12 shows an embryo of Stage I after removal of the feathers. The dorsal and ventral tracts so distinct in Stage G, have met and coalesced on the sides of the neck, but on the trunk the lateral apterium (*Lat.Apt.*) is quite distinct, extending from the region of the wing backwards on to the rump. There is also a well-marked ventral space (*Vent.Apt.*), and the whole inner (ventral) aspect of the wing is devoid of feathers, forming an inferior alar apterium (fig. 13, *Inf.Al.Apt.*). The remiges are no larger than the contour feathers, and as in all other stages the uropygium (*Upg.*) is naked, presenting no feathers round its base which can be identified as rectrices.

As compared with the previous stages the relative diminution in size of the head, the elongation of the beak, and the immense increase in all dimensions of the legs, are particularly noticeable.

My observations on these stages, as well as on many of the previous ones, relate exclusively to the skeleton and the brain. Most points were made out by dissection, but verification by serial section was constantly resorted to, the wings of several specimens being examined in this way, as well as the entire head of an example of *A. oweni* belonging to Stage H.

Neither in these nor in any of the previous stages was there any trace of the little rounded caruncle, or "egg-breaker," on the end of the beak, which is so marked a feature in most Carinate Birds. My Father tells me that he knows of no other bird in which it is absent; I have myself observed it in Gulls, Petrels, Ducks, and Penguins, but there is no trace of it in the advanced embryo of a Dottrel (*Charadrius bicinctus?*) in my possession. It is not indicated in Miss LINDSAY's figures of Ostrich embryos (19, Plate 43), and, according to ROLLESTON and HATCHETT JACKSON (48, p. 379), it is not always present.

III.—REMARKS ON THE EXTERNAL CHARACTERS OF THE ADULT.

It is constantly stated in zoological works that the Ratitæ are distinguished by an uninterrupted pterylosis. NITSCH says (23, p. 118) that "the whole body, with the exception of the constantly naked parts of the head and neck, the naked band on the breast along the crest of the sternum, the tarsi, and, in the African Ostrich, the legs and the sides of the trunk, is covered, after the fashion of Mammals, with a homogeneous feathery coat." This statement is practically repeated by FÜRBRINGER (11, p. 1010) and by WIEDERSHEIM (52, p. 31), to mention only two important modern works which deal with the question. Pterylæ and apteria are, however, shown in Miss LINDSAY's figures of Ostrich embryos (19, Plate 43), but they are only briefly referred to in the explanation of the plate.

In the adult *Apteryx*, as in advanced embryos, the pterylosis is by no means uninterrupted. In a fresh specimen of *A. bulleri* I find the lateral apterium to be fully 2 cm. wide, and to extend about 5 cm. cephalad and 9 cm. caudad from the axilla, its total length being therefore about 14 cm. In the same specimen, the ventral or inferior space was of about equal width (2 cm.), and extended about 11 or 12 cm. caudad from between the origins of the wings. Moreover, the inner (ventral) surface of the wing is always nearly devoid of feathers (Plate 3, fig. 15), and so constitutes a well-marked lower wing-space.

According to NITSCH, the function of the lateral apteria "seems to be, not only the facilitation of the movements of the wing, but likewise to serve for the reception of the folded wing, in such a manner that it may be supported upon the feathers of the branch of the ventral tract." It seems reasonable, on this view, to suppose that the presence of a large lateral space is evidence of the wings having been larger in the ancestors of the Kiwi than in the existing genus.

I find, however, that the space in question has a definite function in connection with the attitude assumed by the bird during sleep. According to POTTS (46), "the mode of roosting is very peculiar; they squat opposite each other with their legs bent under them, each with its head tucked under the scanty apology for a wing." Careful observation of living specimens of both *A. australis* and *A. bulleri* shows that this statement is not quite correct. When a Kiwi is settling down to sleep it squats as described, resting upon the whole length of the foot, the rump being in contact with the ground, and the trunk at an angle of about 45°. The head, after a little preliminary fidgetting, is then turned round to the right, and the beak gradually worked under the side feathers, apparently until the lateral apterium is found by its sensitive tip: it is then somewhat quickly thrust backwards beneath the feathers—the action resembling that of sheathing a sword—until it is completely hidden. On carefully turning the feathers aside without disturbing the bird, it was found that the beak was placed along the lateral apterium, with its base immediately cephalad of the axilla. As the wing is so placed in the position of rest that the upper arm is directed from the axilla upwards and backwards, the base of the beak lay in a kind of trough, bounded mesiad by the trunk and laterad by the wing, the naked elbow being very obvious as a small flesh-coloured projection just external to it. In this position the distal portion of the wing is thrust somewhat outwards, and its feathers—remiges and upper coverts—appear externally, taking a direction downwards and backwards over the ordinary contour feathers of the trunk.

It is rather significant that this is precisely the attitude of a Goldfinch or Canary when asleep, the beak in these cases being over (dorsad of) the axilla, and therefore, of course, under the spreading side feathers. Perhaps the facts may be explained by supposing that during the evolution of the genus *Apteryx*, the great lateral spaces were retained as resting places for the increasing beak, although no longer useful for the reception of the diminishing wings.

Another fact which appears to me to tell in favour of the derivation of *Apteryx* from a progenitor with well developed wings, is the fact that the wing is provided with a true alar membrane. Both OWEN's figure (24, Plate 1, fig. 4), which shows the wing of *A. australis* from the outer side with most of the feathers removed, and BULLER's (7, Plate 12, fig. 6), which shows that of *A. bulleri* from the inner side with the feathers *in sitû*, are apparently taken from somewhat shrivelled specimens. The wing of a perfectly fresh specimen of *A. bulleri* is shown in figs. 14 and 15 (Plate 3): it has, precisely as in typical Carinatæ, a distinct fold of skin, or pre-patagium, passing between the upper arm and fore arm, as well as an equally well marked fold, the post-patagium, between the postaxial border of the upper arm and the trunk.

The characters of the alar claw do not appear to have been described with any accuracy, and are of some interest as seeming to furnish a very fair specific character.

As far as my experience goes, the alar claw of *A. oweni* is always soft and weak, gently curved, about 4 mm. long, and of a light horn colour (Plate 17, fig. 243). That of *A. haastii* is quite similar, but sometimes even smaller: the left claw of the supposed female specimen in the Canterbury Museum being only 3 mm. long; in the supposed male, Professor HUTTON informs me it is about 9 mm. long, much curved and white. In *A. australis* it is about 6–8 mm. long, gently curved, and of a light horn colour, blotched with black (fig. 241). Lastly, in *A. bulleri*, it is strongly curved, from 6 to 18 mm. long, and quite black (figs. 245 and 246). It seems to be constantly larger in the male than in the female, and often differs on the two sides of the body.

As to the form and arrangement of the wing feathers, YARRELL (55) in the earliest accurate description of *Apteryx*, states that these do not differ from the feathers of the body generally, and apparently OWEN (24, p. 3) was the first to point out the presence of remiges; he says "nine quasi-quill-plumes, not exceeding in length the ordinary body feathers, but with somewhat thicker shafts, are arranged in a linear series along the ulnar margin of the antebrachium." FLOWER'S observations referred to by WRAY (54) are not mentioned in the abstract of his lecture on the Wings of Birds (9), but in answer to my enquiries, Professor FLOWER was good enough to inform me that he had found eight cubitals and one metacarpo-digital in the specimen of *A. oweni* mounted for the British Museum, but that several feathers of both sets appeared to be wanting as the bird was moulting.

According to my own observations, made chiefly upon two fresh specimens of *A. bulleri*, and confirmed upon examples of the other three species, there are nine or ten cubitals (figs. 14 and 15 *Cubit.*), of which the five distal (Nos. 1–5) are larger than the rest; two or three metacarpals (*Mtcp.*), and a single mid-digital (*Mid.dig.*), the latter being usually smaller than the rest. The formula for the remiges is therefore

$$Md.\ 3\text{–}4\ (m.\ 2\text{–}3,\ d.\ 1),\ C.\ 9\text{–}10.$$

On the outer side of the wing there is a row of well-marked tectrices majores (fig. 14, *Tect.maj.*), which correspond accurately with the remiges in the distal portion of the series, but towards the proximal end of the row of cubitals become more or less irregularly arranged. The remaining upper coverts are not definitely disposed in rows, so that there is no distinction between tectrices mediæ, tectrices minores, and marginals. The few feathers on the under or inner side of the wing are all directed proximad or towards the axilla (fig. 15), not distad like the upper coverts.

In microscopic structure the feathers agree with those of *Rhea* as described by FÜRBRINGER (11, p. 1482). The barbules (Plate 3, fig. 16) are beset with regularly arranged pointed barbicels slightly curved outwards at their tips, and, as far as my observations go, larger in the unhatched embryo than in the adult.

On the whole it appears to me that the structure of the wing of *Apteryx* lends support to the view that the Ratitæ are the descendants of Birds which possessed the power of flight, a view which, I believe, OWEN was the first to advance. In spite of

Miss **Lindsay**'s conclusions from her study of the development of the sternum (19), and **Wray**'s from his researches on the wing (54), I am still disposed to think that the balance of evidence is in favour of the hypothesis to which I was led by a study of the flightless Rallidæ (26), that the Ratitæ spring from a proto-carinate stock, a theory which has recently received strong support from the researches of **Fürbringer** (11) and of **Gadow** (13).

It has always seemed to me that, on the hypothesis of its development from an ordinary Reptilian fore-limb, *e.g.*, that of a Dinosaur, the wing is one of the most striking examples of the uselessness of incipient structures. If, on the other hand, we suppose it to have been evolved from a patagium, which gradually diminished *pari passû* with the development of its scales into feathers, the difficulty of its first origin is overcome and the presence of the alar membranes is explained.

IV.—THE LAW OF GROWTH.

(Plates 6 and 7.)

A very interesting mode of comparison of aberrant—either highly specialised or highly generalised—forms with their more typical congeners, is furnished by observation of the relative rate of growth of various regions of the body from an early stage of development to adult life. The difference between the law of growth of Man and of the other Primates is an example which will occur to everyone. I think it will be useful to furnish materials towards an enquiry into the general law of growth in Birds by giving a series of measurements of the various stages of *Apteryx*, as is done in Table A. In the adult it will be seen that measurements of both sexes are given in the case of *A. australis* and *A. oweni*: of *A. bulleri* I have been able to measure only a single skeleton. This is, however, of comparatively little importance since *A. australis* and *A. bulleri* agree with one another so closely in size and proportions. Moreover, as already stated (p. 28) the so-called *A. maxima*, of which measurements are given, is probably referable to this species.

Measurements are also given of a skeleton which I have named doubtfully *A. haastii*, a species which was founded by **Potts** (45) upon two skins from the west coast of the South Island and now in the Canterbury Museum. By the kindness of Professor **Hutton**, at that time acting Director of the Museum, I was enabled to examine the wing of one—the supposed female—of the type specimens, and found it to differ from all examples of *A. australis* (which it resembles in size) and to agree with *A. oweni* in the possession of a distinct radiale in the carpus (see p. 93, and Plate 17, fig. 250), and in the characters of the alar claw (p. 37).

The doubtful skeleton referred to was obtained near Cape Providence, on the west coast of the South Island, in 1881, by a collector named **Wheeler**, who left it in the landing shed of the Puysegur Point Lighthouse before starting for another expedition

TABLE A.—Measurements of Developmental Stages of *Apteryx* in millimetres.

Stage.	A.	B.	C.	D.	E.	F.	G.	H.	I.	K.	L.	M.	*Adult.* A. bulleri, ♀.	*Adult.** A. maxima = bulleri.	*Adult.* A. australis, ♂.	*Adult.* A. australis, ♀.	*Adult.* A. haastii, ?	*Adult.* A. oweni, ♂.	*Adult.* A. oweni, ♀.
Vertebral column, length, following the curve	9	10·5	13	19	21	27·5	44	90	120	172	200	285	396	400	380	445	430	288	320
Brain-case, length in a straight line from occiput to base of beak (descending process of nasal)	..	..	..	7·2	7	9	12	20	23	29	32	35	43	45	46	49	48	34	36
Beak, length from base (descending process of nasal) to tip	..	..	..	2·2	2·5	7	12	28	35	49	60	72	140	125	114	146	118	79	84
Entire head, from occiput to tip of beak	3	3·7	4·2	8·7	9	15·5	24	48	58	78	92	107	183	174	160	195	166	113	120
Sternum, greatest length in a straight line	..	..	..	?	1	3·5	3·75	11	15	23	26	27	38	39	42	45	49	28	30
Coracoid ditto ditto	..	..	..	?	1·2	1·6	2	3	4·5	8	9	11	17	18	17	20	20	13	14
Scapula ditto ditto	..	..	..	?	1·5	2·4	3·5	8	11·5	17	19	24	27	25	28	28	30	25	27
Entire shoulder-girdle ditto ditto	..	..	..	?	2·7	4	5·5	11	16	25	26	32	42	43	42	46	46	35	36
Humerus ditto ditto	..	..	..	?	1·5	3	4·75	9·5	14	21	25	31	43	43	44	48	47	34	36
Antebrachium ditto ditto	..	..	..	?	0·9	1·5	2·8	5	7	12	13	17	24	23	23	25	21	15	17
Manus ditto ditto	..	..	..	?	1·1	1·5	1·5	3	5	7·5	10	10	12	14	15	14	13	10	11
Entire fore-limb ditto ditto	0·25	0·5	0·6	?	3·5	6	9·1	17·5	26	40·5	48	58	79	80	82	87	81	59	64
Ilium ditto ditto	..	..	..	3·2	4	7	9·75	23	30	44	50	72	101	113	112	123	123	76	81
Femur ditto ditto	..	..	..	2·5	4	6	7·5	19·5	26	42·5	50	69	99	92	96	107	104	72	76
Crus (to mesotarsal joint), in a straight line.	..	..	..	3	4	7·5	11	27	37	61·5	70	94	134	136	140	145	148	101	104
Tarso-metatarsus, greatest length in a straight line . .	..	..	..	1·4	2·2	3·5	7	16	23	38	43	49	71	75	72	76	76	51	58
Middle (*third*) *digit* ditto ditto . . .	..	..	..	0·7	1	2	5	16	22	38	43	45	62	65	68	66	68	50	50
Entire pes, from mesotarsal joint to end of third digit .	..	..	..	2·1	3·2	5·5	12	32	45	76	86	94	133	140	140	142	144	101	108
Entire hind-limb, greatest length	0·4	1	2·5	7·6	11·2	19	30·5	78·5	108	180	206	257	366	368	376	394	396	274	288

* See p. 28.

from which he never returned. The skeleton was found by the lighthouse keeper, Mr. J. W. CUNNINGHAM, and given to my taxidermist, Mr. E. JENNINGS, to whom I am indebted for the opportunity of examining it. It presents the following peculiarities :—It is as large as an average female *A. australis,* but the beak is little longer than in the male of that species and proportionally no longer than that of *A. oweni* (see Table B). The left manus has a distinct radiale (Plate 17, fig. 251), and the alar claw, which was present on both sides, is small and light coloured, as in *A. haastii* and *A. oweni.* The sternum also (Plate 16, fig. 210) is unusually long. These characters by no means prove the skeleton in question to be anything more than a somewhat aberrant example of *A. australis,* but they are enough to warrant separate measurements being given.

In addition to the Table (A) of actual measurements, another (B) is given in which comparison is facilitated by taking the length of the vertebral column as = 100 and expressing the remaining measurements as percentages. It is only by using some such method as this that the changes of proportion of various parts of the body during the course of development can be clearly shown. In comparing *Notornis* with other Rails (26) I took as my standard the length of the trunk as measured from the anterior end of the coracoid to the posterior end of the pelvis ; FÜRBRINGER (11) employs for the same purpose the length of a thoracic vertebra. But both these methods would preclude the comparison of the earlier stages, and on the whole I am disposed to think that the standard here adopted answers the purpose satisfactorily. Graphic representations of the same facts are given in Plates 6 and 7. In fig. 45 the various parts of the body are represented in a conventional manner, the vertebral column being made in each case 100 mm. long, and the head, limbs, etc., in proportion. In figs. 46-49 the curves of growth of certain important regions are shown separately.

The following are the most important results obtained by this method of enquiry.

The brain-case remains of about the same relative size up to Stage F, when it begins to grow less rapidly than the vertebral column. The age at which its ultimate or minimum proportional size is attained is not known, but in a young bird several weeks old (Stage L) it was not yet reached.

The beak, which is undeveloped in the first three stages, is of about the same size in D and E ; in F it has undergone a notable increase ; in G it is of the same length as the brain-case, and its maximum proportional length is attained in H. It is worthy of remark that, as shown in Table B and fig. 46, the proportional length of the beak is nearly the same in the two sexes, although its absolute length is so much greater in the female ; in *A. oweni,* indeed, the beak of the male was found to be relatively longer than that of the female, but this was very probably an individual variation.

The sternum (fig. 47) attains its maximum in Stage F, thereafter undergoing but little variation in relative size. It is important to note, however, that up to Stage G the postero-lateral processes are not formed (Plate 16, figs. 216–218), so that its

TABLE B.—Measurements of *Apteryx* expressed as Percentages of Length of Vertebral Column.

Stage.	A.	B.	C.	D.	E.	F.	G.	H.	I.	K.	L.	M.	*Adult.* A. bulleri, ♀.	*Adult.** A. maxima = bulleri.	*Adult.* A. australis, ♂.	*Adult.* A. australis, ♀.	*Adult.* A. haastii, ?	*Adult.* A. oweni, ♂.	*Adult.* A. oweni, ♀.
Vertebral column	100	100	100	100	100	100	100	100	100	100	100	100	100	100	100	100	100	100	100
Brain-case	..	..	..	37·89	33·3	32·72	27·27	22·2	19·16	16·8	16	12·28	10·87	11·25	12·1	11·01	11·16	11·8	11·25
Beak	..	..	..	11·57	11·9	25·45	27·27	31·1	29·16	28·48	30	25·26	35·35	31·25	30	32·8	27·44	27·43	26·25
Entire head	33·3	35·23	32·3	45·78	42·85	56·36	54·55	53·3	48·3	45·34	46	37·54	46·21	43·5	42·1	43·82	38·6	39·23	37·5
Sternum	..	..	..	?	4·76	12·72	8·52	12·2	12·5	13·37	13	9·47	9·59	9·75	11·05	10·11	11·39	9·72	9·37
Coracoid	..	..	..	?	5·71	5·21	4·54	3·3	3·75	4·65	4·5	3·85	4·29	4·5	4·47	4·49	4·65	4·51	4·37
Scapula	..	..	..	?	7·14	8·72	7·95	8·8	9·58	9·88	9·5	8·42	6·81	6·25	7·36	6·29	6·97	8·65	8·43
Entire shoulder girdle . .	..	..	..	?	12·85	14·54	12·5	12·2	13·3	14·53	13	11·22	10·6	10·75	11·05	10·33	10·69	12·15	11·25
Humerus	..	..	..	?	7·14	10·9	10·79	10·5	11·6	12·2	12·5	10·87	10·85	10·75	11·57	10·78	10·93	11·8	11·25
Antebrachium	..	..	..	?	4·27	5·45	6·36	5·5	5·8	6·97	6·5	5·96	6·06	5·75	6·05	5·61	4·88	5·2	5·31
Manus	..	..	..	?	5·23	5·45	3·4	3·3	4·16	4·36	5	3·5	3·03	3·5	3·94	3·14	3·02	3·47	3·43
Entire fore-limb	2·7	4·76	4·61	?	16·6	21·81	20·69	19·4	21·6	23·54	24	10·35	19·94	20	21·57	19·55	18·8	20·48	20
Ilium	..	..	..	16·7	19·04	25·45	22·15	25·5	25	25·58	25	25·26	25·5	28·25	29·47	27·64	28·6	26·38	25·3
Femur	..	..	..	13·15	19·04	21·81	17·04	21·6	21·6	24·7	25	24·21	25	23	25·2	24·04	24·18	25	23·7
Crus	..	..	..	15·78	19·04	27·27	25	30	30·8	35·75	35	32·9	33·83	34	36·84	32·58	34·41	35·07	32·5
Tarso-metatarsus	..	..	..	7·36	10·47	12·72	15·9	17·7	19·1	22·09	21·5	17·19	17·92	18·75	18·9	17·09	17·67	17·7	18·12
Middle (third) digit . . .	..	..	..	6·38	4·76	7·27	11·36	17·7	17·5	22·09	21·5	15·7	15·65	16·25	17·89	12·58	15·81	17·37	15·62
Entire pes	..	..	..	11·05	15·23	20	27·27	35·5	37·5	44·18	43	32·9	33·58	35	36·84	31·91	33·48	35·07	33·75
Entire hind-limb	4·4	9·52	19·23	40	53·3	69·09	69·31	87·2	90	104·65	103	90·17	92·37	92	98·93	88·53	92·09	95·13	90

---

* See p. 28.

potential is very much greater than its actual length, and the comparison with later stages is hardly fair.

The shoulder-girdle (fig. 47) hardly changes in proportional size from the time it was first observed (Stage E). The coracoid is of much the same size in all species, but the scapula appears to be longest in *A. oweni.*

The pelvis (fig. 47) attains its maximum in Stage F, remaining about the same throughout life, save for what are probably individual variations, in *A. oweni*, but increasing slightly after hatching (Stage K) in *A. australis.* In all the skeletons examined the relative size of the pelvic girdle was slightly greater in the male than in the female.

The fore-limb (fig. 48), taken as a whole, increases pretty regularly up to Stage F, and then remains stationary, subsequent variations being obviously individual. The variations in the two sexes and in the different species, in the adult, would probably disappear if the average of a sufficiently large series of specimens was taken. As to the separate divisions of the wing the only point worthy of mention is that in Stage E the manus is longer than the antebrachium, while in F the two are of the same length, and in G the adult proportions are attained.

The curve of growth of the hind-limb is very different (fig. 49). The entire limb increases rapidly and with but slight fluctuations, due no doubt to the observations being made on single specimens, from 4·4 per cent. of the vertebral column in Stage A to 104·6 per cent. in Stage K. In the adult it varies from 88 per cent. (*A. australis,* ♀) to 98 per cent. (*A. australis,* ♂), thus undergoing a relative diminution in size between the time of hatching and the attainment of fully adult proportions. It is quite possible that this rather remarkable result is to be put down to individual variation, but I hardly think so, as the three specimens belonging to Stage K and the single specimen of Stage L (not shown in the diagram) all have the hind-limb more than 100 per cent. of the vertebral column, while in the adult it was below 95 per cent. in six out of seven skeletons measured.

The four divisions of the limb—femur, crus, tarso-metatarsus, and middle (third) digit—increase in much the same manner as the whole limb, the only point worthy of special mention being the fact that the middle digit is at first (Stages D and E) not more than half the length of the tarso-metatarsus, while from Stage E onwards it gradually increases until the two divisions of the foot are of equal length in H. This proportion is retained as far as L, but in the adult the middle digit is, in seven skeletons measured, slightly shorter than the tarso-metatarsus. So that in the relative proportions of the two divisions of the foot, as in that of the entire hind-limb, the maximum differentiation appears to be attained about the time of hatching, a retrogression towards more embryonic proportions taking place subsequently.

As to sexual and specific differences I find that the legs of the male are relatively longer than those of the female. In the skeletons examined the legs of the male are proportionately longer in *A. australis* than in *A. oweni*, while in the female the reverse is the case. This, again, is very probably a matter of individual variation.

A brief statement of the law of growth in *Apteryx* is given in the Summary (p. 111).

V.—THE SKELETON.

The detailed accounts of the skeleton of *Apteryx* by Owen (24), Blanchard (6), and Mivart (21), render any full account of the general adult osteology quite superfluous. The observers referred to have, however, only had the opportunity of describing adult or sub-adult specimens. Their material has, moreover, consisted of a small number of examples, so that they have been unable to take account of the individual variations, some of which, as will be seen hereafter, are of considerable interest.

I propose, therefore, to begin my account of each portion of the skeleton by describing somewhat fully either the condition of the part in question in the ripe embryo, in which the various ossifications are distinct, or the adult structure in cases where, owing to paucity of material, the descriptions of former observers are imperfect.

I have found it convenient to add two new terms to the general terminology of the skeleton. An independent cartilaginous element or centre of chondrification is called a *chondrite*, an independent bony element or centre of ossification an *osteite*, both words being formed on the model of the well-known entomological term "sclerite."

1. The Skull.

a. At the Time of Hatching (*Stage K*).

(Plates 8 and 9.)

Owen's descriptions of the skull (24) are taken from a fully adult specimen of *A. australis*, and from one in which the frontal and left half of the coronal* sutures were persistent. The skull of the same species figured by Blanchard (6) had the sagittal, coronal, and middle third of the lambdoidal sutures open, and many of the membrane bones were distinct; but the bones of the basis cranii were united, and the turbinals do not appear to be shown.

In the skull of Kiwi chicks, either shortly before or shortly after hatching, all the ossifications have appeared, and the only ankyloses are those between the right and left premaxillæ, dentaries, and splenials, and between the basi- and para-sphenoids. After maceration the membrane bones are readily detached.

---

* Both in Owen's original monograph and in the reprint the coronal suture is, obviously by a printer's error, called sagittal.

Figures of the entire skull and of the separate membrane bones are given in Plate 8, figures of the chondrocranium in Plate 9. Sections through important regions in a somewhat earlier stage (H) are given in Plates 12–14, and will be occasionally referred to.

The Chondrocranium.

By the removal of all the membrane bones, except the already ankylosed parasphenoid (basitemporal *plus* rostrum) the chondrocranium (Plate 9, figs. 75–77) is obtained as a basin-shaped mass of mingled bone and cartilage, produced in front into the elongated olfactory capsules (fig. 75, *Ec.Eth.*) and prenasal rostrum (*Pr.Na.*). The short basis cranii (*B.Oc.*, *B.Sph.*) is continued behind into the occipital arch (*S.Oc.*), and on each side into the auditory capsules (*Pr.Ot.*), and alisphenoids (*Al.Sph.*), while in front it bears the deep, transversely elongated, pituitary fossa (*Pty.F.*).

All the cartilage bones of the fully developed cranium have appeared, and, with the exception of the isolated ethmo-presphenoid bone (*Eth.Pr.Sph.*), are separated from one another by narrow synchondroses.

The *basioccipital* (*B.Oc.*) is roughly pentagonal in form, and bears posteriorly the transversely ovoid occipital condyle (*Oc.Cn.*). Its anterior border is separated by a narrow synchondrosis from the basisphenoid (*B.Sph.*), while by its antero-lateral borders it is similarly related to the prootics (*Pr.Ot.*), and by its postero-lateral borders with the exoccipitals (*Ex.Oc.*). Its dorsal surface is nearly flat, its ventral surface bears, immediately cephalad of the condyle, a tranversely oval depression.

The exoccipital is already partly ankylosed to the periotic. Externally it forms the greater part of the ventro-lateral region of the posterior surface of the cranium (fig. 53) ; but internally (fig. 56) it appears only as a narrow strip of bone bounding the foramen magnum. It is produced laterad into a large paroccipital process (*pa.oc.pr.*) covered with cartilage, which forms the posterior wall of the tympanic cavity (fig. 77). On its inner or cranial surface (fig. 56) it is separated from the opisthotic by a deep groove, in which is situated—bounded on all sides by the exoccipital—the foramen for the ninth and tenth nerves (*Nv. IX.*, *X.*). The twelfth nerve makes its exit through a number of small foramina (figs. 51 and 76, *Nv. XII.*) in the postero-inferior region of the bone Part of the horizontal semicircular canal (*H S.C.*) lies in the exoccipital, and the vertex of the anterior canal (*A.S.C.*) is situated at its junction with the prootic and supraoccipital.

The *supraoccipital* (*S.Oc.*) is a squarish bone articulating by its dorsal border with the parietals (*Pa.*), separated laterally by synchondroses from the exoccipitals and periotic (fig. 56), and ventrally forming the upper border of the occipital foramen. For the greater part of its extent it is extremely thin, but its ventral border is thickened and hollowed out by air cavities continuous with those of the periotic (figs. 75 and 77, *pn.c.*), and its lateral border bears a deep pit for the vertex of the anterior semicircular canal.

The *prootic* (*Pr.Ot.*) is already fused in great part with the exoccipital, the two bones being inseparable after prolonged maceration, although the bands of cartilage separating them are well shown on the inner surface of the skull (fig. 56). It is a large irregular bone, appearing but little on the outer surface, where it forms the mesial wall of the tympanic cavity (fig. 52), but internally forming a great part of the postero-ventral region of the brain-case (figs. 56 and 75). Its dorsal surface is flattened, and produced mesiad into an obliquely horizontal ridge, which extends from the junction of the prootic, exoccipital, and supraoccipital forwards and downwards to the trigeminal foramen (*Nv.* $V^{2,3}$). Under the eaves of this ridge on the mesial surface of the prootic are two recesses, the hindmost of which is the deep floccular fossa (fig. 56, *flc.f.*), while the foremost is a shallow groove containing anteriorly a foramen for the exit of the seventh nerve (*Nv. VII.*), and posteriorly two small apertures for the eighth (*Nv. VIII.*). Ventrad and slightly caudad of the auditory foramina are three small apertures, which transmit lesser branches of the eighth nerve. The flattened dorsal surface of the prootic presents low elevations, marking the positions of the anterior and horizontal semicircular canals (*A.S.C.*, *H.S.C.*); these are best seen when the chondrocranium is examined in turpentine by transmitted light. Its posterior face is closely applied to the exoccipital, with which it is partly ankylosed, and between the two bones the dorsal edge of the chondrocranium presents a large trough-like pneumatic cavity (figs. 75 and 77, *pn.c.*), divided transversely by a bridge of cartilage, and closed in the entire skull by the juxtaposition of the parietal and squamosal (figs. 62 and 69, *pn.c.* and Plate 14, fig. 170). The lateral surface of the prootic furnishes the inner wall of the tympanic cavity; it is honey-combed with air cells, and presents dorsally a circular facet covered with cartilage (figs. 76, 77, and 78, $qu.^1$) for the inner articular process of the head of the quadrate (fig. 79, *pr.ot.*). Near the boundary of the prootic with the exoccipital is the fenestral recess, containing the fenestra ovalis (fig. 77, *f.ov.*) and the fenestra rotunda (*f.rot.*), and a short distance cephalad of this recess is the aperture (figs. 56, 77, and 78, *Nv.* $VII.^1$), by which the portio dura enters the tympanic cavity.

The *opisthotic* (fig. 56, and Plate 14, fig. 171, *Op.Ot.*) is clearly seen on the inner surface of the auditory capsule, as a narrow bone wedged in between the prootic and the exoccipital, and separated from each by a very narrow synchondrosis. In its deeper portion it is ankylosed to these bones.

There is no trace of epiotic or sphenotic ossifications, both of which occur in the Chick (44, pp. 242 and 249) at the time of hatching or a little later.

The *basisphenoid* (*B.Sph.*) which is already completely united with the parasphenoid (basitemporal, *B.Tmp.*; and rostrum, *Rost.*) has an irregularly hexagonal form as seen from above (fig. 75), and is wedge-shaped in sagittal section (fig. 56), being quite thin where it joins the basioccipital, and increasing in thickness towards the pituitary region. By its posterior border it is connected by synchondrosis with the basioccipital, by its postero-lateral border with the prootics, by its antero-lateral borders with the alisphenoids, and by its anterior border with the presphenoid. Immediately caudad of the vertical posterior edge of the presphenoid (fig. 56, *Pr.Sph.*) the dorsal surface of the basisphenoid is deeply excavated to form the transversely oval pituitary fossa (*Pty.F.*).

Ventrally, as already stated, the basisphenoid is completely fused with the elements of the parasphenoid. Of these, the *rostrum* (*Rost.*) is a slender bone crescentic in cross section (Plate 13, figs. 155–160) and closely applied to the ventral edge of the mesethmoid. The *basitemporal* (*B.Tmp.*) projects beyond the basisphenoid both caudad and laterad, forming paired processes which overlap the basioccipital (figs. 51 and 76). Between these wing-like processes the posterior edge of the bone is emarginate, and in one specimen presents a small median notch (fig. 76, *p.bcr.fo.*) indicating the position of the closed posterior basicranial fontanelle (*cf.* Plate 10, figs. 108 and 109, and Plate 14, figs. 173 and 174, *p.bcr.fo.*). Laterally, the combined basi- and para-sphenoid is produced into the paired outstanding basipterygoid processes (*B.ptg.pr.*), which are tipped with cartilage, and immediately caudad of these are the pretemporal wings (figs. 51, 76, and 78, *Pr.Tmp.*), which, closely applied to the prootics, help to enclose the anterior tympanic recesses.

On the ventral surface of the basitemporal are paired oblique grooves (figs. 51, *Eus.T.*) traceable backwards into the tympanic cavities; they lodge the Eustachian tubes, and in later stages become arched over by bone. In the postero-lateral region of the bone is the well-marked carotid foramen (*Int.Car.*). This leads into a canal which passes forwards, upwards, and inwards, to open with its fellow into the posterior region of the pituitary fossa immediately beneath the dorsum sellæ (fig. 56, *Int.Car.*).

On the dorsal surface of the basisphenoid, near the middle of its antero-lateral border, is the minute foramen for the sixth nerve (fig. 75, *Nv. VI.*); it leads into a canal which passes forwards and slightly upwards and outwards and enters the orbit immediately ventrad of the orbito-nasal foramen (figs. 52 and 77, *Nv. VI.*).

Immediately dorsad of the basipterygoid process is a small round foramen (fig. 77, *n.a.*) which leads into the interior of the basisphenoid: it probably transmits a nutrient artery.

Further particulars of the internal structure of the basisphenoid will be given in the description of the skull in stages H and I (pp. 66 and 70). My material did not allow of my making thin sections of the present stage, and, indeed, such a course was unnecessary as the differences between stages H, I, and K are comparatively slight.

The *alisphenoid* (*Al.Sph.*) is an irregular concavo-convex bone united by cartilage with the anterior border of the prootic and with the antero-lateral border of the basisphenoid. Between it and the prootic is a large rounded foramen (*Nv.* $V.^{2,3}$) for the exit of the second and third divisions of the trigeminal; on the inner surface of the skull this foramen lies immediately in front of the anterior termination of the prootic ridge, externally it is just above the anterior tympanic recess. From the anterior border of this trigeminal foramen a groove is continued forwards on the inner face of the synchondrosis between the alisphenoid and basisphenoid, and ends in a foramen (*Nv. V.*^{1}), which enters the orbit and transmits the first division of the fifth nerve; it may, therefore, be called the orbito-nasal foramen. It is erroneously stated by OWEN (24, p. 28) that the first division of the fifth passes out along with the optic, oculomotor, and abducent nerves through the optic foramen, and that the second and third divisions make their exit respectively through the "foramen rotundum" (= orbito-nasal foramen) and "foramen ovale" (= trigeminal foramen). The actual condition of things I have verified both by dissections, and by a complete series of microscopic sections of stage H.

On the outer surface of the cartilaginous junction between the prootic and alisphenoid, and extending on to the latter bone itself, is a rounded, slightly concave cartilaginous facet (fig. 78, *qu.*^{2}), in contact with but clearly distinguishable from a similar facet to be described hereafter (p. 54) on the squamosal (*qu.*^{3}). To this double surface is articulated the external process of the head of the quadrate (fig. 79, *sq.*).

The anterior sphenoidal region of the skull is wholly cartilaginous, there being neither pre- nor orbito-sphenoidal ossifications. The *presphenoid* (*Pr.Sph.*) is represented by a vertical plate of cartilage which passes insensibly into the mesethmoid (*M.Eth.*, fig. 56) in front, and behind is continuous by its lower fourth with the basisphenoid. Its ventral border is thickened and underlaid by the rostrum (fig. 159, *Pr.Sph.*, *Rost.*), its dorsal border is produced laterad into small paired wings of cartilage (fig. 75, *Pr.Sph.*), each of which is continued into a narrow band of the same tissue (*Orb.Sph.*) passing outwards and slightly backwards to unite with a small bony process on the anterior border of the alisphenoid. The study of earlier stages shows that these outgrowths of the presphenoid are the greatly reduced orbitosphenoid plates (*cf.* Plate 9, fig. 85; Plate 10, figs. 96, 97, 104, 105; and Plate 11, figs. 123 and 125, *Orb.Sph.*).

The optic foramina (*Nv. II.*) are situated in the pituitary fossa, one on each side of the presphenoid, their mesial borders being about 3 mm. apart. Each is bounded above by the orbitosphenoid bar, below by the basisphenoid, in front by the presphenoid and antorbital plate (*vide infra*), and behind by the alisphenoid. The third and fourth nerves make their exit through the connective tissue filling up the postero-dorsal region of the optic foramen, the fourth lying dorsad and slightly laterad of the oculomotor.

The *mesethmoid* (*M.Eth.*), as already stated, is continuous behind with the presphenoid. In its posterior region it is a plate of considerable vertical extent, and its dorsal border, which is concave from before backwards (fig. 56), separates the olfactory fossæ from one another, and has the relations of a crista galli (figs. 75 and 77). At its anterior end the crista galli is produced into a pointed process (figs. 56 and 77, *tg.pr.*), which, as my Father has pointed out, is to be looked upon as a vestige of the cartilaginous tegmen cranii of the lower Vertebrata: it may be conveniently called the tegminal process. At the apex of this process the mesethmoid reaches the outer surface of the skull (fig. 56), and, with the adjacent portions of the ectoethmoids, forms a lozenge-shaped area (fig. 50, *Eth.Pr.Sph.*) between the posterior ends of the nasals. Cephalad of the tegminal process the mesethmoid gradually diminishes in vertical extent, becoming, in the anterior portion of the beak, the pod-like prenasal cartilage (*Pr.Na.*). It is for the most part more or less pyriform in transverse section, its ventral border being greatly thickened (Plate 13, figs. 152–158). None of my specimens of this stage, or, indeed, of any other except G (see p. 126), show any trace of the fenestra in the mesethmoid figured by BLANCHARD (6).

No clear distinction can be drawn between aliethmoid, aliseptal, and alinasal cartilages (*cf.* 31) any more than between presphenoid, mesethmoid, septum nasi, and prenasal. The dorsal border of the mesethmoid, from the tegminal process forwards to within about 2 cm. of the end of the beak, sends off horizontal plates on each side (figs. 75–77 and Plate 12, figs. 152–156, *Ec.Eth.*): these pass at first outwards, then downwards, and finally, in a portion of their extent, inwards, thus forming the roof, the outer wall, and in part the floor of the olfactory chambers. They may be called by the general name of ectoethmoidal plates.

The precise relations of the ectoethmoids vary in different regions, and it is convenient to consider them as consisting of five portions. In the fifth or posterior portion (*Ec.Eth.* 5), besides passing outwards and downwards, they sweep directly backwards, thus forming an almost complete shell-like covering for the principal portion of the olfactory organ, *i.e.*, that part which extends backwards into the orbits (see especially fig. 77, *Ec.Eth.* 5). To this region of the ectoethmoidal plate the name aliethmoid might be restricted. Each aliethmoid is a thin plate of cartilage with convex lateral and caudal (posterior) surfaces; its lateral surface is dilated anteriorly, so as to form the well-marked convexity against which, in the entire skull, the lacrymal is applied (figs. 50, 52, 75, 77, *Ec.Eth.* 5, *Lac.*); its dorsal border, which is concave from before backwards, forms the outer or lateral boundary of the olfactory fossa (figs. 75 and 157); its posterior border is closely applied to the presphenoid and becomes fused with it dorsad; its ventral border is in close contact with the presphenoid and mesethmoid immediately dorsad of the rostrum; its flattened ventral surface (fig. 76) ends in front at its junction with the fourth portion of the ectoethmoid (*Ec.Eth.* 4), and presents a deep emargination which separates a slender forwardly directed process (figs. 76, 77, and 157, *a.*) from the main part of the cartilage. It is the posterior face of this cartilage which forms the anterior wall of the orbit, and is often called the antorbital plate.

In its fourth portion (*Ec.Eth.* 4) the ectoethmoid furnishes only roof and side walls to the olfactory chamber, not being turned inwards to form a floor for the cavity: as a consequence of this, the turbinals are here visible in a ventral view of the entire chondrocranium (figs. 76, 155, 156). Immediately cephalad of its junction with the fifth portion, the lateral region of the fourth is sunk inwards so far as to form an obliquely longitudinal depression (figs. 76 and 156, *A.A.Trb.*) of considerable depth, and lying, in the entire skull, at about the level of the descending process of the nasal (*cf.* figs. 56 and 77). The invagination thus produced projects into the olfactory chamber as the anterior accessory turbinal (*vide infra*, p. 50), and lodges the antero-dorsal branch of the antrum of HIGHMORE.

In its third portion (*Ec.Eth.* 3) the ectoethmoid is again turned inwards ventrally in the form of a plate with a straight mesial border abutting against the mesethmoid, and with oblique anterior and posterior edges (figs. 76, 153 and 154, *Ec.Eth.* 3). At the anterior end of this plate, near its ventral border, is a small arterial foramen.

The second portion of the ectoethmoid (*Ec.Eth.* 2), like the fourth, furnishes only a roof and outer wall to the olfactory chamber (figs. 76 and 152). Lastly, in its first or anterior portion (*Ec.Eth.* 1) it is unconnected with the mesethmoid (prenasal), and has the form of an obliquely placed band of cartilage which is continued to the end of the beak, passing dorsad of the nostril, curving outwards as it does so, and then turning gently downwards, hookwise, immediately cephalad of the anterior termination of the olfactory sac (figs. 75–77 and 149–152). To this plate the name alinasal might be applied, but owing to the unique position of the nostrils in *Apteryx* the relation of this as of other parts of the olfactory capsule is strikingly different from what we are familiar with in other birds.

There is a single ethmoidal ossification (figs. 50, 56, 75, 77, *Eth.Pr.Sph.*) in the form of a bone composed of horizontal and vertical portions, and therefore T-shaped in transverse section. The horizontal portion (fig. 75) is shield-shaped, and appears on the surface of the skull between the posterior ends of the nasals (fig. 50): it is marked dorsally by a pair of sigmoid grooves (fig. 75) laterad of which it is covered, in the entire skull, by the nasals. The vertical portion ossifies the whole postero-dorsal region of the mesethmoid (fig. 56) and ends below in a rounded border. The bone in question is obviously partly mes- and partly ecto-ethmoidal: moreover, it subsequently extends caudad so as to ossify the presphenoid, so that it may be conveniently called the *ethmo-presphenoid.*

One of the most striking characteristics of the skull of *Apteryx* is the extreme complexity of the turbinals. When the mesethmoid is removed (fig. 57) there are seen in the olfactory chamber proper four well-marked obliquely vertical folds, while a fifth is continued into the narrow or respiratory portion of the nasal cavity. The three hindmost of these folds are perfectly distinct from one another, and I propose to call them respectively the *anterior* (*A.Trb.*), *middle* (*M.Trb.*) and *posterior* (*P.Trb.*) turbinals. The fourth and fifth folds are intimately connected with the anterior turbinal: I call the uppermost of the two, which forms part of the olfactory region, has *anterior accessory turbinal* (*A.A.Trb.*), and that which extends forwards, and has no olfactory function, the ventral accessory turbinal (*V.A.Trb.*).

In describing these complex structures it will be necessary to refer, not only to dissections, but to transverse and horizontal sections (Plates 7 and 11).

The posterior turbinal (figs. 57, 75, 83, 84, and 158, *P.Trb.*) has the form of a scroll attached by the whole of one edge to the aliethmoid. It is rolled upon itself caudad (fig. 83) forming about one turn. Like the other turbinals its line of attachment is oblique, passing from above forwards, as well as downwards.

The middle turbinal (figs. 57, 75, 83, 84, 157, and 158 *M.Trb.*), is also attached along the whole length of one nearly vertical edge: from its attachment it passes at first mesiad (fig. 83), then turns caudad, then laterad, then mesiad again, and passes cephalad as a broad plate somewhat indented in the middle by a vertical furrow, which gives it the appearance when viewed from its inner face (fig. 57) of a double fold. The broad vertical plate thus formed is attached to the aliethmoid along the anterior part of its ventral border, but is free dorsad, its apparent connection with the dorsal wall of the olfactory chamber in fig. 57 being due to the fact that the mucous membrane is not removed: anteriorly it is rolled upon itself caudad (figs. 83 and 84), forming a scroll of one turn, which is attached to the aliethmoid above and below, but is free in the middle.

The anterior turbinal (figs. 57, 75, 83, 84, and 157, *A.Trb.*) arises as a single, somewhat oblique plate from the aliethmoid. Soon after its origin it turns caudad (fig. 83), then cephalad, then caudad again, and finally curves forwards, forming a single oblique scroll with an in-turned anterior border.

The anterior accessory turbinal (figs. 57, 77, 83, 84, 155, and 156, *A.A.Trb.*), arises dorsally as a narrow plate springing from the anterior turbinal near its origin (fig. 83); it passes forwards and downwards, and merges into the hollow ingrowth of the ectoethmoid mentioned above (p. 49, figs. 84, 155, and 156). It thus happens that the main part of the anterior accessory turbinal is not a plate-like ingrowth, but an actual hollow invagination of the ectoethmoidal wall. In it, as already mentioned, is inclosed the antero-dorsal branch of the antrum of HIGHMORE. At its anterior and ventral end this pouch gradually narrows, and passes insensibly into a plate of cartilage, which joins the ventral accessory turbinal, gradually fading away on the dorsal surface of the latter.

The ventral accessory turbinal (figs. 57, 76, and 153–156, *V.A.Trb.*) consists of a horizontal plate of cartilage attached along its whole length to the ectoethmoid, and connected caudad with the ventral border of the anterior turbinal. At its posterior end it is a simple narrow plate, but soon divides into two plates, a dorso-mesial and a ventro-lateral (fig. 155), which continue forwards, enclosing between them a dihedral angle. The dorso-mesial plate is rolled upon itself dorsad, and comes to an end a short distance in front of the anterior end of the anterior accessory turbinal (fig. 57). The ventro-lateral plate is rolled upon itself ventrad, and is continued forwards, undergoing a gradual simplification of structure, as far as the junction of the second and third portions of the ectoethmoid (fig. 153).

As already mentioned, all the turbinals, with the exception of the ventral accessory, are covered with Schneiderian membrane, and are therefore analogous to the ethmo-turbinals of a mammal. The ventral accessory turbinal is covered with ordinary mucous membrane, and belongs to the merely respiratory portion of the nasal chamber: it may be compared with maxillo-turbinals of mammals.

There is also, separated by a considerable interval from the turbinals proper, a fold which may be compared with the naso-turbinal of mammals. This (fig. 151, *Na.Trb.*) is a narrow, horizontal, shelf-like plate of cartilage springing from the inner face of the first or anterior portion of the ectoethmoid, and extending from a little in front of its junction with the second portion as far forwards as the nostril.

It may be mentioned in this connection that the lining of the nasal sac from the nostril nearly as far back as the junction of the second and third portion of the ecto-ethmoid—*i.e.*, the preturbinal portion of the olfactory chamber—has the character rather of skin than of mucous membrane, its epithelial layer consisting of a stratum Malpighii covered by a very thick stratum corneum closely resembling, and actually exceeding in thickness, the horny beak (see Plate 12, fig. 151).

On each side of the ventral edge of the mesethmoid in the vomerine region, *i.e.*, from about the posterior end of the third to the middle of the fifth portion of the ectoethmoid, is a slender rod of cartilage (figs. 76, 77, and 155–157, *Ja.C.*), imbedded in connective tissue, and lying parallel to and either immediately dorsad or slightly laterad of the dorsal edge of the trough-like vomer. It is about 10 mm. long, and about 0·14 mm. in diameter, and is most easily made out in sections, although when once its position is known, it can be readily prepared in a well-macerated skull by carefully removing the vomer. It is obviously the vestigial cartilage of JACOBSON'S organ, first described by my Father in *Rhea* (30), and afterwards in various Passerine Birds (36).

The *quadrate* (tympanic, OWEN*) has practically the same form as in the adult. The otic process (fig. 79, *ot.pr.*) bears a large transversely elongated articular head covered with cartilage, and having its mesial extremity widened antero-posteriorly. This portion of the head of the quadrate bears a well-defined, nearly circular, slightly convex facet (*pr.ot.*) for articulation with the surface already noticed on the prootic (p. 73, fig. 78, *qu.*^{1}). The lateral narrow portion of the head of the quadrate (fig. 79, *sq.*) articulates in front with the surface already noticed on the alisphenoid (p. 78, fig. 78, *qu.*^{2}), and behind with a small cartilage-covered facet on the squamosal (p. 97, fig. 78,

---

* The revival by GADOW (12) of the Okenian hypothesis of the homology of the sauropsidan quadrate with the mammalian tympanic is an instructive instance of the way "the whirligig of time brings in his revenges." One had lately been content to think that this question was finally settled in 1869 in favour of the REICHERT-HUXLEY view, or some modification of it.

qu.^{3}). Thus, in *Apteryx*, the quadrate can by no means be described as having a single-headed otic process.

The orbital process (*orb.pr.*) is tipped with cartilage. The shaft of the quadrate bears on its posterior surface a large pneumatic foramen (*pn.f.*) leading obliquely downwards and forwards into a cavity excavated in the interior of the bone. Ventrally the quadrate is tipped with cartilage, and bears the usual two condyles, one (*cn.* 1) mesiad and slightly cephalad of the other (*cf.*, fig. 51). Lying almost immediately cephalad of the external condyle is a deep hemispherical cavity for the articulation of the quadrato-jugal, while dorsad of the internal condyle, and at the base of the orbital process is a somewhat ill-defined surface for articulation with the pterygoid.

The *articular* (figs. 54–56 and 80, *Art.*) is a concavo-convex bone, largely covered with cartilage both dorsad and laterad. From its anterior border the long slender MECKEL'S cartilage (*Mck.C.*) is continued forwards and slightly inwards until it reaches the posterior end of the long mandibular symphysis, when it turns directly forwards, and passes parallel to and in close contact with its fellow of the opposite side to within a short distance of the end of the beak (*cf.* figs. 151–160). There is no trace of a basi-mandibular element.

The *stapes*, or columella auris (fig. 81), is not described by OWEN. It consists of the usual oval plate of bone (*Col.*) inserted in the fenestra ovalis, and continued into a short bony rod, which passes outwards and forwards, and bears at its distal end a triradiate cartilage, the extra-columella (*Ex.Col.*) of GADOW (11). The middle of the three rays, or extra-stapedial (*E.St.*) continues the direction of the bony columella, and is fastened distad to the inner surface of the tympanic membrane. The second ray, or supra-stapedial (*S.St.*), is dorsal and posterior in position, and has its extremity thickened and produced into a small retral spur directed ventrad; it is also attached to the tympanic membrane. The third ray, or infra-stapedial (*I.St.*), springs from the ventral region of the extra-columella close to its proximal end, and immediately opposite the supra-stapedial: it passes forwards and downwards to the anterior tympanic recess, where it becomes ligamentous. In serial sections of Stage H it can be traced to a point about 0·75 mm. dorsad of the internal angle of the articular, beyond which it disappears as a distinct structure.

The *tongue-bone*, or so-called hyoid (fig. 82), consists of a median sagittate cartilage (*B.Br.*) called basi-uro-hyal by my Father (28), produced backwards into a slender-pointed rod. With the lateral processes of this cartilage are articulated the posterior cornua, each of which consists of an ossified ceratobranchial (*C.Br.*) with cartilaginous ends, and of an unossified epibranchial (*E.Br.*) pointed distad. Imbedded in the extremity of the tongue is a Y-shaped cartilage, having its stem (*B.Hy.*) directed forwards, while its arms (*C.Hy.*) extend backwards and embrace the median cartilage (*B.Br.*): the point of the latter is connected by ligament with the re-entering angle of the Y. This answers to the heart- or arrow-shaped cartilage found in most birds, and considered by my Father as being formed of partially concresced ceratohyals.

I am disposed to take a different view of the composition of the avian "hyoid." I consider the arms of the Y-shaped cartilage (*C.Hy.*) to be ceratohyals, and its median portion or stem (*B.Hy.*), the basihyal, formed as it obviously is by concrescence of the right and left halves of the hyoid arch. The sagittate cartilage (*B.Br.*) I consider to be the first basibranchial.

According to this view there is no concrescence between the hyoid and first branchial arches in *Apteryx*; they remain united only by ligament, so that in preparing the skeleton by maceration the first branchial (so-called hyoid) readily separates, leaving the true hyoid imbedded in the end of the tongue, where it is easily overlooked. Moreover, the hyoid is obviously obsolescent; as will be shown, it chondrifies late and never ossifies.

The Membrane Bones.

The *parietal* (fig. 62) is an irregularly four-sided concavo-convex bone. By its straight mesial border it is joined by membrane to its fellow of the opposite side (fig. 50): its sigmoid anterior border articulates with the frontal, and its irregular lateral border with the squamosal, while its irregular posterior border abuts against the occipital cartilage partly in the supra- and partly in the ex-occipital region (fig. 53). At its postero-lateral angle is a pit (*pn.c.*) which fits over and closes above the hinder division of the pneumatic cavity in the prootic (figs. 75 and 77, *pn.c.*).

The *frontal* (fig. 63) is a very irregular concavo-convex bone, broadest at its posterior end and narrowing cephalad. By its evenly curved posterior border it articulates with the parietal; its nearly straight mesial border is separated from that of its fellow of the opposite side by membrane (fig. 50); its arched lateral border, straight as seen from below, articulates with the alisphenoid. In front it is produced into a narrow nasal process (*na.pr.*), which articulates with the postero-lateral border of the nasal. Immediately cephalad of its alisphenoid border the frontal is produced into an orbital process (*orb.pr.*), which curves downwards and inwards and abuts against the aliethmoid (fig. 52); from its antero-ventral angle is sent off an irregular orbitosphenoid process (*o.sph.pr.*), which passes directly mesiad and overlies the orbitosphenoid bar (fig. 56, *o.sph.pr.*). Thus the frontals nearly meet in the middle line over the presphenoid, reminding one of the arrangement found in some of the Primates.

Immediately cephalad of the orbital process is a large notch, covered in the entire skull by membrane, and converted into a foramen, the superior orbital fontanelle (fig. 52, *S.orb.F.*), by the juxtaposition of the aliethmoid. From the dorsal border of this foramen a pedate descending process (*d.pr.*) is given off, and passing downwards and slightly forwards, abuts against the convex lateral surface of the aliethmoid. The orbitonasal nerve passes immediately mesiad of this process in its course from the orbit to the nasal cavity.

The *squamosal* (fig. 69) is a roughly triangular bone articulating by its sinuous dorsal border with the parietal, by its concave anterior border with the alisphenoid and by its thickened ventral border with the prootic and exoccipital. Its ventral region is hollowed out into a pneumatic cavity (*pn.c.*), which in the entire skull fits over the anterior division of the hollow in the prootic already described (p. 45, figs. 75 and 77, *pn.c.*, and fig. 170), the posterior division, as already stated, being covered by the parietal. The antero-ventral angle of the squamosal is produced into a triangular zygomatic process (*zyg.pr.*) which is directed forwards and downwards immediately laterad of the otic process of the quadrate (fig. 52). Just mesiad of the base of this process the squamosal bears on its antero-ventral angle an articular facet covered with cartilage (*qu.*^{3}) for the posterior surface of the external division of the head of the quadrate. Caudad of this facet, the ventral edge of the squamosal is perforated by a considerable aperture (indicated by a bristle in fig. 69) by which the air-cells just mentioned communicate with the tympanic cavity (*cf.* fig. 78, *qu.*^{3}, *pn.c.*, and figs. 169 and 170).

With regard to the cartilaginous facet *qu.*^{3} it is an interesting question whether the presence of a distinct chondrite developed in connection with a parostosis is an indication that the latter is phylogenetically a cartilage bone, like the palatine and pterygoid of Sauropsida and Mammalia, or whether the chondrite in such cases is to be considered as a neomorph. In any case the cartilage now under consideration is comparable and may possibly be homologous with the meniscus of mammals, while it certainly corresponds with the cartilaginous facet on the squamosal of lizards (33).

The *nasal* (fig. 66) is a long narrow bone crescentic in cross section (Plate 13, fig. 155), pointed in front, and irregularly truncated behind. By its posterior border it articulates with the frontal, and by the greater part of its mesial border with the nasal process of the premaxilla: caudad of that process the nasals diverge so as to allow the central part of the ethmo-presphenoid to appear (fig. 50). From the posterior end of the lateral border of the nasal springs a slender descending process (*d.pr.*) which takes a direction downwards and slightly forwards, abutting against the ectoethmoid and articulating caudad with the lacrymal (figs. 50 and 52).

The *lacrymal* (fig. 68) is a small irregular bone consisting of a shell-like central portion applied to the surface of the aliethmoid (fig. 52), and of an ascending portion which articulates with the descending process of the nasal. It is perforated obliquely by the lacrymal foramen (*lac.for*).

The *premaxillæ* (fig. 59) are already ankylosed together, forming a long triradiate bone. The common portion or body of the bone is small and rounded, forms the tip of the beak, and is honey-combed with small close-set pits in which are end-organs abundantly supplied by branches of the dorsal ramus of the orbitonasal nerve. The nasal process (*na.pr.*) is also single, except at its posterior end, where there is a longitudinal cleft. The palatine processes (*pal.pr.*) are quite distinct, each being attached to the body of the bone by a narrow neck, widening as it passes backwards, and finally dividing into a short mesial, and a long lateral process, both of which articulate with the maxilla. The external nostril lies at the junction of the nasal and palatine processes with the body.

The *maxilla* (fig. 58) is a long flat bone pointed in front where it is underlaid by the palatine process of the premaxilla: it gradually widens as it passes backwards and divides into two processes, an internal or palatine (*pal.pr.*), and an external or jugal process (*ju.pr.*). Mesiad of the anterior end of the palatine process is a groove bounded dorsad by an extension of the inner margin of the bone, and serving for the reception of the palatine (*cf.* figs. 50 and 51). The outer border of the maxilla forms part of the boundary of the upper jaw, by its inner or mesial border it articulates with its fellow for a short distance in front, afterwards separating from it so as to leave a narrow lanceolate interval partly filled up by the vomer. The palatine process of the maxilla underlaps the palatine bone towards its outer border; the jugal process articulates dorso-laterad with the jugal.

The *jugal* (fig. 70) is a slender rod-like bone, articulating by its anterior half with the jugal process of the maxilla, and behind articulating by its dorsal surface with the quadrato-jugal.

The *quadrato-jugal* (fig. 71) is a slender bone, pointed in front where it underlies the jugal, and thickened posteriorly where it articulates with the pit already noticed on the quadrate (p. 52) by a knobbed extremity (*qu.*) covered with cartilage (see also fig. 165, *Qu.Ju.*). This is a second instance in the skull of *Apteryx* of a parosteal bone provided with a cartilaginous articular end.

The *vomer* (fig. 60) is Y-shaped, consisting of a median anterior limb and slightly diverging posterior limbs. The anterior limb which projects between the maxillæ is trough-like, and pointed in front, the posterior limbs have their ventral surfaces slightly concave from side to side, and their posterior ends forked: each articulates at its hinder end dorsad with the pterygoid and ventrad with the palatine (see also figs. 155–157).

The *palatine* (fig. 61) is of very irregular form, its pointed and jagged anterior end fits into the groove on the inner border of the maxilla, the palatine process of which is applied to the whole length of its ventro-lateral surface. Its posterior end is expanded and obliquely truncated: it underlies the hinder end of the vomer, and articulates laterad with the pterygoid.

The *pterygoid* (fig. 67) terminates caudad in a saddle-shaped surface covered with cartilage (*qu.*) for articulation with the quadrate. The posterior end of the bone has the form of a stoutish rod, somewhat flattened from above downwards, and bears on its mesial surface a slightly elevated, longitudinally oval facet (*b.ptg.pr.*), covered with cartilage, for articulation with the basipterygoid process. The anterior two-thirds of the bone is flattened from above downwards, and produced dorsad into an obliquely longitudinal ridge, and divided anteriorly into mesial and lateral processes.

The mesial process articulates with the lateral border of the vomer, and with the posterior expanded portion of the palatine, the lateral process articulates with the dorso-lateral border of the palatine, and of the palatine process of the maxilla.

The *dentary* (fig. 72) is already ankylosed with its fellow of the opposite side, forming a symphysis about 1·5 cm. long. The symphysial portion of the united bones is narrow, deeply grooved longitudinally on its dorsal surface, and pitted below (fig. 55) like the corresponding part of the premaxilla. Each ramus consists of a horizontal dorsal plate, and an oblique ventral plate, the two joining laterad in an acute dihedral angle : posteriorly these two plates are separate, and form slightly divergent dorsal and ventral processes.

The *splenials* (fig. 64) are also ankylosed, forming a symphysis nearly 1 cm. long. Each has a nearly flat mesial and a strongly-grooved lateral surface. Thus, when the dentary and splenial are placed in position, they enclose between them a longitudinal canal for MECKEL'S cartilage (fig. 153).

The *angular* (fig. 65) is a narrow splint-like bone, with its broad, flattened posterior end applied to the mesio-ventral region of the articular (figs. 55 and 56). The main part of the bone extends forwards between the splenial and the ventral process of the dentary, forming the posterior portion of the ventral edge of the mandibular ramus.

The *supra-angular* (fig. 73) has its broad, irregular, somewhat thickened posterior end applied to the ventro-lateral region of the articular (figs. 52 and 55). The rest of the bone is a narrow slightly-twisted splint, which extends forwards between the splenial and the dorsal process of the dentary.

The *coronary* (fig. 74) is a slender, rod-like bone, somewhat broadened and truncated at its posterior end and pointed in front. It lies on the inner face of the mandibular ramus (figs. 54 and 56) near its articular end, between and nearly parallel with the angular and supra-angular.

The relations of both cartilage and membrane bones are well shown in the series of sections of Stage H (Plates 12–14).

b. Development of the Skull.

Stage A (Plate 4, figs. 17–21).

The parachordal region or investing mass is represented by a plate of dense blastema on each side of the notochord, and extending a short distance cephalad of its anterior end as the "middle trabecula" of RATHKE (fig. 17, *Pr.Ch.*). This name my Father (29) proposes to drop, as the structure in question has nothing to do with the trabeculæ cranii. As, however, a distinct chondrite subsequently appears in it, which gives rise to part of the dorsum sellæ, and as it is apparently the first part of the skull to appear, being at the present stage decidedly better marked than the parachordals, I think it will be convenient for descriptive purposes to speak of it as the *prochordal plate.*

The end of the notochord (*Nch.*) is simply upturned, not bent into a hook-like form as in Selachians (2, 47), or twisted as in *Chelone* (35). The next stage shows this very clearly, since the notochord never appears twice in the same transverse section (figs. 24 and 25).

There is a concentration of the mesoblastic tissue in the visceral folds (figs. 19–21), but the visceral arches can hardly be said to be formed as yet.

Stage B (Plate 4, figs. 23–30).

The prochordal plate has become a very distinct unpaired structure (fig. 23, *Pr.Ch.*), reaching from the end of the notochord, dorsad between the metencephal (*Mt.cœ.*) and diencephal (*Di.cœ.*). The third nerve (*Nv. III.*) passes through it in its course from the base of the mid-brain. A very short distance caudad of the junction of the prochordal with the parachordal plates the latter are seen to be distinctly paired (figs. 25 and 26, *Pa.Ch.*), the thickenings of mesoblast which form them not meeting either above or below the notochord. Except at their extreme anterior limit (fig. 24) the parachordals remain thus distinct through their whole extent (figs. 25–30), and are uniformly less well-marked than the prochordal.

In the auditory region the thickened mesoblast of the parachordals is seen to be extending laterad, so as to invest the auditory sacs (fig. 28).

The visceral arches (fig. 26, *Mn.*; fig. 27, *Hy.*) are visible as plates of dense blastema, but, with a single specimen, their precise relations could not be very satisfactorily made out.

Stage C. (Plate 5).

The prochordal plate is still better defined than in the previous stages, and is produced at its free end into paired processes (fig. 35, *Pr.Ch.*), which lie immediately laterad of the oculomotor nerve (*Nv. III.*). A short distance in front of (above) the end of the notochord, the prochordal forms a well-marked transverse plate (fig. 36, *Pr.Ch.*), narrow towards the middle line, broadened at either end, and perforated by the third nerve.

I have seen no references to the bifurcation of the "middle trabecula" just referred to. The two processes have exactly the same relation to the main unpaired portion of the prochordal plate as the trabeculæ to the anterior unpaired portion of the parachordals (*vide infra*); and bearing in mind GÖTTE's theory that the trabeculæ represent a pair of neuroids (neural arches), and ALBRECHT's notion (1) that the dorsum sellæ is a "Wirbelcentrum-complex," it is tempting to compare these processes also with neuroids. But it yet remains to be seen whether they exist in the lower Vertebrata, and, if so, whether they are independent elements like the trabeculæ, or, as in the present case, mere processes of the prochordal plate.

The parachordals are well defined anteriorly, and have united dorsad of the notochord (fig. 37), but for the greater part of their extent they are still separate (figs.

38–42), and have not yet passed into the condition of prochondral tissue. The lateral extensions from the parachordals forming the auditory capsules are well seen in this stage (figs. 39 and 40, *Au.c.*).

The trabeculæ (fig. 37, *Tr.*) have apparently just made their appearance. In sections which include the anterior end of the notochord and the pituitary evagination (*Pty.*) of the pharynx, they have the form of short paired rods, springing from the united parachordals, and passing immediately laterad of the internal carotids (*Int.car.*), so as partly to embrace the pituitary body.

The visceral arches are more clearly marked than in the preceding stage, the mandibular (fig. 38, *Mn.*), hyoid (fig. 39, *Hy.*), and first branchial (fig. 41, *Br.* 1) being very obvious.

Stage D (Plate 9, figs. 85–95).

Owing to the unfortunately damaged condition of the single embryo belonging to this stage, my observations are far from complete. The drawings of sections (figs. 88–95) are accurate, only obvious distortions having been corrected, but the figures of the entire skull (figs. 85 and 86) must be looked upon as restorations from very imperfect data.

The cerebral flexure is still nearly a right angle ; the sections cut at right angles to the long axis of the beak, become horizontal in the parachordal region (*cf.* figs. 88–93 with figs. 94 and 95). The advance beyond the preceding stage is very marked ; all the parts of the chondrocranium are formed, and consist, for the most part, of hyaline cartilage.

The parachordals (figs. 86, 94, and 95, *Pa.Ch.*) have to a considerable extent concresced below the notochord; anteriorly, however, they are still separate, a median slit-like space, the posterior basicranial fontanelle (figs. 86 and 94, *p.bcr.fo.*), being left between them. The anterior boundary of this aperture is formed by the inturned hook-like anterior ends of the parachordals (*y.*) which meet in the middle line, and, at the same time, form the posterior limit of the carotid foramina (*Int.car.*).

The precise form of the auditory capsules could not be deduced with accuracy from the sections, but it is almost certainly not very different from what we find in the next two stages in which it was made out by dissection.

In the basisphenoidal region (figs. 86, 93, and 94, *B.Sph.*) the skull-floor is widely open below, the trabeculæ not having united in the middle ventral line. The space thus formed is filled with connective tissue which supports the pituitary body (*Pty.*), and through which the internal carotid arteries (*Int.car.*) enter. Cephalad of the pituitary body the trabeculæ are in close contact, save for a thin stratum of prochondral tissue (fig. 92, *B.Sph.*), and each sends off outwards and downwards a large basipterygoid process (*B.ptg.pr.*), the size of which, so much greater proportionally than in later stages, is worthy of notice.

In the posterior presphenoidal region (fig. 91, *Pr.Sph.*) the trabeculæ are still separated by a layer of prochondral tissue, and each sends off dorsad a vertical plate (*Pr.Sph.′*), which bounds the optic foramen (*Nv. II.*) in front, and at its dorsal edge is continued into the orbitosphenoid (*Orb.Sph.*). In later stages, these vertical offshoots of the trabeculæ have united in the median plane to form the impaired presphenoid cartilage (*cf.* figs. 86 and 91 with figs. 98 and 116); their distinctness in the present stage is interesting as showing that the prenasal cartilage or intertrabecula does not extend so far back in Birds as in Crocodiles (34, Plate 63, fig. 4), and Turtles 35, Plate 2, fig. 6).

In the anterior presphenoidal region (fig. 90, *Pr.Sph.*) the trabeculæ are continued into a single cartilage, pyriform in transverse section; its ventral region is unpaired, and may possibly, though not probably, be formed from a prenasal cartilage, but its dorsal region is still unchondrified in the median plane, and the whole structure appears to be a continuation of the trabeculæ.

The mesethmoid (figs. 85, 86, 88, 89, *M.Eth.*) is well chondrified below, but the formation of cartilage has not yet extended to its dorsal border; it shows no indication of being formed from paired trabeculæ.

The lateral offshoots of the trabecular region of the skull are already well developed. The ectoethmoids (*Ec.Eth.*) are only chondrified posteriorly; they already extend backwards caudad of the middle of the eye (fig. 90). The orbitosphenoid plates (*Orb.Sph.*) are immense; they spring from the whole length of the long presphenoid region and extend backwards, bounding the optic foramen (*Nv. II.*) above, as far as the parachordal region. The alisphenoids (*Al.Sph.*), on the other hand, are comparatively small, and owing to the cerebral flexure their long (antero-posterior) axis is nearly vertical instead of horizontal. The trigeminal (*Nv.* $V.^{2,3}$) and orbito-nasal (*Nv.* $V.^{1}$) foramina have their usual position between the alisphenoid and the auditory capsule. In these and other points the resemblance of the Kiwi's skull at this stage to that of an embryo Mammal (32, Plate 33, fig. 3), or Crocodile (34, Plate 63, fig. 6), is very striking.

The only indication of the turbinals is an in-pushing of the ectoethmoids immediately over the posterior nares (fig. 89, *A.A.Trb.*). This is the rudiment of the anterior accessory turbinal, which is thus the first of these ectoethmoidal folds to appear.

The quadrate (*Qu.*), as far as could be made out from the sections, has a single head articulating with the prootic region of the auditory capsule. The mandible (*Mck.C.*) consists entirely of MECKEL's cartilage, which is expanded at its proximal or articular end.

The columella (figs. 87 and 93, *Col.*) has its knotted mesial end inserted into the fenestra ovalis, and its outer end or extra-stapedial (*E.St.*) fixed to the tympanic membrane; near the middle of its length it gives off a slightly curved downwardly directed process, the infra-stapedial. I can detect no trace of supra-stapedial.

The tongue-cartilage (so-called hyoid) consists of a median basibranchial (fig. 90, *B.Br.*) giving attachment laterad to a pair of cerato-branchials. There is no trace of the Y-shaped cartilage of the adult and advanced embryo (fig. 82, *B.Hy.*), which I take to represent the hyoid arch. The late appearance of this structure is a good indication that the hyoid proper of Birds is tending to disappear. It is worthy of notice that cerato-hyals are figured in my Father's second stage of the Chick's skull (31, Plate 81, fig. 5), which corresponds roughly in point of development with the Kiwi embryo now under discussion; this would seem to show that *Apteryx* is a step nearer atrophy of the hyoid than *Gallus.*

There is no trace of the palato-pterygoid bar described in early embryos of the Chick (31, Plate 81, figs. 1, 3, and 5): in *Apteryx* the palatine and pterygoid are in no way distinguishable in their development from the remaining membrane bones.

Stage E (Plate 10, figs. 96–103).

In the single embryo belonging to this stage the brain was removed and the chondrocranium drawn from above and roughly sketched from the side before being sectioned. Hence fig. 97 is a drawing of an actual dissection, and figs. 96 and 98, although in part restorations, are correct in all their main features.

The cerebral flexure is now about 120°. The general proportions of the skull are much the same as in the previous stage.

In the parachordal region the notochord (*Nch.*) is clearly seen, and is shown by sections to be surrounded with cartilage only in the neighbourhood of the occipital condyle. Elsewhere the parachordal cartilages have not met above the notochord, and their union below it does not extend very far forwards. The occipital arch is completed dorsad by prochondral tissue.

The auditory capsules (*Au.C.*) have rounded dorsal and mesial contours; laterad they are produced into well-marked paroccipital processes (fig. 96, *pa.oc.pr.*) bounding the tympanic recesses. The foramina for the facial and auditory (*Nv. VII., VIII.*), and for the glossopharyngeal and vagus (*Nv. IX., X.*) nerves are well seen, but there is no indication of the floccular fossa.

The pituitary fossa (fig. 97, *Pty.F.*) is a deep pit with a nearly circular outline, bounded in front by the presphenoidal region and behind by the high dorsum sellæ or postclinoid wall (*Dors.sell.*), which extends transversely between the alisphenoids. In a dissection such as that from which fig. 97 is taken, the fossa appears to be completely bounded by cartilage, but sections show that this is not the case. The middle portion of the dorsum sellæ is formed of connective tissue (fig. 101) in which the upturned end of the notochord is embedded, and the floor of the fossa contains three median fontanelles filled with fibrous tissue continuous with the perichondrium. The hindmost of these (figs. 98 and 101, *p.bcr.fo.*) is the posterior basicranial fontanelle already noticed (p. 58): it is bounded behind by the notochord (*Nch.*) and its ventral cartilaginous investment, and in front by a transverse bar of cartilage (*y.*) which separates it from the next or middle basicranial fontanelle (*m.bcr.fo.*). This latter looks, in the present stage, almost directly forwards, and is separated from the third or anterior basicranial fontanelle (*a.bcr.fo.*) by another transverse bar of cartilage (*x.*). The anterior fontanelle is bounded in front by the presphenoid (*Pr. Sph.*), and extending into it from the mouth is seen the remains of the pituitary evagination (fig. 101, *Pty.ped.*). In a section taken very slightly laterad of the median plane (fig. 102), the pituitary fossa is seen to be completely bounded by cartilage, both its floor and posterior wall being fully chondrified: the basicranial fontanelles are, therefore, extremely narrow from side to side.

In the Chick my Father figures only two basicranial fontanelles, corresponding with those I have called anterior and posterior (31, Plate 83, fig. 2) : of the middle aperture I have seen no account in the works of previous observers. My observations are not sufficiently complete to allow of a full explanation of these spaces and of the bars of cartilage which separate them ; but after a careful comparison of this with the previous stage, I am disposed to think that fig. 103 offers a reasonable theory of this most difficult part of the skull. The figure is diagrammatic, and represents the basisphenoidal region on one plane, the cerebral flexure being supposed to be straightened out. The dotted lines show the outlines of the trabeculæ (*Tr.*) and parachordals (*Pa.ch.*), and it will be seen that I suppose the commissure *x* to be formed by the inturned posterior ends of the trabeculæ, the commissure *y* by the inturned anterior ends of the parachordals described in the previous stage (p. 58, fig. 94, *y.*). In the diagram the upturned end of the notochord (*Nch.*) is supposed to be cut off.

The orbitosphenoids (*Orb.Sph.*) are still very large, although smaller than the alisphenoids (*Al.Sph.*). The whole preorbitosphenoidal region is saddle-shaped (fig. 97), being convex from before backwards, and concave from side to side, with, however, a slight rise in the middle (*cf.* fig. 116). The anterior border of the alisphenoid overlaps the posterior border of the orbitosphenoid. The presphenoid (*Pr.Sph.*) is large, and the paired upgrowths of the trabeculæ which form it have apparently completely concresced, but as this part of the skull was sectioned longitudinally, it is impossible to be as certain on this point as if transverse sections also had been examined.

The posterior part of the ectoethmoidal plate (*Ec.Eth.*) is well chondrified, and the three principal turbinals have appeared. The olfactory chamber is continued from the turbinal region to the end of the beak (fig. 100) as a narrow tube lined with a low columnar epithelium, and completely filled with cells evidently derived from the proliferation of the epithelium, so that at this stage there is no actual communication between the olfactory sac and the exterior except by way of the posterior nares and the mouth : this is well shown in fig. 114, taken from a transverse section of the following stage.

The quadrate (*Qu.*) was definitely ascertained to articulate with the auditory capsule by a single head. The columella (fig. 99) shows the three processes of the extra-columellar region ; owing to the cerebral flexure, the direction of the supra-stapedial is backwards and downwards. There is still no trace of the hyoid portion of the entoglossal, but both basibranchial and posterior cornua are well chondrified.

The position of the future membrane bones is indicated in the sections by deeply-stained patches, formed of close-set mesoblast cells. The rudiments of the palatine and pterygoid are in no way distinguishable from those of the remaining parostoses.

Stage F (Plate 10, figs. 104–119).

The skull of this embryo was partially cleaned by dissection, and sketched from above, from below, and from the left side before being stained and sectioned.

The cerebral flexure is greatly reduced, the cranio-facial angle being nearly 150°. This, and the elongation of the prenasal cartilage (*Pr.Na.*) have greatly altered the form of the chondrocranium, which now approaches that of the adult, although still presenting very important differences.

The parachordal region has undergone little alteration: there is a large posterior basicranial fontanelle (*p.bcr.fo*) filled with connective tissue, which is continued dorsad as the median portion of the dorsum sellæ (*Dors.Sell.*), and has imbedded in it the anterior end of the notochord (*Nch.*). Immediately above the latter, but quite independent of it, is a nodule of cartilage (figs. 108, 109, 111, and 112, *Pr.Ch.*), evidently formed as a distinct chondrite in the prochordal plate (Plate 2 and 3, figs. 17 and 36, *Pr.Ch.*). I propose to call it the *prochordal cartilage.* It appears to answer either to the little cap of cartilage which sheaths the end of the notochord in *Chelone* (35, Plate 7, fig. 7*a*), or to the vertical plate, lying altogether dorsad of the notochord (marked *p.cl.*), and forming the dorsum sellæ. In the present instance it is certainly an independent element of the chondrocranium.

On Albrecht's theory (1) that the dorsum sellæ is an "epipituitare Wirbelcentrum-complex," the prochordal cartilage may very fairly do duty for a centrum, the paired processes of the prochordal plate in stage C, representing the corresponding neuroids which atrophy without chondrification, but in the absence of any account of the grounds upon which Albrecht's views rest, beyond the short paper referred to, I am not disposed to consider them as very well founded.

The structure of the pituitary fossa is unaltered, the anterior (*a.bcr.fo.*) and middle (*m.bcr.fo.*) basicranial fontanelles being very obvious. All three fontanelles are of less width from side to side than the prochordal cartilage, as shown by fig. 112, taken about 0·2 mm. from the median plane. The posterior of the two cartilaginous commissures (*y.*) separating the fontanelles is now largely caudad of the anterior one (*x.*), instead of being altogether below it as in the previous stage (*cf.* figs. 101 and 111); this is an obvious result of the straightening of the skull floor.

The alisphenoids (*Al.Sph.*) are somewhat larger than in the preceding stage, the orbitosphenoids are almost unaltered in relative size. The ectoethmoids (*Ec.Eth.*) are still largely composed of prochondral tissue (figs. 113–115), only their posterior portions (fig. 116, *Ec.Eth.* 5) consisting of hyaline cartilage. In addition to the turbinals present in the previous stage, the ventral accessory fold (fig. 115, *V.A.Trb.*) has appeared. Transverse sections of the beak show very clearly the complete filling up of the anterior portion of the nasal chamber with epithelial cells (fig. 114).

The quadrate (*Qu.*) has undergone no alteration : its head is still single, articulating only with the auditory capsule, although, as shown by sections, embraced externally by the rudiment of the squamosal (fig. 119, *Qu.*, *Sq.*). In the columella the infra-stapedial is apparently somewhat longer than in the previous stage. The tongue-cartilage still shows no trace of its hyoid portion (fig. 110).

The membranous foundations of the membrane bones are now well shown, but no actual ossification has yet appeared. In sections (figs. 113–119) the bone-rudiments have very much the appearance of the bones themselves in a later stage after decalcification, except that the matrix, in which the lime salts subsequently appear, takes on a lighter tint with borax-carmine. The identity in mode of development between the palatine and pterygoid and the remaining membrane bones is illustrated by fig. 117, in which the rudiments of the quadrato-jugal (*Qu.Ju.'*) and pterygoid (*Ptg.'*) are seen to be of precisely similar character. There is so far no trace of the cartilaginous articular surfaces on the pterygoid, quadrato-jugal, and squamosal.

Stage G (Plates 11 and 12, figs. 120–145).

This is one of the most important stages in the development of the skull, the chondrocranium having practically attained its final form, and nearly all the membrane bones having appeared. I greatly regret that one of the two specimens belonging to this stage (*A. oweni*) was so much damaged as to be unreliable except for general purposes; all details had therefore to be made out from the complete series of transverse sections of *A. australis.*

The cerebral flexure has almost disappeared, the axis of the prenasal region being very nearly in the same straight line as the notochord. The parachordals have largely united beneath the notochord, but the latter still comes to the surface of the basis cranii. The auditory capsules have nearly attained their adult form ; the floccular fossa (fig. 126, *flc.f.*) is well developed, and a deep groove (figs. 125 and 143–145, *pn.c.*) has appeared on the outer face of the posterior region of the capsule, which, closed laterad by the squamosal, becomes in later stages a pneumatic cavity (*cf.* figs. 75 and 77, *pn.c.*).

Immediately caudad of the dorsum sellæ the parachordals separate in the middle line to form the posterior basicranial fontanelle, the notochord at the same time turning dorsad (figs. 126 and 140, *p.bcr.fo.*). At this level the alisphenoids (fig. 140, *Al.Sph.*) are seen in section to be continuous with the parachordals, and the orbitonasal nerve (*Nv.* $V.^1$) is seen passing through the cartilage to reach the external aperture of the tunnel-like orbitonasal foramen. Considerably less than 1 mm. cephalad of this point (fig. 139), the posterior basicranial fontanelle has come to an end by the formation of the transverse commissure *y* already seen in preceding stages. This commissure (fig. 139, *y.*) unites the parachordals some distance dorsad of their ventral edge, so that these latter project as a pair of nearly parallel ridges (figs. 124 and 139, *r.*) which bound the posterior basicranial fontanelle on either side, and disappear anteriorly at about the level of the carotid foramina (fig. 138, *Int.car.*), *i.e.*, just caudad of the basipterygoid processes.

Immediately above the commissure *y* is the fibrous tissue forming the middle of the dorsum sellæ and containing the nodular prochordal cartilage (figs. 126 and 139, *Pr.Ch.*), the distinctness of which both from the parachordal (*y.*, *r.*) and trabecular regions of the skull is perfectly clear.

The middle basicranial fontanelle has disappeared by the concrescence of the commissures *x* and *y* (fig. 126, *x*, *y.*); the anterior fontanelle (*a.bcr.fo.*) is, however, still present, its general direction being a little forwards from the pituitary fossa as well as downwards, so that the aperture by which it opens on the ventral surface of the skull is just cephalad of the vertical posterior border of the presphenoid (figs. 134 and 135). The pedicle of evagination of the pituitary body (*pty.ped.*) can be traced from the fontanelle forwards and downwards to the mouth, perforating in its course the parasphenoidal rostrum (fig. 134, *Rost.*); the fontanelle itself is covered by the stroma into which the ossification of the rostrum subsequently extends.

The alisphenoid (*Al.Sph.*) has the usual relations; it passes below into the trabecular and parachordal regions, and extends nearly as far forwards as the optic foramen (*Nv. II.*), lying, in the anterior part of its course, outside the orbitosphenoid (figs. 137–139). It is perforated in the usual way by the fifth nerve.

The presphenoid (*Pr.Sph.*) is still nearly as long antero-posteriorly as in the three previous stages, but the orbito-sphenoids (*Orb.Sph.*) have undergone a marked reduction. Posteriorly they form nearly vertical plates bounding the optic foramina above (fig. 136); further forward they lie one on either side of the presphenoid, their point of origin being considerably below its dorsal edge (fig. 135), but gradually rising until in their anterior region (fig. 133), they form lateral offshoots of the dorsal border of the presphenoid as in previous stages, but greatly diminished in width. A comparison of figs. 105, 123, and 75 shows very clearly how the large orbitosphenoid of Stage F becomes a mere band of cartilage in the ripe embryo.

The mesethmoid (*M.Eth.*) has a rounded, rod-like, lower border, its middle portion is narrow from side to side, while dorsad it expands again as it passes into the ectoethmoids, so as to be sub-triangular in section (figs. 131, 132). It presents one peculiarity not met with in any other stage; at the level of the anterior accessory turbinal (fig. 132, *A.A.Trb.*), and of the posterior nares (*Pt.Na.*) it contains near its upper border a small rounded cavity filled with connective tissue (*cr.fa.c.*), about 0·25 mm. in diameter, and probably, since it extends through rather more than 20 sections, nearly 0·5 mm. from before backwards. I am disposed to consider this vacuity as probably homologous with the cranio-facial notch of the Chick (31, Plate 83, fig. 4, *c.f.e.*); I cannot be sure, from my Father's description, whether it corresponds with the fenestra figured by BLANCHARD (*ante*, p. 48).

The ectoethmoids (*Ec.Eth.*) have attained their full development, except that chondrification is still incomplete anteriorly (fig. 129): even the small forwardly-directed process of the fifth portion (fig. 124, *a.*) is already well formed. The turbinals are also fully developed, and all but the naso-turbinal (fig. 129, *Na.Trb.*) are chondrified: the latter, as also the anterior portion of the ectoethmoid, has not even reached the grade of prochondral tissue, but is indicated only by a concentration of nuclei in the mesoblast. Owing to the length of the presphenoidal region the posterior wall of the olfactory chamber or antorbital plate (see p. 48) does not reach backwards to the optic foramen as in later stages. The external nostril and the anterior part (about 4 or 5 mm.) of the nasal chamber are still filled with a solid mass of epithelial cells (fig. 128).

The rudiment of JACOBSON'S cartilage (fig. 132, *Ja.C.'*) appears as a somewhat ill-defined area of prochondral tissue extending through nearly forty sections, and, therefore, probably not more than 1 mm. in length.

The quadrate has the outer side of its head in close proximity to the squamosal (fig. 142, *Qu.*, *Sq.*), but no articular cavity is yet developed for its reception on the latter bone. The cartilaginous mandible—MECKEL'S cartilage (*Mck.C.*) with its articular expansion (*Art.*)—and the columella (*Col.*) have undergone no change of importance, and there is still no trace of the hyoid cartilage beyond a slight concentration of nuclei in the mesoblast of the end of tongue (fig. 132, *C.Hy.'*).

The position and extent of the membrane bones were accurately determined from serial sections, so that figs. 120, 121, and 122, although restorations, are far more reliable than drawings of actual dissections would have been in the present very early condition of the bones. In the sections the bones appear as extremely delicate shining spicules, unstained by carmine: although the head was not decalcified they were not sufficiently advanced to turn the edge of the razor.

The premaxillæ (*Pmx.*) appear in the 34th section, *i.e.*, about 0·5 mm. from the end of the beak, as paired deposits of bone encircling the prenasal cartilage, and nearly meeting above (fig. 127): a few sections further back they have completely united dorsad of the cartilage; and in the 76th section the arch thus formed has divided into a median dorsal and paired lateral deposits, the rudiments respectively of the nasal and palatine processes (fig. 129). It is worthy of notice that even in this early stage there is no indication of the nasal process being double. The extent of the premaxilla is shown in figures 120–122: it reaches only about half-way along the beak.

The maxilla begins immediately caudad of the premaxilla, and already shows its characteristic division into palatine and jugal processes. The jugal (*Ju.*) and quadrato-jugal (*Qu.Ju.*) are delicate styles of bone, and the latter shows no indication of the cartilaginous facet by which in later stages it articulates with the quadrate (fig. 136).

The vomer (*Vo.*) is Y-shaped, and its forwardly-directed stem has nothing to indicate a paired origin. The palatine (*Pal.*) is a simple rod; the pterygoid (*Ptg.*) is forked, and for some distance caudad of the union of its mesial and lateral processes is triradiate in section (fig. 133): further back it becomes a slender rod (fig. 136), and abuts against the basipterygoid process (*B.ptg.pr.*) and the quadrate (*Qu.*): it shows at present neither of the cartilaginous articular facets present in the adult.

The rostrum or anterior division of the parasphenoid (*Rost.*) begins a short distance cephalad of the vomer, and ends just in front of the anterior basicranial fontanelle (fig. 134): it is, however continued backwards beyond the fontanelle by a band of dense mesoblast into which ossification subsequently extends. As already mentioned (p. 64) it is perforated a short distance in front of the anterior basicranial fontanelle by the pedicle of evagination of the pituitary body (*Pty.ped.*). There is no indication of the basitemporals or posterior division of the parasphenoid.

The frontal (*Fr.*) is of considerable extent but very thin: its lower edge is turned in forming an orbital process, but there is, so far, no trace of the remaining processes of the adult bone. Its anterior border is continued forwards for a considerable distance (more than 100 sections, about 2 mm.) by thick fibrous stroma, into which ossification subsequently extends. There is no trace of the parietal, which is thus very late in making its appearance. The squamosal (*Sq.*), on the other hand, is well developed, and is the thickest of all the bones at the present stage: there is, so far, no development of cartilage where it comes into contact with the head of the quadrate (fig. 142).

The nasals (*Na.*) are paired patches of bone on the dorsal surface of the ectoethmoids at the junction of their third and fourth portions. Like the frontal the actual bone is continued some distance, both forwards and backwards, by a thick stroma, into which ossification afterwards extends. The lacrymals (*Lac.*) are small concavo-convex deposits, lying just mesiad of the lacrymal ducts.

The dentary (*Dent.*) begins a short distance cephalad of the anterior end of MECKEL's cartilage (fig. 129) and very soon divides into dorsal and ventral bars, which, after the appearance of the cartilage (fig. 130) lie respectively dorso-laterad and ventro-mesiad of it, but gradually take up the first a lateral, the second a ventral position. The entire bone extends backwards about two-fifths of the length of MECKEL's cartilage, and is continued caudad for a considerable distance by unossified stroma.

The splenial (*Spl.*) begins a short distance caudad of the posterior end of the dentary, and is about half the length of that bone. Both angular (*Ang.*) and supra-angular (*S.Ang.*) commence a little in front of the posterior end of the splenial and extend back to the articular expansion of MECKEL's cartilage. The coronary (*Cor.*) is a slender style situated just in front of the articular expansion.

Stage H (Plates 12–14, figs. 146–171).

In this stage the cartilage bones have appeared; all the membrane bones are present, *i.e.*, the parietals (*Pa.*) and basitemporals (*B.Tmp.*), in addition to those developed in the previous stage; and the skull has, in all essential respects, apart from ankylosis, attained its final form. As shown in fig. 146 (Plate 12), the main difference between the skull at this stage and that of the ripe embryo is the presence of a large fontanelle on the roof of the brain-case, due to the limited extent of the parietals and frontals. There is thus a very considerable gap between stages G and H, and certain points in the history of the skull, and especially of the basisphenoidal region, can only be finally settled by the examination of intermediate stages.

The form of the chondrocranium (fig. 147) differs from that of the ripe embryo only in the more rounded contours of the auditory capsule: it will, therefore, be unnecessary to describe it in detail, except in so far as it is modified by the appearance of the cartilage bones and of the basitemporals.

The basioccipital (*B.Oc.*) is a lanceolate bone surrounding the notochord, and shown by sections (figs. 168–170) to consist of tolerably dense inner (dorsal) and outer (ventral) plates, apparently ectosteal, united by bone of looser texture around the notochord. The exoccipitals (*Ex.Oc.*) are also double, their inner and outer laminæ being continuous round the lateral border of the foramen magnum, as well as round the condyloid foramen (fig. 171). The supraoccipital has not appeared in one of the specimens belonging to this stage (*A. bulleri*, fig. 147); in the other (*A. oweni*) it is present as an impaired ectosteal deposit consisting of outer and inner laminæ. There is no indication of its being formed of paired osteites, as in the Chick (31, Plate 82, fig. 8).

The prootic (*Pr.Ot.*) is a small irregular bone on the inner face of the anterior region of the auditory capsule: it is ectosteal and penetrates for a very short distance into the cartilage (fig. 169). The opisthotic (fig. 171, *Op.Ot.*) is a small endostosis in the postero-ventral region of the auditory capsule, immediately mesiad of the utriculus and laterad of the exoccipital. There is no indication of a separate epiotic, but it appears to be already fused with the supraoccipital, since the latter bone is traceable on each side into the auditory capsule as far as the posterior semicircular canal.

The interpretation of the basisphenoidal region is made difficult by three changes which have occurred simultaneously since the previous stage. The parosteal basitemporals and the endosteal basisphenoid have made their appearance: these two bones have partly ankylosed, and the cartilage of the region has undergone partial absorption.

In the entire chondrocranium the basisphenoid (fig. 147, *B.Sph.*) appears in a view from above as an irregular bone forming the floor of the pituitary fossa and the dorsum sellæ, and ending caudad immediately in front of the posterior basicranial fontanelle (*p.bcr.fo.*), which separates it from the basioccipital. A ventral view (fig. 148) shows the basitemporals (*B.Tmp.*) already united with one another and with the rostrum. Their posterior edge is deeply notched, and between the notch and the basioccipital lies the posterior basicranial fontanelle (*bp.cr.fo.*) filled with connective tissue.

A transverse section through the posterior basicranial fontanelle (Plate 14, fig. 167) shows the cartilage of this region to be hardly at all absorbed, and to consist of paired halves, each with a broad ventral portion bounding the fontanelle (*p.bcr.fo.*) and of a narrow dorsal portion inclined outwards. The basitemporals (*B.Tmp.*) are seen as paired parostoses lying ventrad of the cartilage, passing upwards into the fontanelle and partially ossifying the cartilage on each side. The lateral extension of the basitemporals beyond the cartilage is noteworthy as accounting for the increased breadth of the fully ossified skull in this region (*cf.* Plate 9, fig. 76, with Plate 11, fig. 124), and for the altered position of the carotid foramina, the arteries becoming enclosed between the basitemporals and the cartilage (*cf.* figs. 140 and 167, *Int.Car.*).

The section shown in fig. 166 is taken through the dorsum sellæ, and may therefore be considered as corresponding with fig. 139 (Plate 12) of the previous stage and with fig. 118 (Plate 10) of Stage F. The basitemporals have extended dorsad on each side, so as to come in contact with the basisphenoidal cartilage at its junction with the alisphenoids (*Al.Sph.*). A considerable space is thus shut in on each side of the primitive basis cranii, enclosing the internal carotid (*Int.Car.*) completely and the Eustachian tube (*Eus.T.*) partly. A large cavity (*pn.c.*) is also enclosed in the same space, filled at present with coagulum, but becoming in the adult the pneumatic cavity of the basis cranii. The section passes through the posterior end of the basisphenoid bone (*B.Sph.*), which extends downwards into the cartilage. The latter is largely absorbed, but the irregular area *Pr.Ch.* probably represents the prochordal cartilage, and the mass *y* the commissural band *y* of earlier stages (*cf.* fig. 139).

In the next section figured (fig. 165), which is also through the dorsum sellæ and not more than 0·1 mm. cephalad of fig. 166, the absorption of cartilage has gone farther still, mere traces of the medio-ventral region of the basisphenoid cartilage being left.

The three next sections (figs. 164, 163, and 162) are taken at short intervals between the dorsum sellæ and the pituitary body. In the hindmost (fig. 164) the depression for the pituitary fossa has already begun as far as the cartilage is concerned, but is bridged over by the basisphenoid bone (*B.Sph.*). Thus it would seem that one result of ossification is to fill up the hinder part of the pituitary fossa, and so to reduce slightly its antero-posterior extent (*cf.* Plate 10, fig. 111, and Plate 14, fig. 174).

In fig. 163 the internal carotids (*Int.Car.*) are seen emerging through their foramina into the pituitary fossa, so that this section corresponds fairly with fig. 138 (Plate 12) of Stage G. The cartilage is retained to a greater extent than in succeeding sections, there being a small ventro-lateral patch, which in fig. 162 (Plate 13) is seen to pass into the root of the basipterygoid process (*B.ptg.pr.*). In both fig. 162 and fig. 163 the distinction between the basitemporal and the basisphenoid is well marked ventrally, there being a distinct space between the two. Laterally, however, they pass into one another, and it would require a careful examination of one or more earlier stages to determine exactly their respective limits. As far as I can judge from the whole series of sections of the present stage, the colouring in figs. 161–167 is correct.

Fig. 161 passes through the pituitary body (*Pty.*) and the anterior basicranial fontanelle (*a.bcr.fo.*). The basitemporal covers the fontanelle and is continuous on each side with the basisphenoid, which has here the form of paired ossifications in the cartilage, extending ventro-laterad into the basipterygoid processes.

At the level of the optic chiasma (fig. 160, *Nv. II.*) the basisphenoid cartilage is quite unossified, and is underlaid by the rostral portion of the parasphenoid (*Rost.*), which shows no tendency to invade the cartilage either here or elsewhere.

It appears, therefore, that the basisphenoid bone, in this stage, is an unpaired ossification in the medio-ventral region of the pituitary fossa, extending upwards or backwards into the dorsum sellæ, and sending forward paired prolongations on each side of the anterior basicranial fontanelle; that the basitemporal is a flat bone applied to the basisphenoid and curved upwards on each side so as to abut against the chondrocranium at the junction of the basi- with the ali-sphenoids and enclose paired spaces, external to the chondrocranium but mesiad of the basitemporal, containing the internal carotids and the pneumatic cavities of the skull floor; and that the basitemporal and basisphenoid have already largely ankylosed. In this way the form of the basisphenoidal region is profoundly altered by ossification.

Moreover, a glance at the sections shows that the pituitary fossa is much shallower, and the whole of this region of the skull more depressed, in this than in the preceding stage. Compare particularly fig. 161 with fig. 136, fig. 163 with fig. 138, fig. 166 with fig. 139, and fig. 167 with fig. 140.

The alisphenoid (fig. 165, *Al.Sph.*) is ossified by a double ectosteal deposit. The presphenoid (fig. 159, *Pr.Sph.*) and orbitosphenoids are unossified, but the latter, reduced as already mentioned to a narrow band (fig. 147, *Orb.Sph.*), is overlaid by the orbitosphenoid process of the frontal (fig. 159, *Fr.*).

An endostosis has made its appearance in the mesethmoid (figs. 156, 157, *Eth.Pr.Sph.*), but in the specimen of *A. bulleri* it does not extend to the dorsal border of the cartilage, and is therefore not visible from outside (figs. 146, 147). The turbinals are quite unossified, but the anterior portions of these and of the lateral ethmoids are now fully chondrified (figs. 149–159). The anterior part of the nasal cavity as far back as the junction of the first and second portions of the ectoethmoid is still filled with a solid mass of epithelial cells (figs. 150–152).

The relations of the antrum of HIGHMORE are well seen in this stage. It is a spacious cavity (fig. 158, *Ant.Hgh.*) containing coagulum, lying ventro-lateral of the posterior portion of the ectoethmoid (*Ec.Eth.* 5) and below the orbit. Its posterior limit is at about the level of the hinder boundary of the eye: in front it divides into two branches, one of which (fig. 156, *Ant.Hgh.'*) enters the cavity of the anterior accessory turbinal (*A.A.Trb.*), while the other (*Ant.Hgh.''*) passes forward just outside the ventral region of the ectoethmoid (*Ec.Eth.* 4) and soon ends blindly. I was not able to make out any connection between the antrum and the olfactory cavity.

The body of the quadrate (Plate 14, fig. 165, *Qu.*) is well ossified, but its articular ends (figs. 165 and 169) and orbital process (fig. 160) are still cartilaginous. The otic process has its adult relations, articulating with the prootic, the alisphenoid, and the cartilaginous facet of the squamosal (fig. 169). The articular (fig. 165, *Art.*) is not yet ossified.

The membrane bones have advanced so far that there is nothing to add to the description of Stage K, except to mention that the dentaries and splenials have not yet ankylosed.

Stage I (Plate 14, figs. 172–174).

The advance beyond the previous stage is slight, the most important differences being due to the extension of the cartilage bones. The supraoccipital (fig. 172, *S.Oc.*) is well ossified: the ethmo-presphenoid (*Eth.Pr.Sph.*) has appeared on the surface, and extends both into the ectoethmoids and into the anterior half of the crista galli. All the other cartilage bones have increased in size so as to reduce the width of the synchondroses, and the great fontanelle in the roof of the skull has also diminished considerably.

In two of the specimens belonging to this stage sagittal sections of the basis cranii were made: these are shown in figs. 173 and 174, and illustrate certain points in the structure of this region of the skull with great clearness.

In both sections the basioccipital (*B.Oc.*) is seen to end at the hinder boundary of the posterior basicranial fontanelle (*p.bcr.fo.*), the ventral lamina of the bone extending further forwards than its dorsal lamina. The notochord (*Nch.*) emerging from between the two laminæ, turns upwards and is traceable for some distance up the dorsum sellæ, being imbedded in the periosteum of the latter, and in the connective tissue of the posterior basicranial fontanelle.

In one of the two specimens examined (*A. australis*, fig. 173) a considerable portion of the cartilage of the basisphenoidal region is retained. The median portion of the dorsum sellæ is formed by a large cartilage (*Pr.Ch.*) apparently derived from the prochordal cartilage of earlier stages (Plate 11, fig. 126, *Pr.Ch.*). There is also a large irregular mass of unabsorbed cartilage (*xy*) in the floor of the pituitary fossa, evidently the remains of the commissure marked *xy* in Stage G (fig. 126). The basisphenoid bone (*B.Sph.*) is a thin plate continuous behind with the basitemporal (*B.Tmp.*).

In the other specimen (*A. bulleri*, fig. 174) the basisphenoidal cartilage is completely absorbed and there is no trace of the prochordal nodule. The basisphenoid bone (*B.Sph.*) is continuous with the basitemporal both in front and behind, the posterior ankylosis being immediately cephalad of the posterior basicranial fontanelle (*p.bcr.fo.*), the anterior immediately caudad of the anterior fontanelle (*a.bcr.fo.*).

c. Changes Undergone by the Skull subsequent to Hatching.

Stage L.

In a specimen of *Apteryx australis* a few weeks old the skull is considerably thicker and firmer than at the time of hatching. The intervals between the roofing bones are less than in Stage K, but their edges are still connected by membrane, there being no true sutures.

Stage M.

In the dried skeleton of a young *A. oweni* the various cranial bones are still separate but in close contact with one another, the synchondroses between the cartilage bones being reduced to a minimum, and the roofing bones articulating with one another by true dentated sutures. The ethmo-presphenoid, although larger than in previous stages, has not yet extended into the presphenoid region, which is still cartilaginous. The turbinals had unfortunately been removed in preparing the skull: they were probably not yet ossified.

Stage N.

This stage consists of the dried skull of a young specimen of *A. oweni.* Ankylosis has taken place between the occipital and otic bones and the basi- and ali-sphenoids. The lambdoidal suture is obliterated, but the coronal, sagittal, and frontal sutures still remain, as well as those between the frontals and alisphenoids.

The ethmo-presphenoid bone has extended so as to ossify the presphenoid, nearly the whole of the fifth or posterior portion of the ectoethmoid, the roof of the third and fourth portions, and the greater part of the turbinals: in the mesethmoid it has extended as far forward as the anterior end of the parasphenoidal rostrum. The bony ectoethmoids are still separate from the mesethmoid both ventrad and caudad, but the ethmo-presphenoid has already ankylosed both with the rostrum and with the orbitosphenoid processes of the frontals.

Stage O.

In two sub-adult skulls of *A. oweni* the sagittal, coronal, frontal, and fronto-alisphenoidal sutures are retained. The ectoethmoidal portion of the ethmo-presphenoid bone has further extended and has ankylosed with the perpendicular plate (mesethmoid *plus* presphenoid), the basisphenoid, and the descending process of the frontal. The lacrymal and the descending process of the nasal are still distinct, and the sutures between the premaxillæ, maxillæ, palatines, pterygoids, and vomer are open.

Adult.

In the adult skull the sutures in the brain case have completely disappeared: the nasals have ankylosed with the nasal processes of the premaxillæ, with one another, and with the ethmo-presphenoid: the lacrymal has united with the ectoethmoid and with the descending process of the nasal; and the palatine processes of the premaxillæ, the maxillæ, jugals, quadrato-jugals, vomer, palatines, and pterygoids, are all immovably united together. Thus the quadrate and the columella are the only free bones in the skull. Owing, however, to the slenderness of the connection between the nasal and palatine processes of the premaxillæ, and to the fact that the bones of the palate remain free from those of the base of the skull, the whole palate (*i.e.*, the united palatine processes of the premaxillæ, maxillæ, jugals, quadrato-jugals, palatines, pterygoids, and vomer) can be lifted away from the skull proper, the slender body of the premaxillæ serving as a hinge.

2. The Vertebral Column, including the Ribs.

a. At the time of Hatching (Stage K).

(Plate 15, figs. 175–190.)

The detailed descriptions of the vertebral column in the adult given by Owen (24) and by Mivart (21) allow me to confine myself to such points of structure as can only be made out by the examination of young specimens.

For descriptive purposes I find it necessary to make a slight addition to the terminology of this part of the skeleton. As Baur (4) has pointed out, the so-called neurapophyses and pleurapophyses are not processes of the body but distinct elements, and he, therefore, proposes to call them respectively neuroids and pleuroids. He does not state, however, whether these terms are intended to apply to the cartilaginous or to the bony vertebræ or to both. The distinction is an important one because the ossifications which appear in the neuroids extend ventrad into the centrum, so that the cartilaginous and bony elements of the vertebra do not strictly correspond one with another. In practice I find it very convenient to be able to state without unnecessary circumlocution, not only whether a given process springs from centrum or neuroid, but whether it is connected with the ossification of the centrum or with the ossification of the neuroid.

Starting with the terms chondrite and osteite already proposed (p. 43), the cartilages of which any vertebral segment is formed will be called respectively the *centrochondrite*, *neurochondrites*, and *pleurochondrites*. By the concrescence of these is formed a cartilaginous vertebra, the regions of which are centrum, neuroids, and pleuroids. When ossification takes place one or two centres appear in the body, the *centrosteites,* one in each neuroid, the *neurosteites,* which extend ventrad into the body, and one in each pleuroid, the *pleurosteites.* Thus the entire centrum of the bony vertebra, although co-extensive with that of its cartilaginous predecessor, consists not only of the single or paired centrosteites but of the ventral ends of the neurosteites.

The atlas of a newly-hatched Kiwi (Plate 15, figs. 175 and 176) consists of three distinct osteites, united by synchondrosis. As is proved by the development of the bone (p. 79), the ossification which forms the ventral portion, or so-called body (*pt.oc.int.c.*), is not the centrosteite but a postoccipital intercentrum. It is semilunar in form, having a concave dorsal and a convex ventral border; its anterior face is concave, its posterior face convex, and both are thinly covered with cartilage.

The neurosteites (*n.ost.*) are separated from the intercentrum by broad cartilaginous intervals, and meet with one another in the middle dorsal line by a very narrow synchondrosis. Between the dorsal border of the "body" and the broad cartilaginous ventral ends of the neuroids is a nearly semi-circular notch, across which is stretched a strong transverse ligament (*lg.*) perforated in the centre for the odontoid. In this stage, therefore, the atlas has quite as obvious a dorsal notch as that of the other Ratitæ (*cf.* MIVART, 21, p. 34). There is no trace of the hypapophysis present in the adult, and the hyperapophyses are small.

The axis (figs. 177–179) contains altogether seven ossifications—three in the compound body, one in each neuroid, and one in each pleuroid or transverse process.

The centrosteite of the axis itself (*c.ost.*) forms rather more than the posterior half of the body; it is flat in front, and presents behind the usual saddle-shaped surface covered by cartilage, in which a slight dimple marks the position of the notochord. Immediately cephalad of the dorsal half of this bone is the separate ossification of the odontoid (*Od.*), which as BAUR has shown in Carinatæ, and as will also appear from the consideration of earlier stages (p. 79) is really the centrosteite of the atlas. The odontoid is far less aberrant than in the adult (21, p. 34), being short and blunt with a flat dorsal and a convex ventral surface.

The third ossification of the body (*pt.atl.int.c.*) lies beneath the odontoid and cephalad of the ventral half of the true centrum; it is a tranversely elongated bone with a concave anterior surface. It represents a second or post-atlantal intercentrum.

The neurosteites are united above by a thick mass of cartilage produced into a short blunt neural spine. The perforated transverse processes or pleuroids contain each a small pleurosteite (*pl.ost.*) at its ventral end; this is the "small and rudimentary parapophysial process" of MIVART.

The 3rd to the 15th vertebræ (figs. 180–182) resemble one another in essentials; in matters of detail there is nothing to add to MIVART'S description.

Each contains five ossifications, a centrosteite (*c.ost.*) forming the greater part of the body, paired neurosteites (*n.ost.*), ossifying the neuroids and the dorso-lateral portions of the body, and paired pleurosteites (*pl.ost.*), ossifying the ventral portions of the pleuroids.

The neuro-central suture (*n.c.su.*) is somewhat oblique from before backwards, being lower at its anterior than at its posterior end; as a consequence, a smaller proportion of the body is formed from the neurosteites behind than in front (*cf.* figs. 181 and 182).

The most striking difference of the cervical vertebræ in this stage from those of the adult is their relatively smaller antero-posterior dimensions. This is well seen by comparing fig. 180 with MIVART'S woodcut (21, fig. 34, p. 36) of the corresponding vertebra in the adult.

The 16th (fig. 183) is the last cervical vertebra, according to HUXLEY'S notation, the first dorsal (thoracic) of OWEN, and the cervico-dorsal (better cervico-thoracic) of MIVART. It differs from its predecessors mainly in the large size of its pleurosteites (*Cv.Th.Rb.*), which form slender free ribs about three-fourths the length of the vertebral ribs of the succeeding segment. MIVART does not specially describe the articulation of these ribs. OWEN (24, p. 33) states that "the part corresponding to the head and neck, as usual, is not developed, and it is attached to the transverse process by the part analogous to the tubercle." From this it would follow that in OWEN'S specimen there was no space corresponding to the vertebrarterial canal of the preceding vertebræ.

In the specimen now under discussion there are large cartilaginous parapophyses (*parap.*) springing from the centrum and large cartilaginous downgrowths from the ventral surfaces of the transverse processes or diapophyses (*diap.*). The head of the rib is single, but bears two distinct facets, nearly confluent on the left side, a tubercular facet articulating with the diapophysis and a capitular facet with the parapophysis. Between the two is a well-marked vertebrarterial canal.

The so-called uncinate processes are distinct cartilaginous plates, attached by fibrous tissue to the posterior border of the ribs, and each containing a small endostosis. As they are not processes of the ribs at all, but independent chondrites, I propose to call them simply *uncinates*.* In OWEN'S specimen they were absent in the cervico-thoracic vertebra.

In the 17th or first thoracic vertebra (fig. 184) the head (*capit.*) of the rib is quite short, and the tubercle (*tuberc.*) articulates with a thick cushion of cartilage

---

* FÜRBRINGER states (11, p. 632) that uncinates have not hitherto been found in *Dinornis*. This is certainly not the case; they have obviously not been described, since it is hardly likely that even the most insignificant paper on the subject can have escaped the learned author of the 'Morphologie und Systematik der Vögel'; but they are by no means uncommon in deposits of Moa bones, and are present in no fewer than eight skeletons in the Otago University Museum, usually as distinct bones, but in some cases ankylosed to the ribs.

on the under side of the transverse process (*diap.*). In the second thoracic (fig. 185) this cartilage is reduced in thickness, and at the same time the head of the rib is lengthened. Thus, in passing from the cervical to the thoracic region, there is a gradual ascent of the plane of segmentation between the diapophysis and the tubercle of the rib.

The first four thoracic vertebræ (17th to 20th of the whole series) bear ribs united to the sternum by ossified sternal ribs (see fig. 204); the next four (21st to 24th) have few ribs, and are called by MIVART dorso-lumbar. This name appears to me an unfortunate one; a lumbar vertebra is defined as one devoid of ribs, so that these vertebræ are in no sense transitional between the thoracic and lumbar regions.

The first six thoracic ribs bear uncinates (see fig. 204, *Unc.*); in the seventh and eighth these bones are absent. This is also the case in OWEN'S figure (24, Plates 8 and 9), but it is stated in the text that they are present in all but the last.

The last thoracic (24th) vertebra (figs. 186 and 187, *Th.* 8) shows transitional characters between the remaining thoracic and the lumbar vertebræ. The diapophysis (*diap.*) is short and confluent at its base with the parapophysis, and the capitular and tubercular facets of its ribs are also confluent.

In one of the specimens belonging to this stage, a newly-hatched *A. australis*, the last thoracic is already united to the first lumbar by the concrescence of their centrochrondrites (figs. 186 and 187); their centrosteites are, however, quite distinct, and the only union between the arches takes the form of a narrow longitudinal bridge of cartilage from spine to spine. In an unhatched *A. bulleri* the last thoracic is still free.

The twelve vertebræ following the last thoracic—viz., the 25th to the 36th of the entire series—are united together by complete concrescence of their centrochondrites, and partial concrescence of their arches, by median longitudinal bands uniting the unossified neural spines (fig. 186). Both centrosteites and neurosteites are still quite distinct, and the ilia can be readily removed by maceration, so that there is no difficulty in determining the precise number and character of the vertebræ comprised in the compound sacrum, or, as it may conveniently be termed, *syn-sacrum*. As there is some difference of opinion as to the interpretation of this difficult region, I propose, in the first instance, to describe the facts as I find them in the specimens now under discussion, and afterwards to give the conclusions at which I have arrived as to the classification of the several vertebræ.

In the 26th to the 33rd vertebræ the ventral face of the centrum undergoes a marked flattening, and, as a consequence, the neuro-central suture or synchondrosis is lowered in position (fig. 186). This is especially the case in the 28th vertebra,* in which the centrosteite can barely be seen from the side. At the same time the

---

* In figs. 186–190, the number in brackets is that of the vertebræ in the entire series: *e.g.*, the first caudal is marked *Cd.* 1 (36).

neural canal is greatly increased in vertical extent, to accommodate the sacral enlargement of the myelon.

In the majority of the vertebræ of the syn-sacrum—namely, from the 23rd to the 33rd—the intervertebral foramina (fig. 186, *int.vert.for.*) are vertical slits between the ventral ends of the neurosteites.

The 25th vertebra (*Lb.* 1) resembles the 24th or last thoracic, but its transverse process is smaller, and consists of a low oblique ridge arising entirely from the neurosteite. In the 26th the transverse process is still blunter, and shows a tendency to divide into two parts, a parapophysis (*parap.*) arising partly from the neuro-central synchondrosis, and a very low roughened elevation (*diap.*) on the neurosteite, which represents the diapophysis.

In the 27th and 28th vertebræ the di- and pleur-apophysis are separate. The diapophysis is reduced to a roughened area on the neurosteite, hardly raised above the level of the bone ; the pleurapophysis is a blunt process, arising entirely from the neuro-central synchondrosis, and, in the 28th vertebra, of considerable size (fig. 187, *Lb.* 4, *parap.*).

In the next four (29th–32nd) vertebræ, there is no trace of parapophyses ; in the 29th there is an inconspicuous diapophysial area on the neurosteite, similar to, but smaller than, those on the preceding vertebræ ; in the 30th and 31st there is no trace of this area, these vertebræ being wholly without transverse processes ; in the 32nd, although the parapophysis is still absent, the diapophysis is represented by a low cylindrical cartilaginous elevation, arising from the neuroid immediately above the neurosteite, and abutting against the ilium.

In the 33rd vertebra (*Sc.* 1) the diapophysis is like that of its predecessor, but the parapophysis is an outstanding process containing a distinct ossification, the pleurosteite or sacral rib (*pl.ost.*). In the 34th there is also a distinct pleurosteite, which is curved forwards so as to approach distad the corresponding part of the preceding vertebra, the cartilaginous ends of the two sacral ribs being united (fig. 187) : the diapophysis and parapophysis are united by a vertical ridge of cartilage (fig. 186). In the 35th the di- and par-apophysis are also united by a vertical ridge, and the pleurosteite or sacral rib is short and free at its distal end (fig. 187).

The united ends of the first and second sacral ribs abut against the cartilaginous interval between the ilium and ischium, immediately caudad of the acetabulum and mesiad of the antitrochanter.

The 36th vertebra (*Cd.* 1) has the centrum laterally compressed, and the transverse process is a vertical ridge representing both di- and par-apophysis. The neuro-central suture in this, and indeed in the two or three preceding vertebræ, is precisely at the junction of centrum and neuroid, so that, for the first time, the vertebral body consists entirely of the centrosteite, the neurosteites being confined to the arch.

According to HUXLEY'S notation (16), the 25th to the 28th vertebræ are lumbar, the 29th to the 32nd sacral, while the 33rd to the 36th are the first four of the caudal series. MIVART (21), largely following GEGENBAUR, calls the 25th to the 28th lumbar, the 29th to the 32nd lumbo-sacral, the 33rd to the 35th sacral, and the 36th the first caudal. The two chief factors in determining the question are (1) the origin of the nerves which unite in the sacral plexus, and (2) the presence of distinct sacral ribs. HUXLEY lays the greatest stress on the first of these; both are taken into consideration by GEGENBAUR, as also by MIVART and CLARKE (22*a*), in whose paper the whole question is discussed. My Father (38) follows HUXLEY.

It appears to me that without a fairly complete series of the intermediate forms between Birds and their reptilian or proto-reptilian ancestors, the question is rather one of dialectic than of inductive morphology. After a careful consideration of the arguments, I have come to the conclusion that, in the present case at any rate, GEGENBAUR'S view has the most to be said for it, and that the vertebræ bearing distinct pleurosteites (33rd–35th) are those to which the name sacral should be applied. MIVART'S name, lumbo-sacral, for the presacral vertebræ without parapophyses is convenient, and well worthy of adoption.

The 37th or second caudal is even more compressed than the first, and has no trace of transverse processes. The 38th is somewhat less compressed, and shows no distinction between centrosteites and neurosteites. Its arch bears a very inconspicuous diapophysial tubercle, and there is a distinct neural spine. It is the last vertebra with which the ilia are in contact, so that the syn-sacrum of *Apteryx* includes three thoracic, four lumbar, four lumbo-sacral, three sacral, and three caudal vertebræ.

The name sacro-caudal, applied to the first three caudal vertebræ by MIVART, although convenient in some respects, is hardly necessary. If, in the designation of the vertebræ, the fact of their union in the syn-sacrum is to be expressed, the last three thoracic should be called thoracico-sacral, and all the lumbar, lumbo-sacral. As already stated, I propose to retain the name lumbo-sacral for the 29th–32nd vertebræ, not to intimate their union in the sacrum, but to express the fact that they are vertebræ of a special character, coming between undoubted lumbar and probable sacral vertebræ.

The 39th or fourth caudal is the first free vertebra of the caudal series. It is considerably smaller than its predecessors, and its neural spine is so short as to be practically obsolete. In it also there is no distinction between centrosteites and neurosteites, the ossification of the body passing dorsad into the neuroids. There is a very short and inconspicuous diapophysis. The 40th differs from its predecessor in the possession of a short cartilaginous parapophysis (fig. 187, *Cd.* 5, *parap.*) in addition to a very inconspicuous diapophysis.

In the 41st–43rd (6th to 8th caudal) the di- and par-apophyses have united into a blunt vertically elongated tubercle, which occupies the whole lateral surface of the centrum. The neuroids are united dorsad by connective tissue, so that the short neural spine is double (fig. 189, *Cd.* 8, *neur.*).

In the 44th–46th (ninth to eleventh caudal) the neural canal is open above, the neuroids being widely separated, and, indeed, in the 45th and 46th, slightly divergent (fig. 189). The 44th and 45th resemble their immediate predecessors in general form, but the 46th, or last vertebra of the entire series (figs. 188 and 189, *Cd.* 11) is a broad trough-like bone, somewhat resembling the pygostyle of many birds. The 45th and 46th differ from the seven preceding vertebræ in having distinct neurosteites (figs. 188 and 189, *n.ost.*) in the form of minute endosteal granules in the short neuroids.

The vertebral formula of the specimen described may therefore be written thus :—

$$Cv.\ 15 : Cv.Th.\ 1 : Th.\ \rlap{$\underbrace{}_{8}$}4 + 1 + \overbrace{3 : Lb.\ 4 : Lb.Sc.\ 4 : Sc.\ 3 : Cd.\ \rlap{$\underbrace{}_{11}$}3}^{S.Sc.} + 8 = 46,$$

i.e., there are fifteen cervical vertebræ, one cervico-thoracic, eight thoracic — of which the first five are free, and of these the first four have ribs articulating with the sternum — four lumbar, four lumbo-sacral, three sacral, and eleven caudal, of which the last eight are free. The bracket encloses all those vertebræ which are in contact with the ilia, and so form the syn-sacrum.

There are two caudal intercentra, each consisting of paired cartilages (*int.cent.*), the first lying between the eighth and ninth caudal vertebræ, the second extending from the posterior end of the ninth to the anterior end of the eleventh.

In a ripe but unhatched chick of *A. bulleri* referable to this stage, the last thoracic has not yet united with the first lumbar vertebra, but the only differences of importance are in the caudal region, which contains (fig. 190) only nine vertebræ, and a vestige of a tenth. The ninth (44th of the whole series) alone has an open arch, without neurosteites, and the tenth (*Cd.* 10) is a mere nodule of cartilage attached to the posterior face of the body of its predecessor. The specimen also serves to confirm the observation made above, that the neuroids of most of the caudal vertebræ are ossified by dorsal extensions of the centrosteite, or in other words, have each but a single centre of ossification.

b. Development of the Vertebral Column.

Stages A and *B* (Plate 4, figs. 31–33).

The secondary segmentation of the vertebral column has begun. The mesoblastic somites are still separated by narrow fissures (fig. 33, *f.*), the muscle plates (*M.Pl.*) are differentiated, and the mesoblast immediately surrounding the notochord is undergoing concentration to form the rudiments of the vertebral bodies (figs. 31–33, *Cent.*).

Stage C (Plate 5, figs. 43 and 44).

The patches of concentrated mesoblast from which the centra arise (fig. 44, *Cent.*) are considerably more obvious than in the preceding stage, and the cells composing them have become arranged in a concentric manner round the notochord (fig. 43, *Cent.*). They have not yet, however, passed into the condition of prochondral tissue.

Stage D (Plate 15, figs. 191–193).

The vertebræ are now well chondrified, and in all cases the neuro- and centro-chondrites have united so as to form complete cartilaginous vertebræ. The neural arches are, however, incomplete dorsad throughout the whole column, the neuroids not having yet united above the spinal cord. This is particularly well marked in the sacral (fig. 193) and caudal regions, in which the whole dorsal surface of the cord is covered only by membrane. In the sacral region, moreover, the right and left moieties of the centrum do not quite meet below the notochord (fig. 193), so that the body presents a narrow membranous interval in the middle ventral line.

The pleurochondrites of the cervical vertebræ or cartilaginous cervical ribs (fig. 191, *pl.chn.*) have evidently only recently chondrified, and form mere nodules united by membrane with the di- and par-apophyses. The thoracic ribs (fig. 192) are well chondrified, but there is no trace of sacral ribs (fig. 193), and in fact the whole of the post-thoracic vertebræ appear to be devoid both of lateral out growths and of pleuro-chondrites.

The vertebræ generally are very much higher in proportion to their breadth than in later stages, the centra being nearly circular in section and the transverse processes short (compare fig. 191 with fig. 181, and fig. 192 with fig. 184).

Stages E and *F* (Plate 15, figs. 194–197).

In both these stages the vertebral column was cut into sagittal sections; there is so little difference between them that they may be considered together.

The vertebral formula differs from that given on p. 78 in the presence of an additional caudal vertebra, the total number being 47. The cartilaginous centra are still annular, the notochord having undergone but little relative reduction; its diameter is on the average more than half that of a centrum.

The composition of the atlas and axis is remarkably well seen, and corresponds precisely with BAUR's account (4). The true body (centrochondrite) of the axis (fig. 194, *c.chn.*) is similar to that of the succeeding vertebræ, but is joined in front by a narrow fibrous interval to the odontoid or atlantal centrochondrite (*Od.*), which like the other vertebral bodies and the basioccipital (*Oc.Cn.*) is perforated by the notochord. Lying together ventrad of the notochord are two intercentra, one post-occipital (*pt.oc.int.c.*) which forms the so-called body or inferior arch of the atlas, the other post-atlantal (*pt.atl.int.c.*) which subsequently unites with the proper body of the axis behind and with the odontoid above. The neurochondrites of the atlas have already united with the post-occipital intercentrum but have not yet joined with one another above the spinal cord. In all the succeeding vertebræ the neural arches are completely formed.

The notochord as seen in a median longitudinal section of the cervical region (fig. 194, *Nch.*) has straight dorsal and ventral contours, but sections taken a short distance to the right or left of the median plane (fig. 195) show it to be distinctly beaded, being constricted in the middle of each centrum and dilated intervertebrally.

In the thoracico-lumbar region there are, in addition to the vertebral constrictions, slight constrictions of the notochord in the intervertebral regions, the rudiments of the menisci having grown inwards as narrow annular ridges. In the sacral (fig. 196) and anterior caudal regions both vertebral and intervertebral constrictions are well marked, there being two notochordal "beads" to each vertebral segment. In the posterior caudal region (fig. 197) the only constrictions on the dorsal surface are intervertebral, there being a distinct dilatation in each centrum; ventrally, however, there are vertebral ingrowths as well.

My Father (38) considers "these beadings as a true historical record of development," and as indicating a far greater number of vertebræ in the ancestors of Birds than in existing forms. I think, however, that a good deal of weight should be attached to the fact that the number of segments in *Apteryx* undergoes no alteration from a period corresponding to the fourth day of incubation in the Chick.

The last free and normal vertebra is the 45th (*Cd.* 11); the body of the 46th (*Cd.* 12) is fused ventrad of the notochord with that of the 47th (*Cd.* 13), but is free above the notochord. The body of the 47th is a long hollow cone of cartilage, projecting some distance caudad of its arch, so that the posterior end of the neural canal is freely open above.

The uncinates (Plate 16, fig. 217, *Unc.*) are quite separate from the corresponding ribs, and are not chondrified.

Stage G (Plate 15, figs. 198–203).

In one specimen belonging to this stage (*A. oweni*) the vertebral column was pre pared by dissection, and the vertebræ examined separately, in the other (*A. australis*) transverse sections were made.

The atlas (fig. 198), examined as an opaque object, appears to have an annular body, there being a complete foramen instead of a notch for the odontoid. Sections show, however, that the part lying dorsad of the odontoid foramen (*lg.*) is formed of indifferent tissue, and is the rudiment of the ligament (figs. 175 and 176, *lg.*) found in this position in later stages. The neural arch is still completed above by indifferent tissue.

In the axis (figs. 199 and 200) the three chondrites of the compound body have all concresced, the vertebra now consisting of solid cartilage. The pleurochondrites (*pl.chn.*) are very small, and their dorsal or tubercular ends have united with the neuroids, their ventral or capitular ends being still separated from the centrum by a narrow tract of indifferent tissue. The odontoid (*Od.*) is a short nipple-like process, on the apex of which is a minute dimple (*Nch.*), indicating the position of the greatly reduced notochord.

There is nothing of special importance about the remaining cervical, the thoracic (fig. 201), or the lumbar vertebræ, except that all those going to form the syn-sacrum are quite distinct, concrescence of the cartilaginous centra not having yet commenced. The sacral vertebræ (fig. 202) have diapophysis (*diap.*) and parapophysis, or rather pleuroids (*pleur.*), quite continuous respectively with neuroid and centrum, so that transverse sections of earlier stages would be required to show whether or not the sacral ribs originate as distinct chondrites.

There are twelve caudal vertebræ, the last of which, or 48th of the whole series (fig. 203), is short and nodular. Comparing the end of the tail in this and other stages, it would appear that, in the present case, an additional centrum is differentiated from the cartilaginous sheath of the caudal end of the notochord, the 47th and 48th vertebræ of the embryo now under discussion having the same general relations as the elongated 47th of Stage E (fig. 197), or of the trough-like 46th of the ripe embryo (fig. 189). It is quite obvious that the precise mode of segmentation of this region is a matter of individual variation.

In the last three vertebræ (fig. 203), the neuroids do not meet in the middle dorsal line, the neural arch being, therefore, widely open above. In the 45th, there is a fibrous union ; in all the rest the neural arch is completed above by cartilage.

As to their general form the vertebræ are about intermediate between the high or compressed condition of Stage D, and the broad or depressed condition of the advanced embryo or adult (compare figs. 192, 201, and 185).

Stage H.

One of the specimens belonging to this stage (*A. oweni*) presents a peculiarity in the vertebral formula, which is

$$\mathit{Cv.}\ 15 : \mathit{Cv.Th.}\ 1 : \mathit{Th.}\ \underbrace{4 + 1 + {}}_{7}\overbrace{2 : \mathit{Lb.}\ 4 : \mathit{Lb.Sc.}\ 3 : \mathit{Sc.}\ 3 : \mathit{Cd.}\ 3}^{\mathit{S.Sc.}}\underbrace{{} + 9}_{12} = 45\ ;$$

that is, there is one thoracic and one lumbo-sacral vertebra less than usual, while the number of free caudal vertebræ is nine. In the other specimen (*A. bulleri*) the numbers are normal.

The vertebræ have practically assumed their adult characters : ossification has begun and concrescence of the cartilaginous bodies of the lumbar, lumbo-sacral, and sacral vertebræ has taken place.

In the atlas the neurosteites only have appeared, the body (post-occipital intercentrum) being still unossified. In the axis there is a centrosteite in the body proper and another in the odontoid, but no ossification has yet appeared in the antero-ventral region of the body, or post-atlantal intercentrum.

The remaining cervical and the anterior thoracic vertebræ have small centrosteites and neurosteites : from the posterior thoracic to the sacral region only centrosteites have made their appearance, the arches being still unossified : the caudal region is wholly cartilaginous. The last caudal vertebra is conical and longitudinally grooved above, its neuroids being represented by mere low ridges which do not meet above the myelon.

The vertebral ribs are ossified, but their uncinates, as well as the cervical and sacral pleuroids, are still cartilaginous.

Stage I (Plate 15, fig. 204).

This stage only differs from its predecessor in the further extension of ossification.

Fig. 204 is introduced in order to show the relations of the vertebral column, vertebral and sternal ribs, uncinates, sternum, shoulder-girdle, and pelvis in an advanced embryo. It will be seen that in the specimen figured there is no uncinate on the cervico-thoracic rib (*Cv.Th.Rb.*).

c. *The Vertebral Column subsequent to Hatching.*

Stage L.

This stage differs from the newly hatched embryo (Stage K) only in the further advance of ossification, the cartilage being now nearly replaced by bone. The various osteites are, however, distinct. The last three caudal vertebræ have open arches, and the last is scoop-shaped.

Stage M.

The centrosteites and neurosteites of each vertebra have ankylosed, but the pleurosteites of the cervical vertebræ remain distinct, and there is no union of the separate (bony) vertebræ in the sacral region. The atlas still consists of three bones, its neurosteites not having yet united with the post-occipital intercentrum : and the odontoid and post-atlantal intercentrum have not yet ankylosed with the body of the axis.

The rib of the last thoracic vertebra is only 4 mm. long, and does not project beyond the ilium : if ankylosed to its vertebra the latter would certainly be counted as the first of the lumbar series. There are only three lumbar vertebræ, the lumbosacral are four, and the sacral three as usual, and there are twelve caudal, the last of which is a short blunt bone, its small neuroids meeting above.

Stage O (Plate 15, fig. 205).

Of this stage I have only the syn-sacra of two sub-adult specimens of *A. oweni.* In both the number of lumbar vertebræ is four, but there are only three lumbo-sacral. Most of the vertebræ have completely ankylosed, only the last thoracic (*Th.* 8), third sacral, and first caudal (*Cd.* 1) remaining partly free. Ossification has extended between the roots of the spinal nerves, so that each intervertebral foramen (*int.vert.for.*) is now replaced by two small apertures, one for the dorsal and one for the ventral root of the nerve.

Adult (Plate 15, figs. 206 and 207).

The number of cervical vertebræ appears to be quite constant, viz., fifteen: the 16th vertebra is also, in all specimens which have come under my notice, a cervico-thoracic, *i.e.*, bears free ribs which do not meet the sternum. In every instance but one these ribs are of considerable length—more than 30 mm.—and reach within a short distance of the sternum; but in a skeleton of *A. australis* in the Otago University Museum they are only 12 mm. long.

In every skeleton examined, except one, the number of thoracic vertebræ is eight, the first four of which are connected with the sternum by sternal ribs, while the last three are covered by the ilia and so form part of the syn-sacrum, only the last being ankylosed. The single exception is in the skeleton of *A. australis* referred to in the preceding paragraph, in which the 25th vertebra—corresponding to the first lumbar in other cases—bears on the left side a short rib about 11·5 mm. long, and must, therefore, be counted as a ninth thoracic.

The usual number both of lumbar and lumbo-sacral vertebræ is four, but in some instances there are four lumbar and three lumbo-sacral, in others three lumbar and four lumbo-sacral. The sacral vertebræ proper appear to be invariably three, and there is the same number of caudal vertebræ included in the syn-sacrum (sacro-caudal, MIVART). The single exception to this is in the case of a skeleton of *A. oweni* in the Museum, in which there are four vertebræ behind the third sacral within the limits of the syn-sacrum: the first of these bears diapophyses as distinct as the ankylosed ribs of the third sacral, and may therefore be a true (fourth) sacral vertebra; the fourth is only partly covered by the ilia.

The number of vertebræ caudad of the syn-sacrum is also fairly constant: in every skeleton examined, except one, there are six free vertebræ, followed by a pygostyle, which is obviously formed by the union of either two or three (figs. 206 and 207, *Pyg.*) The pygostyle is a conical bone, and, in every case examined, its neural canal was completely closed in above (fig. 207), this process evidently taking place after hatching. In the skeleton of *A. oweni* referred to in the previous paragraph there are seven free caudal vertebræ, the last of the series being apparently single, so that in this case there is no pygostyle.

The total number of vertebræ and their distribution among the various regions may be expressed by a formula as follows :—

$$Cv.15 : Cv.Th.1 : Th.\,\underbrace{4+1+\mathrlap{\overbrace{\phantom{3(4\text{ or }2) : Lb.4(3) : Lb.Sc.4(3) : Sc.3 : Cd\ 3(4)}}^{S.Sc.}}3(4\text{ or }2)}_{8\,(9\text{ or }7)} : Lb.4(3) : Lb.Sc.4(3) : Sc.3 : Cd\ \underbrace{3(4)+6+\overbrace{3(2\text{ or }1)}^{Pyg.}}_{12\,(13\text{ or }11)}$$

$$= 47\ (46\text{ or }45);$$

that is, there are fifteen true cervical vertebræ without free ribs; one cervico-thoracic bearing free ribs which do not meet the sternum; usually eight, but occasionally nine or seven thoracic, of which the first five are not covered by the ilia, and the first four bear ribs meeting the sternum; four or sometimes three lumbar with distinct parapophyses; four or occasionally three lumbo-sacral without parapophyses; three sacral with autogenous parapophyses or pleurosteites; three or rarely four caudal covered by the ilia; and from seven to nine free caudal, of which the last three or two are usually ankylosed to form a pygostyle. The ilia are supported by about fourteen vertebræ, from the sixth thoracic to the third (rarely fourth) caudal, which therefore constitute the syn-sacrum. The total number of vertebræ is usually forty-seven, but may be forty-six or occasionally forty-five. There appear to be no constant differences between the species in the vertebral formula.

I have found caudal intercentra in one skeleton only (*A. australis*): they have the form of irregular nodules of bone (fig. 206, *int.cent.*), one between the pygostyle and the preceding (ninth) caudal vertebra, the other between the eighth and ninth.

The general rule appears to be, as MIVART states, that uncinates are present on the cervico-thoracic and on the first six thoracic ribs, but the short cervico-thoracic ribs of the skeleton of *A. australis* referred to above (p. 83) are devoid of those appendages, which are also absent on one side in another skeleton examined. OWEN also states that they are absent in the specimen first examined by him. The occasional absence of the cervico-thoracic uncinates, taken in connection with the vestigial condition of the ribs in one case, and with the fact that in the same skeleton the first thoracic rib of the right side terminates ventrad in a blunt free end and has no sternal portion, seems to point to an inclusion of anterior thoracic vertebræ in the cervical region by atrophy of their ribs.

3. THE STERNUM.

a. In the Adult.

(Plate 16, figs. 208–215.)

The descriptions of the sternum by OWEN (24, p. 34) and by my Father (43, p. 191)—the only two detailed accounts I have met with—give all the essential features of the bone, and at the same time serve to show its great variability. In OWEN's specimen (*A. australis*) the posterior lateral processes are slightly longer than the posterior median process, the anterior margin is deeply and evenly excavated, and there are two large perforations, one on each side of the middle line. In my Father's specimen, also stated to be *A. australis*, the posterior median is considerably longer than the posterior lateral processes, the anterior margin is sinuous and is produced in the middle line into a small projection, and there are no perforations.

Miss LINDSAY (19) gives outline figures of the sterna of *A. bulleri* (=*mantelli*) and *A. oweni**; both show an even anterior emargination—deepest in *A. bulleri*, no

---

* These are erroneously stated to be one and a-half natural size: they are really less than two-thirds.

fenestræ, and the posterior lateral rather longer than the posterior median process, which latter is bifid in *A. oweni.*

As far as I have been able to ascertain, no previous observer has called attention to any characters in the bone of specific importance. From the small series of skeletons which have come under my notice, certain points appear to be fairly constant. As one of these depends upon the relative length and breath of the bone, it is necessary to define these terms.

Both posterior median and posterior lateral processes are tipped, in the fresh state, with cartilage (Plate 16, fig. 213), which is usually absent in the dried skeleton, so that the greatest length of the sternum, measured from the apex of the anterior lateral to the extremity of the posterior lateral process, is a variable quantity, depending upon the extent to which ossification has advanced. The same objection applies to taking the length from the middle of the anterior border to the posterior median process, since the latter varies in length with age.

A more constant dimension is, however, furnished by the length of the corpus sterni as measured from the centre of its anterior border to a point midway between the two posterior notches (*ab* in figs. 208, 212, and 214). This I call *length of corpus sterni*; by *breadth of corpus sterni* I understand the length of a straight line drawn transversely across the sternum at about the level of the facets for the second pair of sternal ribs (*cd* in the same figures).

In *A. australis* the length of the corpus sterni appears to be constantly more than half its breadth, and the anterior border is concave with an even curve (figs. 208 and 209).

In *A. bulleri* the length of the corpus sterni is—often considerably—less than half its breadth. The anterior border is more deeply emarginated than in *A. australis,* and presents an even curve. The anterior lateral processes are usually blunter than in *A. australis* (figs. 212 and 213).

In *A. oweni,* besides the smaller size of the entire bone, the length of the body is less than half its breadth. The emargination of the anterior border is about the same as in *A. australis,* but instead of being even it is slightly sinuous, each side presenting a sigmoid curvature (figs. 214 and 215).

In the supposed skeleton of *A. haastii* (p. 38) the length of the corpus sterni is much greater than its breadth, and the characters generally agree with those of *A. australis* (fig. 210).

As far as my own observations go, these characters are constant, but my Father's figure of the sternum of *A. australis* (43, Plate 17, fig. 1) shows an uneven anterior curvature with a slight median projection, and the length, as defined, is less than half the breadth, while in Miss LINDSAY's figure of *A. oweni* (19, p. 712, fig. 5, 5) there is no trace of the sinuosity of the anterior border, and the length is a little more than half the breadth.*

---

* I am disposed to think that skeletons of *Apteryx* often bear wrong specific names. There ought

Trifling as these characters are, and inconstant as they may probably prove to be I think them worth giving as showing that the three or four species of *Apteryx* are tending to differentiation in their skeletons as well as in their external characters.

One point not yet referred to appears to be of considerable interest. As a general rule the costal borders of the bone are thick and strong, the thickening extending to a greater or less extent on to the anterior border, but the rest of the bone being thin and translucent. But in two specimens of *A. bulleri* (fig. 213), in the doubtful *A. haastii* (fig. 210), and in the skeleton in the Wellington Museum marked *A. maxima*, but probably referable to *A. bulleri* (fig. 211), the corpus sterni presents a distinct median longitudinal thickening (*k.*) along its anterior half, the result being the production of a low ridge nearly as well marked as the vestigial keel of *Stringops*. In a skeleton of *A. australis* in the Canterbury Museum (fig. 209), there is a very poorly developed ridge, which projects on the inner or dorsal surface of the bone instead of on the ventral or outer surface, as in all other cases.

On the hypothesis that the Ratitæ are descended from birds which possessed the power of flight, the occasional occurrence by reversion of a vestigial keel is precisely what might be expected. The absence of a special osteite (lophosteon) for the keel hardly appears to be of such fundamental importance as it is sometimes assumed to be. I should rather take the presence or absence of such a bone as a fact of the same rank as the presence or absence of a distinct centre of ossification in the spines of the thoracic vertebræ of mammals. But this is a point upon which the development of the sternum in *Stringops* should throw light.

In one skeleton of *A. australis* there is an exception to the usual rule that four sternal ribs are articulated to the sternum; on the left side the fifth thoracic rib is attached by a true joint, the articular cavity being on the proximal end of the posterior lateral process.

b. Development of the Sternum.

Stage E (Plate 16, fig. 216).

In this the earliest stage in which the sternum was observed, owing to the damaged condition of Stage D, it consists of paired cartilaginous plates, there being no indication of the metasternum or posterior median portion.

Owing to the way in which the ventral body-wall was ruptured (Plate 3, fig. 6) the moieties of the sternum had a position nearly parallel to the median plane of the body, and are, therefore, well seen in sagittal sections. Each (fig. 216, *St.*) is roughly triangular, with a thickened anterior margin, to which the coracoid (*Cor.*) is articulated, and an extremely thin mesio-ventral border. The anterior edge is sinuous.

---

never, of course, to be any mistake about *A. oweni*, but the other two common species are very easily mistaken for one another.

The position of the sternum is remarkable; its antero-posterior axis is as nearly as possible parallel with that of the vertebral column, as in a Carinate Bird, instead of being nearly at right angles to it, as in the adult and advanced embryo (*cf.* figs. 204 and 216).

There are only three ribs attached to the costal border, and the third of these (*Th.Rb.* 3) appears to be united by indifferent tissue. The cervico-thoracic rib (*Cv.Th.Rb.*) is separated by a wide interval from the sternum. There is thus a striking difference from many of the embryos investigated by Miss LINDSAY (19), in which the number of ribs attached to the sternum is greater in the embryo than in the adult. The joints between the vertebral and sternal ribs, and between the first two sternal ribs and the sternum, have already appeared. They are not shown in Miss LINDSAY's figures of even considerably later stages, but this is probably due to that observer not having corrected the results of her dissections by the subsequent examination of thin sections.

Stage F (Plate 16, fig. 217).

The two halves are still separated by a considerable interval, and there is no indication of the metasternal region. The coracoid grooves are very obvious in sections, and the sternum has extended caudad slightly beyond the ventral end of the fourth thoracic rib (*Th.Rb.* 4). From a dissection of the specimen, it appeared that this rib was attached to the sternum, but sections show that it is really separated by a short but perfectly distinct interval.

Comparing this stage with the last, it appears certain that in *Apteryx* each half of the sternum is not formed by the antero-posterior union of the whole of the sternal ribs. In Stage E only two ribs are united by joints, and a third is loosely attached by indifferent tissue at the posterior boundary of the sternum. In Stage F the sternum has apparently grown backwards to the level of the fourth thoracic rib, which has extended mesiad to meet it.

As to position, the posterior end of the sternum is now at a considerably lower level than its anterior end, so that the angle between the sternal axis and the vertebral column approaches a right angle.

Stage G (Plate 16, figs. 218 and 219).

The two halves of the sternum have now concresced in the middle line from about the level of the first sternal rib to that of the fourth. The posterior lateral processes (*post.lat.pr.*) have nearly attained their full length, but there is no trace of the posterior median process.

A transverse section (fig. 219) shows the corpus sterni to be slightly concave ventrad and somewhat thickened in the middle line, but devoid of any trace of a keel.

Stages H and I (Plate 15, fig. 204, and Plate 16, figs. 220 and 221).

The two halves of the sternum are united, and the adult form is attained by the development of a well-marked posterior median process. There is the normal number (four) of sternal ribs articulated to the costal border, except in the specimen of *A. oweni* belonging to Stage H (fig. 221), in which the fourth rib of the right side (*Th.Rb.* 4) does not reach the sternum. On the other hand, in one specimen of Stage I (fig. 204) the end of the fifth thoracic rib approaches within half a millimetre of the sternum (*cf.* p. 86).

Stage K (Plate 16, fig. 222).

In one of the specimens belonging to this stage—a ripe embryo of *A. bulleri*—the sternum is still unossified, but in both the others—a ripe embryo and a newly-hatched chick of *A. australis*—the osteites of the costal sternum (pleurostea) have appeared (*Pl.ost.*). In one of these specimens the posterior median process is double, in the other it is perforated by an oval foramen (fig. 222, *fo.*). This would seem to indicate a paired origin of the metasternum.

In neither of the specimens of *A. australis* are the adult proportions attained, the length of the corpus sterni being slightly less than half its breadth, as in *A. bulleri*. As will be seen by a comparison of figs. 222 and 208, of 220 and 212, and of 221 and 214, the proportional length increases considerably between late embryonic and adult life.

Stage L (Plate 16, fig. 223).

The single specimen belonging to this stage has the pleurostea (*Pl.ost.*) increased in extent, and is remarkable for the presence of three thin places (indicated by shading) in the body, one median and two paired, and evidently indicating recent extensions of cartilage. It looks very much as if the increase in proportional length were due to a filling up of the posterior notches. The posterior median process is perforated by a small foramen (*fo.*). The adult proportions are attained, the length of the corpus sterni being now considerably more than half its width.

Stage M (Plate 16, fig. 224).

The pleurostea (*Pl.ost.*) have nearly met in the middle line, and have extended into the anterior lateral processes (*ant.lat.pr.*), so that only the three posterior processes are unossified. The anterior border shows no trace of the sinuous curve found in the adult of this species (*A. oweni*).

In all later stages ossification is complete.

4. The Shoulder-Girdle.

a. In the Adult.

(Plate 16, figs. 225–232.)

The shoulder-girdle, like the sternum, is subject to great individual variation, and for purposes of comparison I have found it necessary to sketch it from the same points of view in all the adult specimens figured. In the front views (A in figs. 225–232) the bone was placed with the distal end of the scapula and the whole sternal (epicoracoid) border of the coracoid resting on the table, and its outline traced on a sheet of glass placed immediately above it and parallel to the table. In the lateral or external views (B in the same figures) it was placed so that the glenoid fossa exactly faced the observer. The outline was taken on glass as before. In this way the relative dimensions of the various parts are shown from a fixed point of view. Both scapula and coracoid are considerably foreshortened in the front views owing to the curvature of the entire bone, but their correct length is given in the side views.

As a general rule, the scapula (*Scap.*) is about one and a-half times the length of the coracoid (*Cor.*), but in one specimen of *A. australis* (fig. 227), it is hardly more than one and a-quarter times as long, and in a specimen of *A. oweni* (fig. 231), it is more than twice as long. The curve of the scapula also varies considerably.

But it is in the coracoid that the most interesting variations occur. As a rule (figs. 230–232, A), it is a flattened bone with a nearly straight mesial and concave lateral border, but the mesial border is often (figs. 227 and 228, A) somewhat excavated, and in three instances (figs. 225, 226, and 229, A) the excavation takes the form of a regular semicircular notch which is converted into a foramen (*cor.fen.*) by a ligament (*pr.cor.lig.*). The mere observation of the parts in the adult is enough to show what is clearly proved by their development (*infra*, pp. 91 and 92), that the ligament is the degraded procoracoid, and that the foramen or notch is the coracoid fenestra which is so characteristic a feature in the shoulder-girdle of the Ostrich. In cases where there is no such fenestra, the bone in the corresponding position is always thin and transparent (indicated by shading in figs. 227, 230, 231, and 232, A), the space being evidently filled up by the extension mesiad of the coracoid with the fibrous tissue stretched across it.

The small aperture, marked *Sup.cor.for.* (fig. 227, &c., A), and considered by both Owen (24, p. 34), and my Father (43, Plate 17, fig. 1), as the coracoid fenestra, is evidently homologous with the supra-coracoid foramen at the base of the procoracoid process in many Birds, and particularly well-marked in *Diomedea, Ocydromus*, &c.

In the Carinatæ, the furcula is attached by ligament to three processes of the shoulder-girdle—the acromion (mesoscapula, W. K. Parker) on the inner or preaxial border of the proximal end of the scapula, the procoracoid process (mesocoracoid process, W. K. Parker) on the mesial or preaxial border of the coracoid at its dorsal end, and the acrocoracoid of FÜRBRINGER (clavicular process, HUXLEY; head of the coracoid, proximal precoracoid, W. K. PARKER) a large process from the anterior surface of the dorsal end of the coracoid towards its post-axial border. Thus, the foramen triosseum is bounded mesiad by the furcula, laterad by the acrocoracoid, and caudad by the acromion and procoracoid process; and the acrocoracoid is situated immediately mesiad of the tendon of the subclavius as it passes through the foramen triosseum to reach the dorsal aspect of the humerus.

In *Apteryx*, a fair proportion of the specimens examined have more or less well-marked tuberosities in the precise position of all the three processes referred to. At the ventral end of the scapula, close to its preaxial border, and immediately above the position of the obliterated coraco-scapular synchondrosis is an acromial tuberosity (*acr.*) very obvious in figs. 226, 228, and 230; at the dorsal end of the coracoid close to its preaxial border a less obvious, but undoubted procoracoid tuberosity (*pr.cor.t.*) is shown in fig. 230; and in every specimen the acrocoracoid tuberosity or spina coracoidea (*acr.cor.*) is a prominent feature. Moreover, the tendon of the subclavius (Plate 19, fig. 293, *subcl.*) passes immediately mesiad of the last-named elevation, precisely as in Carinatæ.

The coraco-scapular angle varies from 150° to 122°. It is largest (150°) in the skeleton in the Wellington Museum marked *A. maxima* (probably *A. bulleri*, fig. 225); it is 142° in one specimen of *A. australis* (fig. 227) and in the supposed *A. haastii* (fig. 226); between 127° and 130° in another specimen of *A. australis* (fig. 228), in one of *A. bulleri* (fig. 229), and in one of *A. oweni* (fig. 231); and 122° in two specimens of *A. bulleri* (fig. 230) and one of *A. oweni* (fig. 232). There is, therefore, no constancy in this respect in the various species. The fact that the angle is as small as 122° in *Apteryx*, while it rises to 97° in *Notornis* and to 100° in *Ocydromus* and *Diomedea* (26, p. 250) quite bears out FÜRBRINGER's statement that as a character distinguishing the Ratitæ from the Carinatæ, it is of considerably less importance than the relative size in the two groups of the acrocoracoid. FÜRBRINGER gives the range of variation in the coraco-scapular angle as 130° to 160° for Ratitæ, and 45° to 106° for Carinatæ, giving a difference of 24° between the two groups; the foregoing observations reduce the difference to 16°.

b. Development of the Shoulder-Girdle.

Stage E (Plate 16, fig. 216, and Plate 17, fig. 233).

The absence of any stage of the shoulder-girdle earlier than this is much to be regretted, as I have been unable to ascertain whether there are originally formed separate chondrites for the coracoid, procoracoid, and scapula, as described by Miss LINDSAY (19). In the present stage the scapulo-coracoid consists of a solid bar of cartilage of much the same shape as the adult bone, but without any fenestræ or other signs to indicate the separation of coracoid and procoracoid. In fig. 233, taken from the cartilage after removal from the body, the scapula appears to be nearly in the same straight line as the coracoid, but in fig. 216, accurately reconstructed from sagittal sections, it is seen to be strongly curved, so that while the coraco-scapular angle, as usually taken, *i.e.*, considering the ventral end of the scapula only, is about 135°, it is only about 83° if the general direction of the scapula is taken by a line joining its base and apex. Fig. 216 certainly suggests the straightening of the shoulder-girdle by its release from the backward pull of the shoulder muscles.

Another striking fact is that the long axis of the coracoid (fig. 216, *Cor.*) is inclined from its sternal articulation forwards, so as to make an acute angle with the vertebral column, instead of a right angle as in later stages (*cf.* fig. 204, *Cor.*). In other words, the *coraco-vertebral angle* is about 35°, instead of 90°, and thus furnishes an important point of agreement with the Carinatæ.

Stages F and G (Plate 17, figs. 234–236).

In these stages the shoulder-girdle has undergone very little advance except in size and in the increased development of the acrocoracoid tuberosity (*acr.cor.*), which is now a well-marked process considerably larger proportionally than in the adult. Its dimensions are well seen in fig. 236, which shows two obliquely transverse sections through the junction of the scapula and coracoid in Stage G. Both pass through the acrocoracoid (*acr.cor.*), and B, which is three sections caudad of A, also passes through the supracoracoid foramen (*sup.cor.for.*).

The coraco-vertebral angle is still acute, as shown by the fact that obliquely transverse sections of it were obtained by cutting an embryo (*A. australis*, Stage G) at right angles to the long axis of the trunk, but the inclination is considerably less than in the preceding stage, amounting to about 60° in Stage F.

Stage H (Plate 17, figs. 237 and 238).

The two specimens belonging to this stage show a very important step in the development of the shoulder-girdle. In the younger of the two (*A. oweni*, fig. 237) the scapula (*scap.*) is ossified, but the coracoid has undergone no alteration, being still a solid cartilage with a very prominent acrocoracoid tuberosity.

In the other embryo (*A. bulleri*, fig. 238) the scapula is similarly ossified, but the coracoid has undergone a great change, a portion of the cartilage having been absorbed so as to produce a large coracoid fenestra (*cor.fen.*) separating a narrow preaxial (mesial) procoracoid bar (*Pr.Cor.*) from a broad postaxial (lateral) portion, the coracoid proper (*Cor.*), in which an ossification has appeared.

In *Apteryx*, therefore, the coracoid and procoracoid clearly result from a process of fenestration in an originally single cartilage. Whether this fenestration is a secondary process and the two elements arise in the first instance as distinct chondrites, my material has not allowed me to determine; but Miss LINDSAY'S researches (19, p. 692) show that such a mode of origin is probable. The resemblance of the shoulder-girdle shown in fig. 238 to that of the Ostrich is very striking.

Stages I and K (Plate 17, figs. 239 and 240).

These stages are also interesting since they show the gradual degradation of the cartilaginous procoracoid.

In Stage I (fig. 239) the procoracoid (*Pr.Cor.*) is a narrow cartilaginous bar continuous above with the coracoid, but free below, and connected by ligament with the epicoracoid region. In Stage K (fig. 240) the process has gone still further, and the procoracoid is almost entirely converted into ligament (*pr.cor.lig.*), only a small pointed process being left to indicate its dorsal end.

Stage L precisely resembles K, and in M the adult characters are assumed.

5. The Fore-Limb.

a. In the Adult.

(Plate 17, figs. 241–253.)

With regard to the humerus, radius, and ulna, I have nothing to add to Owen's description, but his account of the manus is imperfect and somewhat obscure. He say " there is a minute carpal bone, two metacarpals, and a single phalanx," but the plate shows the manus to consist of three bones in a single longitudinal series. The middle and distal of these would naturally be considered as phalanges, so that there is only the proximal one to represent the carpal and the two metacarpals. The figure is on such a small scale that it is impossible to place much reliance upon it, but it has all the appearance of representing a normal wing of *A. australis,* while the description, at least as regards the separate carpal, applies rather to *A. oweni* (*vide infra*).

My Father (41, Plate 65, fig. 5) figures a manus which he calls *A. oweni,* but which is, in all probability, *A. australis.* In an earlier paper (42, p. 127) he figures a specimen in which a small radial carpal is shown, but is not referred to; the species in this case is not mentioned.

As far as my own observations go, the essential structure of the manus is quite constant in *A. australis* and in *A. oweni,* judging from four adult specimens of each; while in *A. bulleri* the variations are so great that the examination of five specimens is quite insufficient to determine their range. Besides these, I have examined the wing of one of the type specimens of *A. haastii* in the Canterbury Museum, as well as that of the supposed *A. haastii* from Puysegur Point (p. 38), and of the skeleton called *A. maxima* (= *A. bulleri ?*) in the Wellington Museum.

In *A. australis* (fig. 241) the bones of the forearm (*Ra., Ul.*) are succeeded by a somewhat irregular flattened bone, the carpo-metacarpus (*Cp.Mtcp.*). It presents on the preaxial side of its proximal border a small facet for the radius, and a larger and very oblique surface for the ulna. Distad it narrows considerably, and gives attachment to the proximal phalanx. Postaxiad, it is usually produced into a tolerably well-marked projection, which represents the third metacarpal; a similar, but smaller projection, sometimes springing from the preaxial border, may represent the first metacarpal, but is possibly a mere process of the second. The development of this bone shows that it is composed of both proximal and distal carpals, and of the second and third, and possibly also the first, metacarpals.

There are sometimes two and sometimes three phalanges to the single (second) digit (*Phal.* 2′, *Phal.* 2″, *Phal.* 2‴); in the latter case the second or middle phalanx (*Phal.* 2″) is always small, and, as will be seen, it appears later than the others. It is evidently obsolescent.

The presence of three phalanges to the index is a generalised character, the normal number in birds being two, but as, according to WIEDERSHEIM (52, p. 218), three families of Carinatæ possess the maximum number, no great stress need be laid upon the occasional presence of the second in *Apteryx*, except as showing which of the three has usually atrophied.

In *A. oweni* there seems to be invariably a distinct radiale (figs. 242–244, *ra.*) in the form of a small rounded nodule of bone intercalated between the radius and the carpo-metacarpus. In two of the specimens examined, the third metacarpal (fig. 242, *Mtcp.* 3) is ankylosed along its whole length to the second (*Mtcp.* 2) as in *A. australis*, but in the third it is free distad (fig. 243), and in the fourth—a sub-adult specimen—united only by membrane (fig. 244). The phalanges of the second digit may be three or two.

In *A. haastii* the single wing examined (fig. 250) has two free carpals, a radiale (*ra.*) and an ulnare (*ul.*), and all three phalanges are present.

In the skeleton, doubtfully referred to *A. haastii*, a radiale is present in the left manus (fig. 251) but absent in the right (fig. 252); there are also three phalanges on the left, and two on the right side.

In *A. bulleri* the variations in the structure of the carpo-metacarpal region are very striking. In two instances (fig. 246) there is a single carpo-metacarpus exactly resembling that of *A. australis*. In a third (fig. 245) the resemblance is equally close to *A. oweni*, there being a carpo-metacarpus and a radiale. In the fourth (fig. 247) the radius and ulna on the left side articulate with a transversely elongated bone (*ra.dist.*) which apparently represents both the radiale and the distal carpals, and to the distal surface of which free second and third metacarpals are attached. It is worth noticing that this is probably the only recorded example of a fully adult recent bird with free metacarpals. On the right side of the same skeleton (fig. 248) the second metacarpal appears to have ankylosed with the carpals, forming an irregular rod-shaped carpo-metacarpus, while the third metacarpal is free. In the fifth and last specimen—removed like several others from a skin—there is (fig. 249) a nodular radiale, a sigmoid bone which apparently represents the distal carpals and the second metacarpal, and a short free third metacarpal. As far as I can make out there is no doubt about the species in any of the five cases.

The Wellington specimen, marked *A. maxima,* agrees with the left side of the fourth example of *A. bulleri* mentioned above (fig. 247). There is a single transversely elongated carpal (fig. 253), not yet ossified postaxiad, a large second metacarpal, or possibly carpo-metacarpal, and a small third metacarpal. Thus the characters both of the sternum and of the manus seem to show that this specimen is referable to *A. bulleri.*

It is worth mentioning that while the manus is usually permanently flexed postaxiad on the forearm at an angle of about 140° (figs. 241, 245, &c.), the two are sometimes nearly or quite in the same straight line (figs. 243 and 250).

b. Development of the Fore-Limb.

Stage E. (Plate 17, figs. 254 and 255.)

The external characters of the limb at this stage have been described (p. 32). The humerus (*Hu.*), radius (*Ra*), and ulna (*Ul.*) are well chondrified. The carpus is represented by a thickened plate of mesoblast, which in its external (dorsal) region (fig. 255) shows no division into separate carpals, but towards the middle of its thickness (fig. 254) presents four fairly well-marked patches of prochondral tissue, the rudiments of the carpals. Of these, one (*ra.*) is immediately distad of the radius, and is evidently the radiale; the other three lie proximad of the three metacarpals, and may be considered as the first (*dist.* 1), second (*dist.* 2), and third (*dist.* 3) distalia.

The three preaxial digits are quite distinct. The pollex consists only of a chondrified metacarpal (*Mtcp.* 1); the index of a metacarpal (*Mtcp.* 2) and proximal phalanx (*Phal.* 2′) of cartilage, and of a distal phalanx (*Phal.* 2‴) of prochondral tissue; the third of a chondrified metacarpal (*Mtcp.* 3) and a single phalanx of prochondral tissue.

Stage F (Plate 17, fig. 256).

There is still no trace of chondrification in the carpal mesoblast, and only two patches of prochondral tissue are distinguishable, one (*ra.*) between the radius and the first metacarpal, the other (*dist.* 2) immediately proximad of the second metacarpal. I take the first of these to be the radiale, the other the second distale.

The first (*Mtcp.* 1) and third (*Mtcp.* 3) metacarpals have not increased in size since the previous stage, but the second (*Mtcp.* 2) is half as long again. The distal phalanx of the second digit is still unchondrified, and there is no trace of a second phalanx, present in the embryo Goose, according to BAUR, in the third digit.

Stage G (Plate 17, figs. 257–260).

The carpals have begun to chondrify, but are still very indistinct, the several chondrites fading insensibly into the common carpal mesoblast. In the specimen of *A. australis* belonging to this stage, a section taken near the dorsal (outer) aspect of the carpus (fig. 258) shows a distinct radiale (*ra.*) interposed between the end of the radius (*Ra.*) and a large distale (*dist.*). Further ventrad (fig. 259) the radiale is no longer seen, the radius is almost in contact with the distale, and a small chondrite (*ul.*), probably an ulnare, is seen postaxiad of the third metacarpal (*Mtcp.* 3). Fig. 257 shows my interpretation of these sections.

The first metacarpal (figs. 257 and 259, *Mtcp.* 1) is represented only by a small rounded patch of cells, and seems therefore to have undergone complete histological degeneration. The second digit has two chondrified phalanges, and its metacarpal (*Mtcp.* 2) has partly united with the distale. The third consists only of a small metacarpal (*Mtcp.* 3).

In the specimen of *A. oweni* belonging to this stage (fig. 260) the skeleton of the wing was dissected out and afterwards cut into serial sections in order to settle some doubtful points. It is quite possible that the carpus may have been injured in dissection. There is a large chondrite (*cp.*) imperfectly chondrified distad, and giving attachment on the one hand to the radius and ulna, and on the other to the first and second metacarpals. It apparently represents the first and second distalia ; whether it includes also the radiale or whether the latter was lost in preparation is uncertain. Immediately postaxiad of it is an unchondrified but distinct patch of mesoblast (*dist.* 3), with which the third metacarpal is connected. It is probably the third distale. Postaxiad of this again, and passing obliquely proximad towards the ulna is a rod-shaped chondrite (*ul.*) which appears to be an ulnare.

The first metacarpal (*Mtcp.* 1) is well developed in this specimen, and ossification has begun in the shafts of the humerus, radius (*Ra.*), and ulna (*Ul.*).

Stage H (Plate 17, figs. 261 and 262).

The humerus, radius, and ulna have their shafts ossified, but the manus is still entirely cartilaginous, and its structure differs considerably in the two specimens belonging to the stage.

In *A. oweni* (fig. 261) there is a large radiale (*ra.*), and the distalia have united into a single transversely-elongated cartilage (*dist.*) which articulates proximad with the radiale and the ulna, and distad with the second and third metacarpals. It is obvious that by subsequent concrescence of this cartilage with the metacarpals the carpo-metacarpus of the adult is formed.

The third metacarpal (*Mtcp.* 3) is about the same length as the second (*Mtcp.* 2), and its distal end is turned slightly postaxiad. Both metacarpals are in process of fusion with the distale. There is no trace of a first metacarpal. The second digit bears two phalanges, of which the distal one is very small.

There are synovial capsules between the radius and radiale, the ulna and distale, and the radiale and distale, as well as between the metacarpal and proximal phalanx of the second digit.

In *A. bulleri* (fig. 262) there is a large cartilaginous preaxial carpal (*ra.dist.*) articulating proximad with both radius and ulna, and distad with both second and third metacarpals. The ulna and the second metacarpal project postaxiad of it, and between them is intercalated a small nodular cartilage (*ul.*). Comparison with other stages leads me to consider the large preaxial carpal (*ra.dist.*) as a radio-distale, the small nodule (*ul.*) as an ulnare.

The third metacarpal is—quite exceptionally—longer than the second and of equal diameter. The second digit bears two phalanges, the distal of which has taken on the usual characters of an ungual phalanx.

Stage I (Plate 17, figs. 263 and 264).

The two specimens, like those of the previous stage, show very considerable differences.

In *A australis* (fig. 264) there is a large radiale (*ra.*) and a small trigonal ulnare (*ul.*). Articulating with these, and partly also with the ulna, is a large flat distale (*dist.* 2), the postaxial end of which (*dist.* 3) is shown by sections to be a separate chondrite, its plane of junction with the larger cartilage being marked by a layer of small close-set cells. The second metacarpal is in contact mainly with the larger cartilage, the third with the smaller; they may, therefore, be safely considered as the second and third distalia.

The second and third metacarpals have undergone almost complete concrescence with the distalia, the junction between them being marked only by a layer of close-set cells. The second metacarpal (*Mtcp.* 2) is slightly longer and considerably wider than the third, and its shaft is ossified; the third (*Mtcp.* 3) is slender, pointed distad, and separated by a space from the second, except at its proximal end where concrescence has begun.

The second digit bears three phalanges, of which the first (*Phal.* 2′) has begun to ossify in the middle of its shaft, and the third (*Phal.* 2‴) at its distal end; the second (*Phal.* 2″) is considerably smaller than the others, and is unossified.

As in the previous stage, there is a distinct synovial capsule between the radiale and the distale, as well as between the radius and ulna respectively, and the carpus.

The specimen of *A. bulleri* belonging to this stage (fig. 263) presents certain peculiarities. The carpus consists of a distinct radiale (*ra.*) and of a large distale (*dist.*) nearly fused with the second metacarpal. The third metacarpal is free, and slightly smaller than the second.

The preaxial border of the second metacarpal is produced into a blunt process (*Mtcp.* 1), which is shown by sections to be a distinct chondrite; it can hardly be anything else than the first metacarpal which has thus, in this instance, fused with the second, instead of degenerating.

There are only two phalanges to the second digit, the second being absent. The third (*Phal.* 2‴) has its tip ossified, and gives off from its proximal end a rod-like recurrent process (*Phal.* 3), which appears to be a distinct chondrite; it is probably the distal phalanx of the third digit, which has not, as usual, atrophied at an early stage.

Stage K (Plate 18, figs. 265–268).

In this case also there is a striking difference between the two specimens examined.

In *A. australis* (figs. 265 and 266) the carpo-metacarpus is almost exactly intermediate between the condition found in the previous stage and in the adult. The radiale (fig. 266, *ra.*) and ulnare (*ul.*) have begun to concresce with the distalia (*dist.*), the synovial space existing between them in Stages H and I being nearly filled up by small cells, which shade into the cartilage on either side. Towards the ventral (palmar) aspect of the carpus the radiale and ulnare have united. The distalia (*dist.*) have completely fused with the metacarpals. The diaphysis of the second metacarpal has extended so that the shaft of the bone is now well ossified, and the third metacarpal (*Mtcp.* 3) has united with it, forming a narrow cartilaginous ridge postaxiad of the bone.

In the left manus there is a small cartilaginous projection (fig. 265, *Mtcp.* 1) on the preaxial side of the carpo-metacarpus, probably representing the first metacarpal.

In *A. bulleri* (figs. 267 and 268) the condition of the parts approaches most nearly to what was found in the same species in Stage H (fig. 262). There is a large radio-distale (*ra.dist.*) separated by a very thin layer of fibrous tissue from the second metacarpal, with which it is beginning to unite. There is no ulnare, but its place is occupied by a well-defined patch of fibrous tissue. The second and third metacarpals are separate, and each has a distinct diaphysial ossification.

Stage L (Plate 18, figs. 269–271).

In a specimen of *A. australis* a few weeks old the radiale and ulnare (fig. 270, *ra.*, *ul.*) have united with one another, and their concrescence with the distalia (*dist.*) is nearly complete. The ossification of the second metacarpal has extended both into the distalia and into the third metacarpal. Hence from an external inspection (fig. 269) the manus presents the simple carpo-metacarpus characteristic of the species.

In the wing of a young *A. oweni* removed from a skin, and apparently referable to this stage (fig. 271), there is a cartilaginous radiale (*ra.*), and the first and third metacarpals are represented by distinct osteites. The first (*Mtcp.* 1) is a rounded nodule lying preaxiad of the proximal end of the second metacarpal (*Mtpc.* 2); the third (*Mtcp.* 3) is a rod of bone tipped with cartilage lying close alongside its post axial border.

Stage M (Plate 18, figs. 272 and 273).

The specimen of *A. oweni* belonging to this stage (fig. 273) is the only instance I have met with of any important deviation from the normal type of the species. Distad of the radius there is, instead of the ordinary nodular radiale, a semilunar bone (*ra.*), which extends distad a short distance along the preaxial border of the carpo-metacarpus, and seems to consist of radiale *plus* first metacarpal. The third metacarpal (*Mtcp.* 3) is free, and is tipped with cartilage.

In a wing removed from a young stuffed specimen of *A. australis*, which may be referred to this stage (fig. 272), there is a distinct osteite (*ul.*) at the postaxial extremity of the cartilaginous proximal end of the carpo-metacarpus. It is obviously an ulnare.

6. The Pelvic Girdle.

a. In the Adult.

I have nothing to add to the descriptions of Owen (24) and of Mivart (21) except to mention that the curvature of the ischium appears to be slightly but constantly greater in *A. oweni* and *A. bulleri* than in *A. australis*, and to call attention to a statement of Owen's which seems to imply the presence of a perfectly new and unique element in the vertebrate skeleton. He says, " A distinct epiphysial piece of bone, of a compressed and triangular form, is wedged in between the posterior extremity of the ilia and the first three caudal vertebræ."

The bone in question is nothing but the ankylosed neural spines of the first three caudal vertebræ. In one of my specimens it is separated by a well-defined groove from the corresponding centra, and shows no distinction into its constituent parts; it is, however, united both with the centra below and with the ilia above.

b. Development of the Pelvis.

Stage D (Plate 18, fig. 274, and Plate 15, fig. 193).

The pelvic girdle, in this stage, corresponds pretty nearly with Miss Johnson's fig. 7 (18, Plate 27). The pre-ilium (*Pr.Ilm.*) is short, the post-ilium (*Pt.Ilm.*) longer and strongly curved ventrad, the pubis (*Pub.*) slender and nearly straight, the ischium (*Isch.*) broad and expanded distad. The pectineal process (*pect.pr.*) is slightly below the level of the acetabulum, springing obviously from the pubis and not from the ilium, and both pubis and ischium are nearly at right angles to the long axis of the body, as shown by the fact that a vertical section through the acetabulum takes in nearly the whole length of the ischium (Plate 15, fig. 193).

The ischium and pubis are not continuous, as in Miss Johnson's figures, but are separated by a layer of indifferent tissue extending downwards from the acetabulum.

Stage E (Plate 18, fig. 275).

The more advanced condition of the pre- than of the post-ilium is very obvious. The post-ilium (*Pt.Ilm.*) has attained its adult proportions, *i.e.*, is of about the same length as the ischium and pubis; it is also curved downwards, as in the adult, and has altogether a finished appearance. The pre-ilium (*Pr.Ilm.*), on the other hand, is very thin, ends in an irregular border, and falls far short of its ultimate dimensions. These facts certainly lend support to the view that it is the post-ilium of Birds which answers to the ilium of Reptiles, and that the pre-ilium is a secondary structure.

The distinctness of the pubis and ischium is well seen both in a dissection and in sections; there is a well-defined tract of fibrous tissue passing vertically downwards from the acetabulum, and separating their proximal ends from one another.

Stage F (Plate 18, fig. 276).

The most marked change is the forward extension of the pre-ilium (*Pr.Ilm.*), which has attained its ultimate length, although its dorsal region is still imperfect. The pubis and ischium are now distinctly inclined backwards.

Stage G (Plate 18, fig. 277).

The adult form is assumed, the pre-ilium being perfectly formed, and the pubis and ischium having rotated backwards to their final position. There is no appearance of ossification.

Stages H–L (Plate 15, fig. 204, and Plate 18, fig. 278).

The three divisions of the pelvis are now separately ossified. In H, the anterior and posterior borders of the ilium are still cartilaginous, and the pubic osteite is a rod-shaped bone, not more than half the length of the cartilage, and situated at its proximal end. In I and K (fig. 204) ossification has extended farther, and in L (fig. 278) the only cartilaginous parts are the distal ends of the pubis and ischium, the antitrochanter (*Ant.Trch.*), and the pectineal process (*pect.pr.*), together with a narrow tract between the pubis and pre-ilium.

Stages M–O (Plate 18, fig. 279).

In Stage M, the ossifications have extended into and obliterated the connecting cartilages, but have not yet ankylosed. In Stage N (fig. 279) the pectineal process (*pect.pr.*) is seen to be ossified equally by the ilium and pubis. This is also the case in the Ostrich, according to Hatchett Jackson (48, p. 65).

In Stage O, complete ankylosis has taken place.

7. The Hind-Limb.

a. In the Adult.

(Plate 18, fig. 292.)

The hind-limb of *Apteryx* is so typically avian, and has been so thoroughly described by OWEN, that little need be said about it here. It is necessary, however, to supplement his account in one particular.

OWEN states (24, p. 37) that "there is a small cuneiform tarsal wedged into the outer and back part of the ankle-joint." In his 'Anatomy of Vertebrata' (vol. 2, p. 83), the same bone is called a "calcaneal sesamoid," and is said to exist also in several Rasores.* It occurs as an ossification in the thickness of the postaxial moiety of the mesotarsal articular pad (fig. 292, *cent.* 2) and has therefore all the appearance of a sesamoid bone. Its development shows, however, that it is formed by the ossification of a distinct chondrite which has the relations of a postaxial centrale. At the time my Preliminary Note (28) was written I was not aware that it had been figured by MORSE, and figured and described by my Father. It is about 5 mm. long in the adult *A. oweni* and 7 mm. long in the larger species.

I also find in the supposed skeleton of *A. haastii* and in the right leg of one skeleton of *A. australis* a similar but much smaller bone (fig. 292, *cent.* 1), about 4 mm. in diameter, imbedded in the lesser or preaxial moiety of the mesotarsal pad. This is also formed by ossification of a distinct chondrite, which however does not appear, as far as my observations go, until after hatching. It may be looked upon as the first or preaxial centrale. I have not found it in *A. oweni.*

b. Development of the Hind-Limb

Stage D (Plate 18, figs. 280–282).

The femur (*Fe.*) is very slightly shorter than the crus, and the tibia (*Tib.*) and

---

* The bone in question occurs also in *Dinornis*, and thus furnishes an additional point of resemblance between that genus and *Apteryx*. It is apparently not mentioned by OWEN in his memoirs on the Moa, but was described and figured, in 1874, by COUGHTREY (8*a*), in the remarkably perfect, and, indeed, unique feet of *D. ingens*, now in the Otago University Museum. It is also present on both sides in a very fine "individual" skeleton of *D. robustus*, in the same collection. COUGHTREY describes the ligamentous attachments of the bone, which, following OWEN, he calls a "calcaneo-sesamoid." BULLER (8, vol. 1, p. 32, and vol. 2, p. 334), describes and figures it as an "astragalus-like bone," in a foot of *D. elephantopus*, in the Cambridge Museum, and mentions its occurrence in the well-known skeleton of *D. robustus*, in the York Museum; he refers to COUGHTREY'S paper, but has overlooked the fact that the bone is described there, stating that it has not hitherto been noticed in *Dinornis.*

There is another point in the structure of the foot of *Dinornis* which is often wrongly stated in authoritative publications. VON HAAST erroneously concluded that the Dinornithidæ as restricted by him, differed from the Palapterygidæ in the absence of a hallux, but as HUTTON showed in 1876 (15), and as is abundantly proved by the collections in the Otago University Museum, this is not the case, many individual feet of Dinornithidæ having been found with a well-developed hallux.

fibula (*Fib.*) are equal in length and sub-equal in diameter. The tarsus consists of the three chondrites usual in embryo Birds, a large tibiale (*tib.*), a small fibulare (*fib.*), and a large, single, transversely-elongated distale (*dist.*).

All five digits are present. The hallux (fig. 281, *Mt.tsl.* 1) is a rounded nodule of cartilage close alongside the proximal end of the second metatarsal (*Mt.tsl.* 2) and separated by indifferent tissue from the distale. The second digit consists of a metatarsal and one phalanx, the third and fourth each of a metatarsal and two phalanges, and the fifth (fig. 282, *Mt.tsl.* 5) of a short conical cartilage attached by its proximal end to the fibulare and by its preaxial border to the distale.

Stage E (Plate 18, figs. 283 and 284).

The fibula is still of the same length as the tibia, but not more than half its diameter: its distal end is pointed. The tarsals are as in the preceding stage, except that the tibiale and fibulare are very closely applied to the end of the tibia.

The hallux has shifted distad, being attached to about the middle of the second metatarsal; it consists of a metatarsal (*Mt.tsl.* 1) and one phalanx. The fifth digit is still a distinct pointed cartilage (*Mt.tsl.* 5) but has begun to degenerate, being absolutely as well as relatively smaller than in the previous stage.

Stage F (Plate 18, figs. 285–288).

The fibula is still further reduced in size and no longer reaches to the distal end of the tibia. The tibiale (figs. 285 and 287, *tib.*) has sent off the ascending process (*asc.pr.*) which extends proximad along the anterior (external) face of the tibia, and neither in this nor any other stage shows the slightest indication of being a distinct chondrite comparable to an intermedium. The fibulare (fig. 286, *fib.*) is still distinct but smaller proportionally than in previous stages. The mesotarsal joint has made its appearance (fig. 287) by the intrusion of a mass of connective tissue—the rudiment of the articular pad—between the tibiale and the distale on the posterior (flexor) aspect of the limb. On the postaxial side a concentration of nuclei in this tissue (*cent.* 2′) indicates the position of the second or postaxial centrale.

It is worth mentioning that the articular pad does not appear to be a syndesmosis (*cf.* 14) *i.e.* a fibrous pad formed, like the cartilages it separates, from the common blastema of the limb, but to be formed of connective tissue, unconnected with the limb-rudiment, which intrudes between the proximal and distal tarsals on the appearance of the mesotarsal flexure. Its origin appears therefore to support SUTTON'S view (50) of the origin of interarticular cartilages, viz., that they are modified tendons which have become drawn in between the opposed surfaces of the bones forming the joint. This being the case the question naturally arises whether a nodule of hyaline cartilage appearing in such a structure can be properly counted as a tarsal. I think, however, that the fact of the two chondrites which I consider as centralia making their appearance in this way may be accounted for on the hypothesis that, being vestigial or obsolescent structures, their origin is greatly retarded.

The hallux (fig. 285) has nearly reached its adult position, and the second, third, and fourth digits have acquired their full number of phalanges. The rudiment of the fifth digit (fig. 288, *Mt.tsl.* 5) has undergone histological degeneration, being no longer formed of hyaline cartilage but of indifferent tissue. It is also greatly reduced in size, being only 0·25 mm. long as against 0·6 mm. in Stage E, and 1·2 mm. in Stage D (*cf.* figs. 282, 284, and 288, which are all drawn to the same scale). It is, therefore, evident that the fifth digit undergoes gradual degeneration in *Apteryx* instead of concrescing with the fourth metatarsal, as in the Chick (3).

Stage G (Plate 18, figs. 289–291).

The adult form is assumed in all essential respects (fig. 289). The shafts of the femur (*Fe.*) and tibia (*Tib.*) are ossified in about their middle thirds, and in one specimen (*A. australis*) bone has also appeared in the fibula.

The tibiale has partly fused with the tibia and the fibulare (fig. 290, *fib.*) with the tibiale. The concrescence is, however, incomplete, some sections showing both cartilages as distinct structures. The distal surface of the tibiale has assumed its normal pulley-like form. The intrusive connective tissue from which the mesotarsal articular pad is formed has increased greatly in quantity (fig. 291), and the postaxial centrale (*cent.* 2) appears in it as a distinct rounded nodule of cartilage.

The distale (*dist.*) has partially fused with the second and fourth metatarsals (figs. 290 and 291), but the third (fig. 291) is still free.

Stage H.

Ossification has greatly advanced, the thigh and shank bones having well ossified shafts. The tarsals are still cartilaginous, but the metatarsals are bony, with the exception of that of the hallux. They are still free and are readily separable both from one another and from the distale. In the second and third digits all the phalanges are ossified, but in the fourth, the 2nd–5th phalanges are cartilaginous. Perhaps the late appearance of ossification in this digit may be looked upon as the first step in the process which, in the Ostrich, has resulted in its complete atrophy.

Stage I.

Ossification has advanced further, all the phalanges as well as the first metatarsal being bony.

Stages K and L.

Endosteal deposits of bone have appeared in both tibiale and distale, and the second, third, and fourth metatarsals are firmly ankylosed. In K the mesotarsal pad still encloses a single postaxial chondrite, but in L a second much smaller nodule or cartilage is present in the preaxial moiety of the pad. This is the first or preaxial centrale.

Stage M.

This specimen differs from the adult only in having the tibiale still free from the tibia and the distale from the metatarsus, and in the centrale being still cartilaginous.

VI.—THE MUSCLES OF THE WING.

(Plate 19, figs. 293–296.)

OWEN'S description of the muscles of the wing is incomplete in certain particulars.

In the specimens examined by me there is no pectoralis tertius, but only a pectoralis major (fig. 293, *pect.maj.*) and a pectoralis secundus or subclavius (*subcl.*), both of which correspond with OWEN'S description. The account of the coraco-brachialis is hardly correct. The coraco-brachialis superior (*cor.brach.sup.*) is a large muscle arising from the dorsal half of the postaxial border of the coracoid and inserted into the proximal third of the humerus. The coraco-brachialis inferior (*cor.brach.inf.*) is a much smaller muscle arising from the ventral half of the postaxial border of the coracoid and inserted by a short tendon into the head of the humerus.

After describing the muscles of the shoulder OWEN concludes his account of the myology of the wing as follows :—

"A minute flexor, wanting the attachment to the scapula which exists in birds of flight, and arising solely from the humerus, glides along the front of that bone, chiefly as a delicate tendon to be attached to the inner part of the ulna.

"A single extensor, almost equally tendinous and delicate, arises from the scapula and represents the 'long extensor' of VICQ D'AZYR. It is inserted into the rudimental olecranon.

"There is a tendinous trace of a flexor and extensor of the minute monodactyle manus; but the motions of the rudimental wing and its terminal hook would seem to be produced as much by the cutaneous muscles which converge to be inserted into the integument connected with it, as by the feeble representatives of the true wing-muscles above described."

This account is imperfect in many particulars. Both biceps and triceps are incorrectly described, and the muscles of the forearm are entirely overlooked. The omission to notice them is probably due to the very thick and tough fascia by which they are covered, although it must be remembered that the great variability of the entire wing may account for many discrepancies between the present account and that just quoted. It is a curious circumstance that whenever subsequent observers have had occasion to correct the original description of *Apteryx*, the result has been to show the bird to be less aberrant and more typically avian than it was considered to be by the distinguished anatomist to whom we owe our first knowledge of its structure.

The *biceps* (fig. 293) is a long slender muscle fleshy in about its middle third. It arises by a single tendon from the acro coracoid tuberosity (*acr.cor.*), and is inserted, also by an undivided tendon, into the radius at about the junction of its proximal and middle thirds.

The *triceps* is a slender, two-headed muscle. The long head arises from the postaxial border of the scapula immediately dorsad of the glenoid cavity and passes outside the teres to join the short head which arises from the distal three-fifths of the dorsal surface of the humerus. The triceps is inserted by a broad tendon into the olecranon.

The *brachialis anticus* (figs. 293, 294, and 296, *brach.ant.*) is a small muscle arising from the distal eighth of the ventral (flexor) surface of the humerus and inserted into about the proximal sixth of the radial surface of the ulna.

Lying immediately mesiad of the preceding is a small triangular muscle (fig. 296, *brach.ant.access.*) with very similar origin and insertion. It arises from the internal tuberosity of the humerus and is inserted into the proximal end of the ulna. It may be called the *brachialis anticus accessorius,* and is probably due to a duplication of the small flexor of the forearm such as is occasionally found in Mammals. It was present in two wings of *A. bulleri,* but was absent on both sides of the specimen of *A. australis* on which most of my observations were made.

The *anconeus* (figs. 293 and 295, *ancon.*) arises by a flat tendon from the external tuberosity of the humerus; its fibres diverge in a fan-like manner, and are inserted into the greater part of the outer surface of the shaft of the ulna. SELENKA (49) makes no mention of this muscle: MORRISON WATSON (51) failed to find it in Penguins, in some genera of which it is said by other observers to exist. It must act partly as a pronator.

The single *supinator* (figs. 293 and 295, *supin.*) arises with the preceding muscle from the external tuberosity of the humerus, and is inserted into the anterior (preaxial) border of the shaft of the radius.

The single *pronator* (figs. 294 and 296, *pron.*) arises by a flat tendon from the internal tuberosity of the humerus: its fibres diverge, and are inserted into the distal two-thirds of the inner (flexor) surface of the radius.

As the pronator on the inner may be said to balance the supinator on the outer surface of the forearm, so the externally situated anconeus is balanced by a very similar muscle (figs. 294 and 396, *flex.prof.int.*) which arises from the internal tuberosity of the humerus, and is inserted by diverging fibres into the inner (flexor) face of the distal two-thirds of the ulna. It appears to answer to the *flexor profundus interior gallinaceorum* of SELENKA (49), which is well developed in the common fowl, but has nothing like the same proximo-distal extent as in *Apteryx*. It also seems to correspond with the muscle called *supinator accessorius* by MIVART (22) in *Iguana*. In the specimen of *A. australis* examined, the tendon of origin of this muscle crosses that of the pronator (fig. 294).

The *extensor carpi ulnaris* (figs. 293 and 295, *ext.carp.ul.*) is a very slender muscle, arising in common with the supinator, of which, proximad, it forms a part. Its fleshy portion is extremely small, and soon passes into a long and very delicate tendon, which is inserted into the dorsal surface of the carpo-metacarpus, near its postaxial border. In a specimen of *A. bulleri* (fig. 295) this muscle was entirely tendinous.

The *extensor indicis proprius* (figs. 293 and 295, *ext.ind.prop.*) is a small muscle arising from the contiguous surfaces of the radius and ulna. Distally it passes into a strong tendon which, in the specimen of *A. australis* (fig. 293), could not be traced beyond the middle of the carpo-metacarpus, but in that of *A. bulleri* (fig. 295) is inserted into the base of the distal phalanx of the single (second) digit. I call this muscle an extensor indicis rather than an extensor digitorum communis, because of its origin.

The *extensor metacarpi radialis brevis* (figs. 293 and 295, *ext.metacarp.rad.brev.*) is a very small muscle, arising with the preceding from the contiguous surfaces of the radius and ulna, and passing distad into a slender tendon, which curves preaxiad over the dorsal surface of the carpo-metacarpus to be inserted into its proximal border.

The *flexor digitorum profundus* (figs. 294 and 296, *flex.dig.prof.*) is a small muscle arising with the two preceding from the contiguous surfaces of the radius and ulna. It is continued into a rather broad flat tendon which passes along the inner (flexor) face of the carpo-metacarpus and proximal phalanx, and is inserted into the base of the distal phalanx.

In one specimen (*A. australis*) a minute tendon (fig. 294, *flex.carp.rad.*) was seen preaxiad of that of the deep flexor, and passing to the preaxial side of the carpo-metacarpus: probably it is a vestigial *flexor carpi radialis*.

In one specimen of *A. bulleri* a few fleshy fibres (fig. 295, *interos.dors.*) were seen on the dorsal face of the carpo-metacarpus, and immediately preaxiad of the extensor indicis tendon: they probably represent an *interosseus dorsalis*.

The wing of *Apteryx* is thus seen to have the usual flexors and extensors of the forearm, and a rather unusually large development of muscles acting as pronators and supinators for so small and obviously vestigial an organ. There is also a fair-sized flexor and an equally large extensor of the single digit, as well as two small extensors and a minute flexor of the carpo-metacarpus.

The evidences of degeneration are very clear, and the variability of the muscles is noteworthy, the two specimens examined differing considerably in minor points.

The differences in the myology of the wing between the Kiwi and the Ostrich

(20, p. 549) are very marked: I have not been able to consult any detailed description of the wing-muscles in the other Ratitæ.

VII.—THE BRAIN.

a. In the Adult.

(Plate 19, figs. 297–303.)

The brain and cerebral nerves of *Apteryx* are described by OWEN in a supplementary memoir (24, *b*) illustrated by several figures. As, however, the description is imperfect in some particulars, and the figures small, and drawn from specimens from which the pia with its bloodvessels had not been removed, I have thought it advisable to preface the account of the development of the brain by a brief description of the adult organ taken from well-preserved brains of *A. australis* and *A. bulleri*. The terminology employed was suggested in a short paper in 'Nature' (29).

Comparing the brain of *Apteryx* with that of other Birds, *e.g.*, the Turkey, figured by HUXLEY (16, pp. 302 and 303), the Goose, Gull, and Eagle by OWEN (25, pp. 118 and 119), and the Pigeon by WIEDERSHEIM (53, p. 165) and myself (27, pp. 255 and 259), one is struck with the proportionally large size of the cerebral hemispheres (fig. 297, *Prosen.*), and with the way they overlap the cerebellum (*Epen.*). In this respect *Apteryx* resembles the Passerine Birds more closely than the comparatively generalized Gallinæ and Columbæ. As in other Birds, the outline of the cerebellum is roughly semicircular from before backwards (figs. 299 and 301), and is marked externally by grooves, which radiate from the flocculus (*floc.*): in Carinatæ the grooves on the anterior, as well as those on the posterior moiety of the epencephal are visible externally, while in *Apteryx* the anterior ones are completely hidden, the hemispheres extending as far back as the flocculi. As a consequence of this, the pineal peduncle (fig. 301, *Pin.*), instead of being vertical, is inclined backwards.

Another peculiarity is the position of the diencephal, which is best seen in a sagittal section (fig. 301). In most Birds the lamina terminalis looks directly forwards, the optic chiasma downwards, while the foramen of MONRO is in the antero-dorsal angle of the diacœle, or third ventricle, and the anterior commissure just beneath it. In *Apteryx* the whole of this division of the brain is as it were tilted backwards: the lamina terminalis (*lam.term.*) looks upwards, and the optic chiasma (*opt.chs.*) forwards, the foramen of MONRO (*for.M.*) is in the postero-dorsal angle of the diacœle (*di.cœ.*) and the anterior commissure (*ant.com.*) in the middle of its dorsal wall. In the same way, the optic commissure (*opt.com.*), or thin roof of the iter, is vertical, instead of horizontal.

The combined anterior commissure (*ant.com.*) and corpus callosum (*corp.call.*) is unusually large, the posterior commissure (*post.com.*) small. The pineal body (figs. 29 and 301, *Pin.*) has the usual form; the pituitary body (*Pty.*) is globular and connected with a narrow conical infundibulum (*inf.*).

The relations of the more important cavities of the brain, including the small optocœles or ventricles of the optic lobes (*opt.cœ.*) are shown in figs. 300–303.

The numerous olfactory nerves are given off from the ventral and anterior surfaces of the rhinencephal (*Rhinen.*), and pass, some almost directly downwards, others forwards, to the Schneiderian membrane. (See Plate 13, figs. 157 and 158, *Nv. I.*)

The small optic nerves (*Nv. II.*) pass from the chiasma downwards and forwards to the eye. The nerves of the eye muscles (*Nv. III.*, *Nv. IV.*, *Nv. VI.*) have the usual relations; their mode of exit from the skull has already been described (pp. 46 and 47).

The trigeminal (*Nv. V.*) is said by OWEN (24, p. 324) to leave the cranium before dividing, but this not the case. Its root lies immediately over the trigeminal foramen (Plate 14, fig. 167, *Nv. V.*), and it divides shortly after its origin into two trunks; one of which—the common trunk of the second and third divisions (fig. 167, *Nv.* $V.^{2,3}$)—passes downwards and forwards through the trigeminal foramen, while the other—the first division or orbitonasal nerve (figs. 164–166, *Nv.* $V.^{1}$)—passes forwards along the surface of the orbitosphenoid bone, finally making its exit from the skull by the orbitonasal foramen (figs. 162 and 163, *Nv.* $V.^{1}$). The sections of Stage H show conclusively that OWEN is in error when he says that it is the ventral ramus of the orbitonasal which supplies the tactile organ at the end of the beak, while the dorsal ramus "becomes lost upon the septal membrane"; as a matter of fact it is the dorsal ramus (figs. 149–157, *Nv.* $V.^{1a}$) which supplies the tactile organ; the ventral ramus (*Nv.* $V.^{1b}$) supplies the outer surface of the beak.

The seventh nerve (figs. 298 and 299, *Nv. VII.*) arises from the lateral region of the metencephal (*Meten.*), behind and above the root of the fifth; it is immediately followed by the eighth (*Nv. VIII.*) which, as already stated (p. 45), divides into two main and about three smaller branches, which enter the auditory capsule through separate foramina. There is nothing of special interest in the origins of the ninth to the twelfth nerves (*Nv. IX.*, *X.*, *XI.* and *XII.*).

b. Development of the Brain.

My observations on this subject are very imperfect owing to lack of material; they are however not without interest, since they seem to prove conclusively what might have been inferred from adult anatomy that the brain of *Apteryx* is simply a typical avian encephal with reduced optic lobes.

Stages A and *B* (Plate 4, figs. 17, 18, and 22–30).

The metencephal (*Meten.*) has already undergone a considerable thickening of its floor, while its roof is very thin; the cerebellum or epencephal (fig. 17, *Epen.*) is indicated merely by a thickening of the antero-dorsal region of the hind-brain. The floor of the metacœle or fourth ventricle (*mt.cœ.*) has an undulating antero-posterior contour (fig. 17); the depressions probably correspond with the doubtful encephalomeres into which this region of the brain is frequently divided.

The mesencephal, as already seen from an external view (Plate 3, figs. 1 and 2, *Mesen.*), is small, and shows no indication of optic lobes on its dorsal surface.

The diencephal is large, and contains a spacious diacœle or third ventricle (*di.cœ*). The pineal body (figs. 17 and 18, *Pin.*) has the form of a narrow diverticulum, and immediately cephalad of it is a second out-pushing of the roof of the diacœle (*Pr.Pin.Divert.*) which I have not seen mentioned. It is very different in form from the pineal offshoot, being expanded at its origin, and narrowing almost to a point distad. This structure, which apparently gives rise to the velum interpositum, may be called the *prepineal diverticulum.*

The ventral region of the diencephal is dilated to form the infundibulum (*inf.*) to which the pituitary out-pushing of the stomodæum (*Pty.*) is closely applied. Its lateral regions give off the optic vesicles (fig. 24, *Opt.ves.*) which are already invaginated.

The prosthiencephal (secondary fore-brain, unpaired cerebral rudiment) has already divided into a median portion, the basi-cerebrum, containing a wide cavity, the aula (figs. 17, 22, and 23), and paired offshoots, the prosencephals or cerebral hemispheres, containing large prosocœles or lateral ventricles (fig. 22, *prs.cœ.*), the walls of which are still of approximately equal thickness throughout.

Stage C (Plate 5, figs. 34–42).

The metencephal and epencephal (fig. 36, *Epen.*) have undergone comparatively little alteration, but in the other divisions of the brain changes of considerable importance have taken place.

The mesencephal, although still simple in front (fig. 34, *Ms.cœ.*), has divided posteriorily into a median ventral portion, the basi-opticus (fig. 35, *Bs.Opt.*), and paired offshoots, the optic lobes (*Opten*). Corresponding with this the mesocœle, which is still a simple cavity in the anterior part of the region (fig. 34, *Ms.cœ.*), is distinguishable into a median iter (fig. 35) and paired optocœles (*Opt.cœ.*).

In the fore-brain the posterior or outer walls of the prosocœles (fig. 34, *Prs.cœ.*) have undergone a considerable thickening, forming the rudiments of the corpora striata (*corp.stri.*). The aula is reduced to a small cleft, communicating by narrow apertures, the foramina of MONRO (*for.M.*), with the prosocœles.

Stages D–F (Plate 19, figs. 304–307).

The brain has advanced immensely between Stages C and D, but very little change is noticeable between D and F, the chief differences being the greater size and rounder form of the hemispheres in the later stage (*cf.* figs. 304 and 306).

As shown by a sagittal section (fig. 307), the flexure between the fore- and hind-brain is at its maximum. The metencephal (*Meten.*) has practically assumed its adult characters, except for its strong sigmoid flexure, but the cerebellum (*Epen.*) has the form of a semi-circular flap, marked with a median groove, and closely resembling the corresponding structure in a lizard.

The optic thalami (fig. 307, *Opt.thal.*) have the form of small rounded prominences projecting inwards from the lateral walls of the dorsal region of the diacœle (*di.cœ.*): the remaining part of the wall of this cavity is still quite thin. Its roof is formed by a projecting sac-like velum interpositum (*vel.int.*), which is apparently derived from the prepineal diverticulum of Stage A.

The long axis of the hemispheres (*Prosen.*) is vertical instead of horizontal, and each shows a very distinct temporal lobe (fig. 305). The corpus striatum (fig. 304, *corp.stri.*) is very large, the mesial wall of the prosocœle (*prs.cœ.*) quite thin.

Stage G (Plate 19, figs. 308 and 309).

This very interesting stage I was only able to examine from sections: the figures are therefore restorations.

The hind-brain (*Meten.*, *Epen.*) has undergone comparatively little alteration, but the mid- and fore-brains show a condition of things as nearly as possible intermediate between Stage F and the adult.

The optencephals (*Opten.*) have become widely separated from one another by the elongation of the optic commissure (*opt.com.*) or medio-dorsal portion of the mid-brain; they have therefore come to occupy a lateral position as in ordinary birds (see also Plate 12, fig. 143). At the same time the hemispheres (*Prosen.*) have grown backwards so as partly to cover the mid-brain. There is only wanted an increase in size, and forward extension of the cerebellum to convert the brain of *Apteryx* at this stage into a typical avian encephal.

Stage H (Plate 17, fig. 310).

The adult characters are now fully attained, except that the optic lobes (*Opten.*) and the flocculi (*floc.*) are considerably larger than in the fully developed organ.

VIII.—THE EYE.

(Plate 19, fig. 311.)

I have only a single fact to mention with regard to the eye, but that is one of considerable interest. As OWEN showed, the pecten is absent in the adult, *Apteryx* being in this respect unique among birds. But in advanced embryos of stages H and I there is a distinct pecten in the form of a conical pigmented prominence, about 1–2 mm. long, passing from the entrance of the optic nerve towards the back of the lens. Figs. 311 is taken from a dissection of Stage I: fig. 158 (Plate 13) shows its relations in a section of Stage H.

SUMMARY.

1. *New Terms Proposed.*

Chondrite, an independent cartilaginous element, or centre of chondrification.

Osteite, an independent bony element or centre of ossification.

Centrochondrite, cartilaginous, *Centrosteite*, bony, elements of a vertebral body.

Neurochondrite, cartilaginous, *Neurosteite*, bony, elements of a neural arch.

Pleurochondrite, cartilaginous, *Pleurosteite*, bony, elements of a rib or autogenous transverse process.

Prochordal plate, the middle trabecula of RATHKE; a mass of blastema formed above (cephalad of) the upturned anterior end of the notochord, and continuous behind with the parachordals.

Prochordal cartilage, a nodular chrondrite which appears in the prochordal plate, and gives rise to the medio-dorsal portion of the dorsum sellæ.

Coraco-vertebral angle, the angle enclosed between the long axis of the coracoid and that of the vertebral column.

Syn-sacrum, the entire series of vertebræ which support the ilia, and include thoracic, lumbar, lumbo-sacral, sacral, and caudal vertebræ.

2. *External Characters.*

In Stage C, corresponding with a sixth day Chick, there is a well marked operculum growing backwards from the hyoidean fold, and covering the third (? and fourth) visceral cleft. A rudiment of this structure is seen in the preceding stage (pp. 30 and 31, Plate 3, figs. 2, 3, and 4, Plate 5, fig. 41).

In Stage A, corresponding in general features with a fourth day Chick, but in some respects not more advanced than one of the third day, the limbs have already attained their permanent position, so that if the backward shifting of the appendages so noticeable in the Chick occurs in *Apteryx*, it must take place at an unusually early period (p. 28; Plate 3, fig. 1).

From the first appearance of the feather-papillæ there are well-marked pterylæ and apteria, most of which can be made out with tolerable distinctness in the adult (pp. 33, 34, and 35; Plate 3, figs. 8, 10, and 12).

The wing of the adult has a well-marked pre- and post-patagium, and amongst its feathers may be distinguished nine or ten cubitals, two or three metacarpals, one mid-digital, and a row of tectrices majores. The barbicels of the feathers are slightly curved (p. 37; Plate 3, figs. 14, 15, and 16).

The fore-limb passes through a stage in which it is a tridactyle paw with sub-equal digits, followed by one in which it is a typical wing with hypertrophied second and partially atrophied first and third digits (pp. 32 and 33; Plate 3, figs. 6 and 9).

The nostril has acquired its final position at the end of the beak in Stage E: up to the middle of incubation the whole respiratory region of the olfactory chamber from the anterior nares to the commencement of the turbinals, is filled with a solid mass of epithelial cells, through which a passage is formed at a later period (pp. 61, 63, and 65; Plate 10, fig. 114; Plate 10, fig. 128; Plate 12, figs. 150 and 151). At no stage is there any trace of the caruncle or "egg-breaker" at the end of the beak (p. 35).

3. *The Law of Growth.*

The head attains its maximum size in Stage F, *i.e.*, shortly before the appearance of ossification: thereafter the beak increases, and the brain-case diminishes in relative size, the beak attaining its full proportional length in Stage H—probably about the middle of incubation—while the brain-case continues to undergo a relative diminution in size up to adult life (p. 40; Plate 6 and Plate 7, fig. 46).

The sternum and the pectoral and pelvic-girdles attain their maximum or nearly so in Stage F, thereafter undergoing but little alteration (pp. 40 and 42; Plate 6, and Plate 7, fig. 47).

The fore-limb also attains its maximum proportional size in Stage F, undergoing little subsequent alteration (p. 42; Plate 6, and Plate 7, fig. 48).

The hind-limb increases rapidly and regularly up to Stage K (time of hatching) between which period and the attainment of adult proportions there appears to be a slight decrease in relative length (p. 42; Plate 6 and Plate 7, fig. 49).

4. *Specific and Sexual Differences.*

The beak is relatively slightly longer in *A. australis* than in *A. oweni*: the difference between the two sexes, in this respect, is very slight (p. 40).

The pelvic girdle and the sternum are relatively longer in *A. australis* than in *A. oweni*: the reverse appears to be the case with the scapula (p. 42; Plate 7, fig. 47).

The hind-limb is relatively longer in the male than in the female, the differences holding good for all three divisions of the leg. There appear to be no constant specific differences in this respect (p. 42; Plate 6 and Plate 7, fig. 49).

In *A. australis* the alar claw is gently curved and of a light horn colour, blotched with black (p. 37): the length of the corpus sterni, as defined on p. 85, is greater than half its breadth, and the anterior margin of the sternum is concave, with an even curve (p. 85; Plate 16, figs. 208 and 209): the manus has a carpo-metacarpus, but no free radiale or ulnare, and the third metacarpal is ossified from the second (pp. 92 and 97; Plate 17, fig. 241, and Plate 18, figs. 266 and 270).

In *A. oweni* the alar claw is soft and weak, gently curved, and of a light horn colour (p. 37): the length of the corpus sterni is less than half its breadth, and the anterior sternal margin is sinuous (p. 85; Plate 16, figs. 214 and 215): the manus has a free radiale in addition to the carpo-metacarpus, and the third metacarpal is ossified separately (pp. 93 and 98; Plate 17, figs. 242–244).

In *A. bulleri* the alar claw is black and strongly curved (p. 37): the length of the corpus sterni is less than half its breadth, and the anterior sternal margin is evenly curved and much more deeply emarginate than in *A. australis* (p. 85; Plate 16, figs. 212 and 213): the manus is very variable; there is sometimes a simple carpo-metacarpus, sometimes a radiale and carpo-metacarpus, sometimes a radio-distale and free second and third metacarpals, sometimes the second metacarpal alone fuses with the carpals and sometimes with the distalia only, leaving a free radiale; the third metacarpal is, sometimes at least, ossified separately (pp. 93 and 97; Plate 17, figs. 245–249, and Plate 18, fig. 268).

My observations on *A. haastii* are not sufficiently complete to have any systematic value.

5. *The Skull.*

In Stages A and B the only cranial rudiments present are the parachordal plates, continued cephalad into the prochordal plate, and the visceral arches (pp. 56 and 57; Plate 4).

In Stage C the trabeculæ have appeared, and are continuous with the parachordals; the prochordal plate sends off paired processes directly upwards in the mesencephalic flexure, and laterad of the third nerves (pp. 57 and 58; Plate 5, figs. 35–37).

In Stages E and F the pituitary fossa is pierced by three apertures in longitudinal series—the anterior, middle, and posterior basicranial fontanelles. A theoretical explanation of these is given in fig. 103, Plate 10 (p. 60). The middle fontanelle has disappeared in Stage G (p. 63; Plate 11, fig. 126), but the anterior and posterior are still recognisable in Stages H and I (pp. 66 and 70; Plate 12, fig. 148; Plate 13, fig. 161; Plate 14, figs. 167, 173, and 174). Through the anterior fontanelle the pituitary pedicle passes.

The medio-dorsal portion of the dorsum sellæ arises as a distinct chondrite, the prochordal cartilage (pp. 62 and 64; Plate 10, figs. 109 and 111; Plate 11, fig. 126), which in Stages F and G is quite separate both from the trabecular and from the parachordal regions of the skull.

None of the stages show a separate prenasal cartilage or intertrabecula: if present as a distinct chondrite it certainly does not extend further backwards than the anterior presphenoidal region; the posterior presphenoidal region is clearly formed from the trabeculæ (p. 59; Plate 9, figs. 90 and 91).

In Stages D, E, and F the presphenoid is a vertical plate of considerable antero-posterior extent, and gives origin to a pair of large orbitosphenoids (pp. 59, 61, 62; Plate 9, figs. 85 and 86; Plate 10, figs. 96–98 and 104–108). In Stage G the orbitosphenoids have begun to atrophy (p. 64; Plate 11, figs. 123–126) and in later stages are reduced to narrow bars of cartilage (p. 47; Plate 9, fig. 75), the presphenoid at the same time undergoing a great diminution in antero-posterior extent.

The olfactory capsules extend backwards to the optic foramina mesiad of the eyes

(Plate 9, fig. 77; and Plate 13, fig. 158): there is at no stage an interorbital septum.

The turbinals are unusually well developed and are divisible into anterior, middle, posterior, anterior accessory, ventral accessory, and naso-turbinal folds. Alone amongst these the anterior accessory turbinal is formed as a hollow invagination of the wall of the olfactory capsule, not as a plate-like ingrowth (p. 49; Plate 8, fig. 57; Plate 9, figs. 83 and 84; Plate 12, fig. 151; Plate 13, figs. 153–158): its cavity contains a prolongation of the antrum of HIGHMORE.

These are paired, rod-like, JACOBSON'S cartilages, lying one on each side of the rostrum in the vomerine region (p. 51; Plate 9, figs. 76 and 77; Plate 13, figs. 155–157).

In late embryonic life, and even in the adult, the quadrate articulates with the roof of the tympanic cavity by a double articular surface (p. 51; Plate 9, figs. 78 and 79).

The hyoidean portion of the tongue-bone chondrifies late—subsequently to Stage G—and never ossifies (pp. 52 and 65; Plate 9, fig. 82, and Plate 11, fig. 132).

6. *The Vertebral Column.*

As in other Birds, the atlas arises from a post-occipital intercentrum and a pair of neurochondrites. The axis consists originally of seven pieces; its own centrochondrite, the odontoid or centrochondrite of the atlas, a post-atlantal intercentrum, a pair of neurochondrites, and a pair of pleurochondrites. In both vertebræ each of these elements ossifies separately (pp. 73 and 79; Plate 15, figs. 175–179 and 194).

The way in which the notochord is constricted by the ingrowing centrochondrites differs greatly in the various regions (p. 79; Plate 15, figs. 194–197).

The atlas and axis in a newly-hatched embryo differ far less than in the adult from those of the other Ratitæ (p. 73).

Two intercentra are described in the caudal region (pp. 78 and 84; Plate 15, figs. 188 and 206).

A new method of writing the vertebral formula of Birds is adopted (pp. 78, 81, and 83).

7. *The Sternum and Ribs.*

In Stage E the sternum is nearly horizontal in position; only two sternal ribs are attached to it by joints, and a third by indifferent tissue; and it does not extend caudad of the attachment of the third (p. 87; Plate 16, fig. 216). In Stage F three ribs are united to it by joints, and a fourth by fibrous tissue (p. 87; Plate 16, fig. 217). In Stage G there is the normal number of four sternal ribs in connection with the sternum. These facts seem to show that the costal sternum does not originate by the union of the ventral ends of all four sternal ribs, but that it extends backwards independently of the third and fourth ribs, meeting them in turn and becoming united with them by joints.

In some adult specimens the sternum bears a low median ridge, probably to be looked upon as a vestigial keel (p. 86; Plate 16, figs. 210, 211, and 213).

The form of the adult sternum is very variable (Plate 16, figs. 208–215).

8. *The Shoulder-Girdle.*

Up to Stage H the shoulder-girdle is a single cartilage (Plate 17, figs. 233–237). During that stage the procoracoid and coracoid are differentiated by fenestration (p. 91; Plate 17, fig. 238). The procoracoid degenerates into a ligament (p. 92; Plate 17, figs. 239 and 240), which is sometimes present in the adult (p. 89; Plate 16, figs. 225, 226, and 229). The coracoid fenestra may persist or may be filled up by a preaxial extension of the coracoid (p. 89; Plate 16, figs. 225–232).

Acromial, procoracoid, and acrocoracoid tuberosities are present (p. 90; Plate 16, figs. 225–232).

The coraco-scapular angle varies from 150° to 122°. In Stage E the scapula is curved backwards over the ribs (p. 91; Plate 16, fig. 216). In the same stage the coraco-vertebral angle is 35°; by Stage H it has increased to 90° (p. 91).

The adult shoulder-girdle is subject to great variation both in form and size (Plate 16, figs. 225–232).

9. *The Fore-Limb.*

In the carpus a radiale, an ulnare, and the three preaxial distalia are distinguishable in early stages (pp. 94–95; Plate 17, figs. 254–260). The distalia usually concresce with the second and third metacarpals to form a carpo-metacarpus, with which the radiale and ulnare may or may not become united (pp. 95–97; Plate 17, figs. 261–264, and Plate 18, figs. 265–273).

The pollex usually atrophies at an early stage, but a vestige of it may persist (pp. 95 and 97; Plate 17, figs. 257 and 263; Plate 18, fig. 271).

The manus is fairly constant in structure in *A. australis* and *A. oweni*, but is very variable in *A. bulleri* (p. 92; Plate 17, figs. 241–253).

10. *The Pelvic-Girdle.*

The pubis and ischium are nearly vertical in Stages D and E, and gradually become rotated backwards (pp. 98 and 99; Plate 18, figs. 274–277).

The post-ilium is already fully formed in Stage D, the pre-ilium not until Stage G (pp. 98 and 99; Plate 18, figs. 274–277).

The pectineal process is ossified equally from the ilium and the pubis (p. 99; Plate 18, fig. 279).

11. *The Hind-Limb.*

In the tarsus a tibiale, a fibulare, and a single distale are distinguishable in Stages D and E (p. 101; Plate 18, figs. 280 and 283). In F a postaxial centrale appears in the rudiment of the mesotarsal articular pad (p. 101; fig. 287); in G it becomes chondrified (p. 102; fig. 291), and in the adult ossified (p. 100; fig. 292). A smaller preaxial centrale is first seen as a distinct chondrite in Stage L (p. 102); in the adult of *A. australis* and *A. haastii* (?) it was observed as a separate bone in the preaxial moiety of the mesotarsal pad (p. 100, fig. 292).

In Stage D the fifth digit is represented by an elongated metatarsal (p. 101; fig. 282); in E this has diminished in size (p. 101; fig. 284); and in F undergone almost complete atrophy (p. 102; fig. 288).

12. *Muscles of the Wing.*

The following muscles are present in the wing in addition to those described by OWEN:—Brachialis anticus, supinator, pronator, anconeus, flexor profundus internus, extensor carpi ulnaris, extensor metacarpi radialis brevis, extensor indicis proprius, and flexor digitorum profundus. There may also be a brachialis anticus accessorius, an interosseus dorsalis, and probably a flexor carpi radialis (p. 104; Plate 19, figs. 293–296).

The biceps arises from the acrocoracoid, the triceps by a long head from the scapula and by a short head from the humerus (p. 104; fig. 293).

13. *The Brain.*

The mesencephal is unusually small from the first (p. 108; Plate 3, figs. 1 and 2). In Stages D–F the optic lobes are dorsal (Plate 19, figs. 304 and 306); in G they become lateral by the transverse extension of the optic commissure or median portion of the roof of the mesocœle (p. 109; figs. 308 and 309); in H they are already ventral, although larger proportionally than in the adult (fig. 310).

The diencephal becomes tilted backwards in later stages, its dorsal wall becoming posterior, and the foramen of MONRO postero-dorsal instead of antero-dorsal (p. 106; fig. 301).

The anterior commissure and corpus callosum are large (fig. 301).

The cerebral hemispheres are of unusual proportional length, and partly cover the cerebellum (figs. 297, 299, and 301).

14. *The Eye.*

A pecten is present during late embryonic life (p. 109; Plate 13, fig. 158, and Plate 19, fig. 311).

15. *Phylogeny.*

The following characters support the view that *Apteryx* is derived from a typical Avian form capable of flight:—

a. The presence of an alar membrane or patagium (p. 36; Plate 3, figs. 14 and 15).
b. The presence of pterylæ and apteria (pp. 33, 34, and 35; Plate 3, figs. 8, 10, and 12).
c. The presence of remiges and of tectrices majores (p. 37; Plate 3, figs. 14 and 15).
d. The attitude assumed during sleep (p. 36).
e. The presence of two articular facets on the head of the quadrate (p. 51).
f. The presence of a pygostyle (p. 83).
g. The extreme variability of the sternum, shoulder-girdle, and wing, indicating degeneration.
h. The occasional occurrence of a median longitudinal ridge or vestigial keel on the sternum (Plate 16, figs. 210, 211, and 213).
i. The position of the shoulder-girdle and sternum in Stage E (p. 91; Plate 16, fig. 216).
j. The presence of vestigial acromial, procoracoid, and acrocoracoid processes.
k. The fact that the skeleton of the fore-limb is that of a true wing in Stage F (p. 94; Plate 17, fig. 256).
l. The early assumption of undoubted avian characters in the pelvis (p. 98).
m. The typically avian characters, both as to structure and development, of the vertebral column and hind-limb.
n. The fact that the brain passes through a typical avian stage with lateral optic lobes (p. 109; Plate 19, figs. 308 and 309).
o. The relations of the subclavius muscle (p. 90; Plate 19, fig. 293).

On the other hand the total absence of rectrices tells against this view.

The following characters indicate derivation from a more generalised type than existing Birds:—

a. The characters of the chondrocranium, especially in the earlier stages (pp. 59, &c.). Many of these peculiarities, *e.g.*, the absence of an interorbital septum, may, however, be adaptive and correlated with the diminished eyes and the enlarged olfactory organs.
b. The presence of an operculum in early stages (pp. 30 and 31; Plate 3, figs. 2, 3, and 4; Plate 5, fig. 41). As however this structure has not been described in Reptiles, it either proves nothing or too much.
c. The presence of a well-marked procoracoid in comparatively late embryonic life (p. 92; Plate 17, figs. 238 and 239).
d. The characters of the pelvis.

On the other hand, in the following characters *Apteryx* exhibits greater specialisation than other birds :—

a. The early assumption of their permanent position by the limbs (p. 29).
b. The late appearance and obviously degraded character of the hyoid portion of the tongue-bone (pp. 52 and 65).
c. The position of the nostrils and the peculiar mode of development of the respiratory section of the nasal chamber (pp. 61, 63, and 65).
d. The total absence of clavicles.

Such characters as the position of the basipterygoid processes, the broad vomer, and the presence of JACOBSON'S cartilages, being paralleled in existing Carinatæ, some of them even in Passerines, can hardly be considered as of fundamental importance, since they may be derived either from a Proto-Carinate or from an early typical Carinate stock.

Before considering the peculiarities in the development of the sternum as of fundamental importance, it will be necessary to study that of the flightless Carinatæ, and especially of *Stringops* (p. 86).

The general balance of evidence seems to point to the derivation of both Ratitæ and Carinatæ from an early group of typical flying Birds, or *Proto-Carinatæ* (p. 37).

LIST OF WORKS REFERRED TO.

1. ALBRECHT, P. "Die zwischen Gehirn und Hypophysis liegenden Wirbelcentrum complexe." 'Anat. Anzeiger,' 2 (1887), p. 405.
2. BALFOUR, F. M. 'Comparative Embryology.' London, 1881.
3. BAUR, G. "Der Tarsus der Vögel und Dinosaurier." 'Morphol. Jahrb., 8 (1882), p. 417.
4. *Id.* "On the Morphology of Ribs." 'American Naturalist,' vol. 21 (1887), p. 942.
5. BEDDARD, F. E. "Notes on the Visceral Anatomy of Birds, No. 1." 'Zool. Soc. Proc.,' 1885, p. 836.
6. BLANCHARD. 'L'Organisation du Règne Animal ; Oiseaux.' Livr. 1re. (Quoted in 30—I have not seen this work.)
7. BULLER, W. L. "Further Notes on the Ornithology of New Zealand." 'New Zealand Inst. Trans.,' vol. 3 (1870), p. 37.
8. *Id.* 'A History of the Birds of New Zealand.' 2nd Ed. London, 1888.
8*a*. COUGHTREY, M. "Anatomical Notes on the Moa's Leg found at Knobby Ranges, in the Province of Otago." 'New Zealand Inst. Trans.,' vol. 7 (1874), p. 269.
9. FLOWER, W. H. "The Wings of Birds." 'Nature,' vol. 34 (1886), p. 204.
10. FOSTER, M., and BALFOUR, F. M. 'Elements of Embryology.' 2nd Ed. London, 1883.

11. FÜRBRINGER, M. 'Die Morphologie und Systematik der Vögel.' II. Allgemeiner Theil. Amsterdam, 1888.

12. GADOW, H. "On the Morphology of the First and Second Visceral Arches, &c." 'Phil. Trans.,' B, vol. 179 (1888), p. 451.

13. *Id.* "Remarks on the Numbers and on the Phylogenetic Development of the Remiges of Birds." 'Zool. Soc. Proc.,' 1888, p. 655.

14. HOWES, G. B. "Observations upon the Morphology and Genesis of Supernumerary Phalanges, &c." 'Zool. Soc. Proc.,' 1888, p. 495.

15. HUTTON, F. W. "Remarks on Dr. VON HAAST'S Classification of the Moas." 'New Zealand Inst. Trans.,' vol. 9 (1876), p. 363.

16. HUXLEY, T. H. 'The Anatomy of Vertebrated Animals.' London, 1871.

17. *Id.* "On the Classification of Birds." 'Zool. Soc. Proc.,' 1867, p. 415.

18. JOHNSON, A. "On the Development of the Pelvic Girdle and Skeleton of the Hind Limb in the Chick." 'Quart. Journ. Micros. Sci.,' vol. 23 (1883), p. 399.

19. LINDSAY, B. "On the Avian Sternum." 'Zool. Soc. Proc.,' 1885, p. 684.

20. MACALISTER, A. "On the Anatomy of the Ostrich." 'Roy. Irish Acad. Proc.,' 1864, p. 531.

21. MIVART, ST. G. "On the Axial Skeleton of the Struthionidæ." 'Zool. Soc. Trans.,' vol. 10, p. 1.

22. *Id.* "Notes on the Myology of *Iguana tuberculata.*" 'Zool. Soc. Proc.,' 1867, p. 766.

22*a*. MIVART, ST. G., and CLARKE, R. "On the Sacral Plexus and Sacral Vertebræ of Lizards and other Vertebrata." 'Linn. Soc. Trans.,' 2nd Series (Zool.), vol. 1, p. 513.

23. NITSCH. 'Pterylography.' Ray Society, 1867.

24. OWEN, R. 'Memoirs on the Extinct Wingless Birds of New Zealand.' London, 1879.
    - *a.* "On the *Apteryx australis,*" p. 1. 'Zool. Soc. Trans.,' vol. 2, p. 257; vol. 3, p. 277.
    - *b.* "On the *Apteryx australis* (Brain and Nerves)," p. 321. 'Zool. Soc. Trans.,' vol. 7, p. 381.
    - *c.* "On the *Apteryx australis* (Mandibular and Hyoidean Muscles)," p. 334. 'Zool. Soc. Trans.,' vol. 7, p. 392.

25. *Id.* 'On the Anatomy of Vertebrates,' vol. 2. London, 1866.

26. PARKER, T. J. "On the Skeleton of *Notornis mantelli.*" 'New Zealand Inst. Trans.,' vol. 14 (1881), p. 245.

27. *Id.* 'Zootomy.' London, 1884.

28. *Id.* "(Second)* Preliminary Note on the Development of *Apteryx.*" 'Roy. Soc. Proc.,' vol. 43, p. 482.

---

* The so-called "Preliminary Note on the Development of the Skeleton of the *Apteryx,*" is merely an unrevised extract from my rough note book, and was not intended for publication. I am, also, not

29. *Id.* "On the Nomenclature of the Brain and its Cavities." 'Nature,' vol. 35 (1886), p. 208.
30. Parker, W. K. "On the Structure and Development of the Skull in the Ostrich Tribe." 'Phil. Trans.,' 1865, p. 113.
31. *Id.* "On the Structure and Development of the Skull of the Common Fowl." 'Phil. Trans.,' 1866, p. 755.
32. *Id.* "On the Structure and Development of the Skull in the Pig." 'Phil. Trans.,' 1873, p. 289.
33. *Id.* "On the Structure and Development of the Skull in the Lacertilia." 'Phil. Trans.,' 1879, p. 595.
34. *Id.* "On the Structure and Development of the Skull in the Crocodilia." 'Zool. Soc. Trans.,' vol. 11, p. 263.
35. *Id.* "Report on the Development of the Green Turtle." '*Challenger* Reports (Zoology),' vol. 1.
36. *Id.* "On the Structure and Development of the Skull of Birds." 'Linn. Soc. Trans.,' 2nd Ser. (Zool.), vol. 1, p. 99.
37. *Id.* "On the Morphology of Birds." 'Roy. Soc. Proc.,' vol. 42, p. 52.
38. *Id.* "On the Vertebral Chain of Birds." 'Roy. Soc. Proc.,' vol. 43, p. 465.
39. *Id.* "On the Remnants or Vestiges of Amphibian and Reptilian Structures found in the Skull of Birds." 'Roy. Soc. Proc.,' vol. 43, p. 397.
40. *Id.* "On Secondary Carpals, Metacarpals, and Digital Rays in the Wings of existing Carinate Birds." 'Roy. Soc. Proc.,' vol. 43, p. 322.
41. *Id.* "On the Structure and Development of the Wing in the Common Fowl." 'Phil. Trans.,' B, vol. 179 (1888), p. 385.
42. *Id.* "On the Presence of Claws in the Wings of the Ratitæ." 'Ibis,' 5th Series, vol. 6, p. 124.
43. *Id.* 'On the Structure and Development of the Shoulder Girdle and Sternum.' Ray Society. 1868.
44. Parker, W. K., and Bettany, G. T. 'Morphology of the Skull.' London, 1877.
45. Potts, T. H. "Notes on a New Species of *Apteryx*." 'New Zealand Inst. Trans., vol. 4 (1871), p. 204.
46. *Id.* "On the Birds of New Zealand." 'New Zealand Inst. Trans.,' vol. 5 (1872), p. 187.
47. Rabl-Rückhard, H. "Das gegenseitige Verhältniss der Chorda, Hypophysis, und des mittleren Schädelbalkens bei Haifischembryonen, &c." 'Morphol. Jahrb.,' 6 (1880), p. 535.
48. Rolleston, G., and Jackson, W. H. 'Forms of Animal Life.' 2nd. Ed. Oxford, 1888.

responsible for the figures in the actual (so-called Second) Preliminary Note, which have the sizes incorrectly given.

49. Selenka, E. Bronn's 'Thierreich'; Aves.
50. Sutton, J. B. 'Ligaments; their Nature and Morphology.' London, 1887.
51. Watson, Morrison. 'Report on the Anatomy of the Spheniscidæ.' '*Challenger* Reports (Zoology),' vol. 7.
52. Wiedersheim, R. 'Lehrbuch der Vergl. Anatomie.' 2te. Aufl. Jena, 1886.
53. *Id.* 'Grundriss der Vergl. Anatomie.' 2te. Aufl. 1888.
54. Wray, R. S. "On Some Points in the Morphology of the Wings of Birds." 'Zool. Soc. Proc.,' 1887, p. 343.
55. Yarrell, W. "Description, &c., of the *Apteryx australis* of Shaw." 'Zool. Soc. Trans.,' vol. 1, p. 71.

Description of Plates 3–19.

The scale of enlargement is given on the figures themselves.

In plates dealing with the skeleton cartilaginous parts are coloured green and cartilage bones brown; membrane bones are uncoloured or (in sections) black; prochondral tissue is darkly shaded.

A. External Form.

References.

All.	Allantois (in outline).
Au.	Auditory sac.
Claw.	Terminal claw of wing.
Clo.Ap.	Cloacal aperture.
Cl. 1–4.	Visceral clefts.
Cubit. 1.	First cubital remex.
Dien.	Diencephal.
Dors.Pt.	Dorsal pteryla.
Fem.Pt.	Femoral pteryla.
F.L.	Fore-limb.
Fr.Na.P.	Fronto-nasal process.
H.L.	Hind-limb.
Ht.	Heart.
Hum.Pt.	Humeral pteryla.
Hy.	Hyoid fold.
Inf.Al.Apt.	Lower wing space.
Lat.Apt.	Lateral apterium.
Mesen.	Mesencephal.
Mes.Som. 16 *and* 28.	16th and 28th mesoblastic somites.
Meten.	Metencephal.
Mid.dig.	Mid-digital remex.
Mn.	Mandibular fold.
Mtcp.	Metacarpal remiges.
Mth.	Mouth.
Na.	External nasal aperture.
Nch.	Notochord.
Operc.	Operculum.
Prosen.	Prosencephal.
Pr.Ptgm.	Pre-patagium.
Pt.Ptgm.	Post-patagium.
S.Mx.P.	Superior maxillary process.
Som.Stk.	Somatic stalk.
Tect.maj.	Tectrices majores.
Upg.	Uropygium.
Vent.Apt.	Ventral apterium.
1–4.	Digits of manus or pes.

Plate.	Fig.	Stage.	Species.	
3	1	A	*australis*	Entire embryo from the right side
	2	B	,,	,, ,, ,, ,, ,,
	3	C	,,	,, ,, ,, left ,,
	4	,,	,,	The head, obliquely from beneath
	5	D	*oweni*	Entire embryo from the left side. The heart is exposed by rupture of the body wall
	6	E	,,	Entire embryo from the left side. Heart exposed by rupture of body wall
	7	,,	,,	Pes, dorsal aspect
	8	F	,,	Entire embryo from the left side
	9	,,	,,	Fore-limb, dorsal (external) aspect
	10	G	*australis*	Entire embryo from the right side
	11	,,	,,	Caudal extremity
	12	I	,,	Embryo from the left side with the feathers removed
	13	,,	,,	Left wing, ventral (inner) aspect
	14	Adult	*bulleri*	Right wing, dorsal (outer) aspect
	15	,,	,,	,, ,, ventral (inner) ,,
	16	,,	,,	Barbule of a wing-feather, showing curved barbicels

B. SECTIONS OF STAGES A, B, AND C.

References.

Au.	Auditory capsule.
Au.C.	Auditory capsule.
Aula.	Cavity of basi-cerebrum.
Bas.Art.	Basilar artery.
Bas.Crb.	Basi-cerebrum, or median portion of secondary fore-brain.
Bs.Opt.	Basi-opticus, or mid-ventral portion of mid-brain.
Br. 1–3.	Branchial folds.
Cent.	Rudiment of centrum.
Cl. 1–5.	Visceral clefts.
Cl.Ap.	Cloacal aperture.
Cœl.	Cœlome.
D.Ao.	Dorsal aorta.
Di.Cœ.	Diacœle (3rd ventricle).
Epen.	Epencephal (cerebellum).
f.	Fissure between mesoblastic somites.
F.L.	Fore-limb.
For.Monro.	Foramen of MONRO.
Fr.Na.P.	Fronto-nasal process.
H.L.	Hind-limb.
Hy.	Hyoid fold.
Inf.	Infundibulum.
Int.Car.	Internal carotid.
Iter.	Iter a tertio ad quartum ventriculum.
Jug.V.	Jugular vein.
Mes.neph.	Mesonephros.
Lam.term.	Lamina terminalis.
Mn.	Mandibular fold.
M.Pl.	Muscle plate.
Ms.cœ.	Mesocœle (cavity of mid-brain).
Mt.cœ.	Metacœle (4th ventricle).
Mth.	Mouth.
My.	Myelon.
Na.	Nasal sac.
Nch.	Notochord.
Nv. 3, 5, 10.	Oculomotor, trigeminal, and vagus nerves.
Operc.	Operculum.
Opt.cœ.	Optocœle (cavity of optic lobe).
Opten.	Optencephal (optic lobe).
Opt.ves.	Primary optic vesicle.
Pa.Ch.	Parachordal plate.
Pin.	Pineal body.
Pr.Ch.	Prochordal plate.
Pr.Pin.Divert.	Pre-pineal diverticulum.
Prs.cœ.	Prosocœle (lateral ventricle).
Pty.	Pituitary body.
S.Mx.P.	Superior maxillary process.
Sp.Gn.	Spinal ganglion.
Tr.	Trabecula.
V.Ao.	Ventral aorta.

Plate.	Fig.	Stage.	Species.	
4	17	A	*australis*	Sagittal section of head through median plane
	18	,,	,,	Pineal region of same section enlarged
	19	,,	,,	Part of 20th section laterad of median plane
	20	,,	,,	,, 30th ,, ,, ,,
	21	,,	,,	,, 40th ,, ,, ,,
	22	B	,,	Horizontal section of head, level of diacœle
	23	,,	,,	,, ,, ,, ,, eyes
	24	,,	,,	,, ,, ,, ,, pituitary body
	25	,,	,,	,, ,, ,, ,, nasal aperture
	26	,,	,,	Transverse ,, ,, ,, mandibular fold
	27	,,	,,	,, ,, ,, ,, hyoid fold
	28	,,	,,	,, ,, ,, ,, operculum
	29	,,	,,	,, ,, ,, ,, 2nd visceral cleft
	30	,,	,,	,, ,, ,, ,, 3rd visceral cleft
	31	,,	,,	,, ,, trunk ,, fore-limbs
	32	,,	,,	,, ,, ,, ,, hind-limbs
	33	,,	,,	Horizontal ,, ,, ,, notochord
5	34	C	,,	,, ,, head ,, diacœle
	35	,,	,,	,, ,, ,, ,, eyes
	36	,,	,,	,, ,, ,, ,, ,,
	37	,,	,,	Transverse ,, ,, ,, superior maxillary process
	38	,,	,,	,, ,, ,, ,, mandibular fold
	39	,,	,,	,, ,, ,, ,, hyoid fold
	40	,,	,,	,, ,, ,, ,, ,,
	41	,,	,,	,, ,, ,, ,, operculum and 2nd visceral cleft
	42	,,	,,	,, ,, ,, ,, ,, ,, 3rd visceral cleft
	43	,,	,,	,, ,, trunk ,, hind-limbs
	44	,,	,,	Horizontal ,, ,, ,, notochord

C. GRAPHIC REPRESENTATIONS OF RATE OF GROWTH.

Plate.	Fig.	
6	45	Diagram showing the relative dimensions of various regions of the body in the different stages, the length of the vertebral column being taken as a standard
7	46	Diagram showing curve of growth of the entire head, the brain case, and the beak, expressed as percentages of the vertebral column
	47	Diagram showing curves of growth of the ilium, sternum, scapula, and coracoid: vertebral column = 100
	48	Diagram showing curves of growth of entire fore-limb, brachium, antebrachium, and manus: vertebral column = 100
	49	Diagram showing curve of growth of entire hind-limb, femur, crus, tarso-metatarsus, and third digit: vertebral column = 100

D. The Skull.

References.

a.	Process of ectoethmoid.
A.A.Trb.	Anterior accessory turbinal.
a.bcr.fo.	Anterior basicranial fontanelle.
A.Trb.	Anterior turbinal.
Al.Sph.	Alisphenoid.
Ang.	Angular.
Ant.Hgh.	Antrum of Highmore.
Ant.Na.	Anterior nares.
Art.	Articular.
Ary.	Arytenoid cartilage.
A.S.C.	Anterior semicircular canal.
Au.C.	Auditory capsule.
Bas.Art.	Basilar artery.
B.Br.	Basibranchial.
B.Hy.	Basihyal.
B.Oc.	Basioccipital.
B.ptg.pr.	Basipterygoid process.
b.ptg.pr.	Facet on pterygoid for articulation of ditto.
B.Sph.	Basisphenoid.
B.Tmp.	Basitemporal.
C.Br.	Cerato-branchial.
C.Hy.	Cerato-hyal.
C.Hy.'	Prochondral rudiment of ditto.
Cn. 1 *and* 2.	Internal and external condyles of quadrate.
Col.	Columella auris.
Cor.	Coronary.
Cp.Str.	Corpus striatum.
cr.fa.c.	Craniofacial cavity.
Dent.	Dentary.
Dent.'	Fibrous rudiment of ditto.
Di.cœ.	Diacœle (3rd ventricle).
Dors.sell.	Dorsum sellæ.
d.pr.	Descending process of nasal or of frontal.
E.Br.	Epibranchial.
Ec.Eth. 1–5.	The five regions of the ectoethmoid.
E.St.	Extra-stapedial.
Eth.Pr.Sph.	Ethmo-presphenoid bone.
Eus.T.	Eustachian tube or its bony canal.
Ex.Col.	Extra-columella.
Ex.oc.	Exoccipital.
Ext.Aud.M.	External auditory meatus.
flc.f.	Floccular fossa.
f.ov.	Fenestra ovalis.
Fr.	Frontal.
f.rot.	Fenestra rotunda.
H.S.C.	Horizontal semicircular canal.
Int.Car.	Internal carotid or its foramen.
Inf.	Infundibulum.
I.St.	Infra-stapedial.
Ja.C.	Jacobson's cartilage.
Ju.	Jugal.
ju.pr.	Jugal process of maxilla.
Lac.	Lacrymal.
Lac.D.	Lacrymal duct.
Lac.Gl.	Lacrymal gland.
lac.for.	Lacrymal foramen.
m.bcr.fo.	Middle basicranial fontanelle.
Mck.C.	Meckel's cartilage.
M.Eth.	Mesethmoid.
M.Pter.	Pterygoid muscle.
M.Temp.	Temporal muscle.
Mth.	Mouth.
M.Trb.	Middle turbinal.
Mx.	Maxilla.
Na.	Nasal.
n.a.	Foramen for nutrient artery.
na.pr.	Nasal process of premaxilla or of frontal.
Na.Trb.	Naso-turbinal.
Nch.	Notochord.
Nv. I.–XII.	Cerebral nerves or their foramina.
Nv. V^{1-3}.	The three divisions of the trigeminal or their foramina.
Nv. $V^{1\,a\ and\ b}$.	The two rami of the orbito-nasal nerve.
Oc.cn.	Occipital condyle.
Oc.for.	Occipital foramen.
Olf.fos.	Olfactory fossa.
Olf.sac.	Olfactory sac.
Op.Ot.	Opisthotic.
orb.pr.	Orbital process of frontal or of quadrate.
Orb.Sph.	Orbito-sphenoid.
o.sph.pr.	Orbito-sphenoid process of frontal.
ot.pr.	Otic process of quadrate.
Pa.	Parietal.
Pa.Ch.	Parachordal cartilage.
Pal.	Palatine.
pal.pr.	Palatine process of premaxilla or of maxilla.
pa.oc.pr.	Paroccipital process.
p.bcr.fo.	Posterior basicranial fontanelle.
Pect.	Pecten.
Pmx.	Premaxilla.
Pmx.'	Fibrous rudiment of ditto.
pn.c.	Pneumatic cavity.
pn.f.	Pneumatic foramen.
Pr.Ch.	Prochordal cartilage.

Pr.Na.	Prenasal cartilage.
Pr.Ot.	Prootic.
pr.ot.	Facet on head of quadrate for articulation with ditto.
Prosen.	Prosencephal.
Prs.cœ.	Prosocœle (lateral ventricle).
Pr.Sph.	Presphenoid.
Pr.Sph.'	Paired moieties of ditto in Stage D.
Pr.Tmp.	Pretemporal wings.
Ptg.	Pterygoid.
Ptg.'	Fibrous rudiment of ditto.
Pt.Na.	Posterior nares.
P.Trb.	Posterior turbinals.
Pty.	Pituitary body.
Pty.F.	Pituitary fossa.
Pty.ped.	Pituitary pedicle.
Qu.	Quadrate.
Qu.(orb.pr.)	Orbital process of ditto.
Qu. (ot.pr.).	Otic process of ditto.
qu.	Facet for articulation of ditto on pterygoid or on quadrato-jugal.
qu.^{1}	Ditto on prootic.
qu.^{2}	Ditto on alisphenoid.
qu.^{3}	Ditto on squamosal.
Qu.Ju.	Quadrato-jugal.
Qu.Ju.'	Fibrous rudiment of ditto.
r.	Ridge of parachordal.
Rhinen.	Rhinencephal.
Rost.	Rostrum.
S.Ang.	Supra-angular.
Scl.	Sclerotic.
S.Oc.	Supra-occipital.
S.orb.F.	Superior orbital fontanelle.
Spl.	Splenial.
S.St.	Supra-stapedial.
Sq.	Squamosal.
Sq.'	Fibrous rudiment of ditto.
sq.	Facet for ditto on head of quadrate.
tg.pr.	Tegminal process.
Thy.	Thyroid cartilage.
Tr.	Trabecula.
Trch.	Trachea.
Tymp.C.	Tympanic cavity.
Tymp.M.	Tympanic membrane.
V.A.Trb.	Ventral accessory turbinal.
Vo.	Vomer.
x.	Transverse commissure between trabeculæ, separating anterior and middle basicranial fontanelles.
y.	Ditto between parachordals, separating middle and posterior basicranial fontanelles.
zyg.pr.	Zygomatic process of squamosal.

Plate.	Fig.	Stage.	Species.	
8	50	K	*bulleri*	Entire skull, dorsal aspect
	51	„	„	„ „ ventral „
	52	„	„	„ „ from left side
	53	„	„	„ „ „ behind
	54	„	„	Mandible, dorsal
	55	„	„	„ ventral
	56	„	„	Entire skull, sagittal section
	57	„	„	The turbinals of the right side, mesial aspect, exposed by removal of mesethmoid
	58 to 74	„	*australis*	The separate membrane bones
9	75	„	„	Chondrocranium, dorsal
	76	„	„	„ ventral
	77	„	„	„ left side
	78	„	„	Dorsal wall of tympanic cavity

Plate.	Fig.	Stage.	Species.	
9	79	K	*australis*	Quadrate, mesial aspect
	80	,,	,,	Mandible after removal of membrane bones, ventral
	81	,,	,,	Columella auris, posterior aspect
	82	,,	,,	Tongue bone, dorsal
	83	,,	,,	Horizontal section of turbinals
	84	,,	,,	,, ,, ,, further ventrad
	85	D	*oweni*	Entire skull, left side
	86	,,	,,	Chondrocranium, sagittal section restored from sections
	87	,,	,,	Columella auris
	88	,,	,,	Transverse section of head, anterior olfactory region
	89	,,	,,	,, ,, ,, level of posterior nares
	90	,,	,,	,, ,, ,, ,, eyes
	91	,,	,,	,, ,, ,, ,, optic nerves
	92	,,	,,	,, ,, ,, ,, basipterygoid processes
	93	,,	,,	,, ,, ,, ,, pituitary pedicle
	94 95	,,	,,	,, ,, ,, ,, parachordals
10	96	E	,,	Entire skull from left side, restored from sections
	97	,,	,,	Chondrocranium, dorsal, from a dissection
	98	,,	,,	,, sagittal section, restored from sections
	99	,,	,,	Columella auris, restored from sections
	100	,,	,,	Sagittal section of head, through olfactory chamber
	101	,,	,,	Median sagittal section through basis cranii
	102	,,	,,	Sagittal section of ditto, slightly laterad of median plane
	103	,,	,,	Diagram of basis cranii from above, showing probable relations of parachordals and trabeculæ
	104	F	,,	Entire skull, from left side, from a dissection
	105	,,	,,	Chondrocranim, dorsal ,, ,,
	106	,,	,,	,, ventral ,, ,,
	107	,,	,,	,, from left side ,, ,,
	108	,,	,,	,, sagittal section, restored from previous dissections and from sections
	109	,,	,,	Pituitary region of ditto, with connective tissue removed
	110	,,	,,	Tongue-cartilage (first branchial arch)
	111	,,	,,	Median sagittal section of basis cranii
	112	,,	,,	Sagittal section of basis cranii, 0·2 mm. laterad of median plane
	113	,,	,,	Transverse section of head, anterior olfactory region
	114	,,	,,	,, ,, ,, part of ditto, showing characters of olfactory sac
	115	,,	,,	,, ,, ,, anterior turbinal region
	116	,,	,,	,, ,, ,, presphenoidal region
	117	,,	,,	,, ,, ,, level of basipterygoid processes
	118	,,	,,	,, ,, ,, ,, dorsum sellæ
	119	,,	,,	,, ,, ,, ,, tympanic cavity

Plate.	Fig.	Stage.	Species.		
11	120	G	*oweni*	Entire skull, dorsal	from dissections, membrane bones added from sections
	121	,,	,,	,, ,, ventral	
	122	,,	,,	,, ,, left side	
	123	,,	,,	Chondrocranium, dorsal	from dissections corrected by sections
	124	,,	,,	,, ventral	
	125	,,	,,	,, left side	
	126	,,	,,	,, sagittal section	
	127	,,	*australis*	Transverse section of head, anterior end of beak	
	128	,,	,,	,, ,, ,, level of anterior nares	
	129	,,	,,	,, ,, ,, ,, naso-turbinal	
	130	,,	,,	,, ,, mandible slightly caudad of preceding	
	131	,,	,,	,, ,, head, anterior turbinal region	
	132	,,	,,	,, ,, ,, level of posterior nares	
	133	,,	,,	,, ,, ,, ,, eyes	
	134	,,	,,	,, ,, ,, ,, pituitary pedicle	
	135	,,	,,	,, ,, ,, ,, anterior basicranial fontanelle	
	136	,,	,,	,, ,, ,, ,, optic nerves and basipterygoid processes	
	137	,,	,,	,, ,, ,, ,, pituitary body and internal carotid foramen	
12	138	,,	,,	,, ,, ,, just caudad of pituitary body	
	139	,,	,,	,, ,, ,, level of dorsum sellæ	
	140	,,	,,	,, ,, ,, ,, posterior basicranial fontanelle	
	141	,,	,,	,, ,, ,, ,, trigeminal foramen	
	142	,,	,,	,, ,, ,, ,, tympanic cavity	
	143	,,	,,	,, ,, ,, ,, condyloid foramen	
	144	,,	,,	,, ,, ,, ,, occipital foramen	
	145	,,	,,	,, ,, ,, ,, posterior end of auditory capsule	
	146	H	*bulleri*	Entire skull, dorsal	
	147	,,	,,	Portion of chondrocranium, dorsal	
	148	,,	,,	,, ,, ventral	
	149	,,	*oweni*	Transverse section of head, anterior end of beak	
	150	,,	,,	,, ,, ,, level of anterior nares	
	151	,,	,,	,, ,, ,, ,, naso-turbinal	
13	152	,,	,,	,, ,, ,, at junction of first and second portions of ectoethmoid	
	153 154	,,	,,	,, ,, ,, region of ventral accessory turbinal	
	155 156	,,	,,	,, ,, ,, ,, ,, and anterior accessory turbinals	
	157	,,	,,	,, ,, ,, ,, anterior and middle turbinals	
	158	,,	,,	,, ,, ,, level of eye	
	159	,,	,,	,, ,, ,, presphenoid region	
	160	,,	,,	,, ,, ,, anterior part of pituitary fossa	

Plate.	Fig.	Stage.	Species.	
13	161	H	*oweni*	Transverse section of head, level of anterior basicranial fontanelle
 14	162 163	„	„	„ „ „ posterior part of pituitary fossa
	164 165 166	„	„	„ „ „ through dorsum sellæ
	167	„	„	„ „ „ „ posterior basicranial fontanelle
	168 169 170	„	„	„ „ „ level of tympanic cavity
	171	„	„	„ „ „ „ occipital condyle
	172	I	*australis*	Chondrocranium, dorsal
	173	„	„	Sagittal section through basis cranii
	174	„	*bulleri*	„ „ „ „

E. Vertebral Column and Ribs.

References.

a.zyg.	Anterior zygapophysis.	*neur.*	Neuroid.
capit.	Head of rib.	*n.ost.*	Neurosteite.
c.chn.	Centrochondrite.	*n.sp.*	Neural spine.
Cd.	Caudal vertebræ.*	*Oc.cn.*	Occipital condyle.
Cor.	Coracoid.	*Od.*	Odontoid.
C.ost.	Centrosteite.	*parap.*	Parapophysis.
Cv.Th.Rb.	Rib of cervico-thoracic vertebra.	*pl.*	Pleuroid.
diap.	Diapophysis.	*pl.chn.*	Pleurochondrite.
Fe.	Femur.	*pl.ost.*	Pleurosteite.
Il.	Ilium.	*pt.atl.int.c.*	Post-atlantal intercentrum.
int.cent.	Intercentrum.	*pt.oc.int.c.*	„ occipital „
int.vert.for.	Intervertebral foramen.	*Pu.*	Pubis.
Isch.	Ischium.	*Pyg.*	Pygostyle.
Lb.	Lumbar vertebræ.	*Sc.*	Sacral vertebræ.
Lb.Sc.	Lumbo-sacral vertebræ.	*Scap.*	Scapula.
lg.	Ligament.	*St.*	Sternum.
My.	Myelon.	*Th.*	Thoracic vertebræ.
Nch.	Notochord.	*tuberc.*	Tubercle of rib.
n.c.su.	Neurocentral suture.	*Unc.*	Uncinates.

---

* These and the remaining vertebræ are numbered in order; the numbers in brackets give the position in the entire series.

Plate.	Fig.	Stage.	Species.		
15	175	K	*australis*	Atlas, cephalic aspect	
	176	„	„	„ caudal „	
	177	„	„	Axis, left side	
	178	„	„	„ ventral	
	179	„	„	„ sagittal section	
	180	„	„	3rd cervical, dorsal aspect	
	181	„	„	5th „ anterior aspect	
	182	„	„	„ „ posterior „	
	183	„	„	Cervico-thoracic, anterior aspect	
	184	„	„	1st thoracic „	
	185	„	„	2nd „ „	
	186	„	„	Syn-sacrum and caudal vertebræ, left side	
	187	„	„	„ „ „ ventral	
	188	„	„	Last four caudal vertebræ, left side	
	189	„	„	„ „ dorsal	
	190	„	*bulleri*	Caudal vertebræ, left side	
	191	D	*oweni*	Vertical section of 12th cervical vertebræ	
	192	„	„	„ „ 3rd thoracic „	
	193	„	„	„ „ 1st sacral „	
	194	E	„	Sagittal section of anterior cervical region, median	
	195	„	„	„ „ „ „ „ laterad of mesial plane	
	196	„	„	„ „ sacral region	
	197	„	„	„ „ posterior caudal region	
	198	G	„	Atlas, anterior	
	199	„	„	Axis „	
	200	„	„	„ left side	
	201	„	„	Thoracic vertebra, anterior	
	202	„	*australis*	1st sacral vertebra	Restored from sections
	203	„	„	Posterior caudal vertebræ	
	204	I	„	Post-cervical portion of vertebral column, with ribs, sternum, shoulder-girdle, and pelvis; left side	
	205	O	*oweni*	Syn-sacrum, left side	
	206	Adult	*australis*	Posterior caudal region, right side	
	207	„	*oweni*	„ „ „ sagittal section	

F. The Sternum.

References.

ant.lat.pr.	Anterior lateral process.	*Pl.ost.*	Pleurosteon.
Cor.	Coracoid.	*post.lat.pr.*	Posterior lateral process.
Cor.gr.	Coracoid groove.	*post.med.pr.*	,, median ,,
Cv.Th.Rb.	Cervico-thoracic rib.	*Scap.*	Scapula.
fo.	Fontanelle.	*St.*	Sternum.
Hu.	Humerus.	*Th.Rb.*, 1–4.	Thoracic ribs.
k.	Median ridge or vestigial keel.	*Unc.*	Uncinates.

Plate.	Fig.	Stage.	Species.	
16	208	Adult	*australis*	Sternum, ventral
	209	,,	,,	,, ,,
	210	,,	*haastii?*	,, ,,
	211	,,	*maxima* = *bulleri*	,, ,,
	212	,,	*bulleri*	,, ,,
	213	,,	,,	,, ,,
	214	,,	*oweni*	,, ,,
	215	,,	,,	,, ,,
	216	E	,,	,, with shoulder-girdle, anterior ribs, &c., left side
	217	F	,,	,, with anterior ribs, left side
	218	G	*australis*	,, ventral
	219	,,	,,	,, transverse section
	220	H	*bulleri*	,, ventral
	221	,,	*oweni*	,, ,,
	222	K	*australis*	,, ,,
	223	L	,,	,, ,,
	224	M	*oweni*	,, ,,

G. The Shoulder-Girdle.

References.

acr.	Acromial tuberosity.
acr.cor.	Acrocoracoid tuberosity.
Cor.	Coracoid.
Cor.fen.	Coracoid fenestra.
gl.	Glenoid cavity.
Pr.cor.	Procoracoid.
pr.cor.t.	Procoracoid tuberosity.
pr.cor.lig.	,, ligament.
Scap.	Scapula.
Sup.cor.for.	Supracoracoid foramen.

Plate.	Fig.	Stage.	Species.		
16	225	Adult	*maxima* =*bulleri*	Shoulder-girdle.	A. ventral, B. lateral aspect
	226	,,	*haastii ?*	,, ,,	,, ,, ,, ,, ,,
	227	,,	*australis*	,, ,,	,, ,, ,, ,, ,,
	228	,,	,,	,, ,,	,, ,, ,, ,, ,,
	229	,,	*bulleri*	,, ,,	,, ,, ,, ,, ,,
	230	,,	,,	,, ,,	,, ,, ,, ,, ,,
	231	,,	*oweni*	,, ,,	,, ,, ,, ,, ,,
	232	,,	,,	,, ,,	,, ,, ,, ,, ,,
17	233	E	,,	,, ,,	ventral
	234	F	,,	,, ,,	,,
	235	G	,,	,, ,,	,,
	236	,,	*australis*	,, ,,	two transverse sections
	237	H	*oweni*	,, ,,	ventral
	238	,,	*bulleri*	,, ,,	,,
	239	I	*australis*	,, ,,	,,
	240	K	,,	,, ,,	,,

H. The Fore-Limb.

References.

Cl.	Alar claw.
Cp.	Carpale.
Cp.Mtcp.	Carpo-metacarpus.
dist.	Distale.
dist. 1–3.	The separate distalia of early stages.
Hu.	Humerus.
Mtcp. 1-3.	The three metacarpals.
Phal. $2'$, $2''$, and $2'''$.	The phalanges of the second digit.
Phal. 3.	Phalanx of third digit.
Ra.	Radius.
ra.	Radiale.
ra.dist.	Radio-distale.
Ul.	Ulna.
ul.	Ulnare.

Plate.	Fig.	Stage.	Species.	
17	241	Adult	*australis*	Left manus, dorsal aspect
	242	"	*oweni*	" " " "
	243	"	"	" " " "
	244	"	"	" " " "
	245	"	*bulleri*	" " " "
	246	"	"	" " " "
	247	"	"	" " " "
	248	"	"	Right " " "
	249	"	"	Left " " "
	250	"	*haastii*	" " A. dorsal, B. palmar aspect
	251	"	" ?	" " dorsal aspect
	252	"	"	Right " " "
	253	"	*maxima* =*bulleri*	Left " " "
	254	E	*oweni*	Horizontal section of left fore-limb (combined figure)
	255	"	"	" " " " " " single section, further dorsad than the preceding
	256	F	"	" " " " manus (combined figure)
	257	G	*australis*	Left manus, dorsal aspect, restored from sections
	258 259	"	"	Single horizontal sections of left manus
	260	"	*oweni*	Horizontal section of left manus
	261	H	"	" " " " " combined figures
	262	"	*bulleri*	" " " " "
	263	I	"	" " " " "
	264	"	*australis*	" " " " "
18	265	K	"	Left fore-limb, dorsal (outer) aspect
	266	"	"	Horizontal section of left carpo-metacarpus
	267	"	*bulleri*	Left manus, dorsad aspect
	268	"	"	Horizontal section of left carpo-metacarpus
	269	L	*australis*	Left manus, dorsal aspect
	270	"	"	Horizontal section of left carpo-metacarpus
	271	"	*oweni*	Left manus, dorsal aspect
	272	M	*australis*	" " " "
	273	"	*oweni*	" " " "

I. THE PELVIS.

References.

actb.	Acetabulum.	*Pr.Il.*	Pre-ilium.
Ant.trch.	Antitrochanter.	*Pt.Il.*	Post-ilium.
Isch.	Ischium.	*Pu.*	Pubis.
Pect.pr.	Pectineal process.		

Plate.	Fig.	Stage.	Species.	
18	274	D	*oweni*	Left innominate, external aspect, restored from sections
	275	E	,,	,, ,, ,, ,, ,, ,, ,,
	276	F	,,	,, ,, ,, ,, ,, ,, ,,
	277	G	,,	,, ,, ,, ,, ,, ,, ,,
	278	L	*australis*	,, ,, ,, ,, ,, ,, ,,
	279	O	,,	,, ,, ,, ,, ,, ,, ,,

K. THE HIND-LIMB.

References.

asc.pr.	Ascending process of tibiale.	*Fib.*	Fibula.
cent. 1.	Preaxial centrale.	*fib.*	Fibulare.
cent. 2.	Postaxial ,,	*Mt.tsl.* 1–5.	Metatarsals.
dist.	Distale.	*Tib.*	Tibia.
Fe.	Femur.	*tib.*	Tibiale.

Plate.	Fig.	Stage.	Species.	
18	280	D	*oweni*	Left leg, dorsal aspect, reconstructed from sections
	281 282	,,	,,	Single horizontal sections of tarsus
	283	E	,,	Left leg, dorsal aspect, reconstructed from sections
	284	,,	,,	Horizontal section of tarsus
	285	F	,,	Right pes, dorsal aspect, reconstructed from sections
	286	,,	,,	Horizontal section of tarsus
	287	,,	,,	Vertical ,, ,,
	288	,,	,,	Horizontal ,, ,,
	289	G	,,	Left leg, dorsal aspect
	290	,,	*australis*	Horizontal section of tarsus
	291	,,	,,	,, ,, ,,
	292	Adult	*haastii ?*	Posterior (plantar) aspect of mesotarsal joint

L. Muscles of the Wing.

References.

ancon.	M. anconeus.
biceps.	M. biceps brachii.
brach.ant.	M. brachialis anticus.
brach.int.access.	M. brachialis anticus accessorius.
Cor.brach.sup.	M. coraco-brachialis superior.
Cor.brach.inf.	M. coraco-brachialis inferior.
Cp.Mtcp.	Carpo-metacarpus.
ext.carp.ul.	M. extensor carpi ulnaris.
ext.ind.prop.	M. extensor indicis proprius.
ext.metacarp.rad.brev.	M. extensor metacarpi radiatis brevis.
flex.carp.rad.	M. flexor carpi radialis.
flex.dig.prof.	M. flexor digitorum profundus.

flex.prof.int.	M. flexor profundus internus gallinaceorum.
Hu.	Humerus.
interos.dors.	M. interosseus dorsalis.
pect.maj.	M. pectoralis major.
pron.	M. pronator.
Ra.	Radius.
Subcl.	M. subclavius.
supin.	M. supinator.
teres.	M. teres.
triceps.	M. triceps brachii.
Ul.	Ulna.

Plate.	Fig.	Stage.	Species.	
19	293	Adult	*australis*	Muscles of the shoulder and wing, dorsal (external) aspect
	294	,,	,,	,, fore-arm and hand, palmar aspect
	295	,,	*bulleri*	,, ,, ,, dorsal ,,
	296	,,	,,	,, ,, ,, palmar ,,

M. The Brain and Eye.

References.

ant.com.	Anterior commissure.
ch.plx.	Choroid plexus.
corp.call.	Corpus callosum.
corp.stri.	Corpus striatum.
Bs.opt.	Basiopticus.
di.cœ.	Diacœle (third ventricle).
Dien.	Diencephal.
ep.cœ.	Epicœle (cerebellar ventricle).
Epen.	Epencephal (cerebellum).
floc.	Flocculus.
for.M.	Foramen of Monro.
inf.	Infundibulum.
lam.term.	Lamina terminalis.
Mesen.	Mesencephal.
Meten.	Metencephal (medulla oblongata).
Ms.cœ.& iter.	Mesocœle.
mt.cœ.	Metacœle (fourth ventricle).
Nv. II.–XII.	Cerebral nerves.

opt.chs.	Optic chiasma.
opt.cœ.	Optocœle (optic ventricle).
opt.com.	Optic commissure.
Opten.	Optencephal (optic lobe).
Opt.thal.	Optic thalamus.
Opt.ves.	Optic vesicle.
Pect.	Pecten.
ped crb.	Peduncle of cerebrum.
ped.crbl.	,, cerebellum.
Pin.	Pineal body.
post.com.	Posterior commissure.
Prosen.	Prosencephal (cerebral hemisphere).
Pr.Pin.Divertic.	Prepineal diverticulum.
prs.cœ.	Prosocœle (lateral ventricle).
Pty.	Pituitary body.
Rhinen.	Rhinencephal (olfactory lobe).
vel.int.	Velum interpositum.
Vlv.Vieus.	Valve of Vieussens.

Plate.	Fig.	Stage.	Species.	
19	297	Adult	*bulleri*	Entire brain, dorsal aspect
	298	,,	,,	,, ventral ,,
	299	,,	,,	,, left side
	300	,,	,,	Brain with hemispheres and cerebellum removed and right opto-cœle exposed
	301	,,	*australis*	Sagittal section of brain
	302	I	,,	Transverse section through diencephal
	303	,,	,,	,, ,, ,, mesencephal
	304	E	*oweni*	Brain from above: proso-, dia-, and opto-cœle exposed on left side
	305	,,	,,	Entire brain from left side
	306	F	,,	Brain from above: diacœle exposed on left side
	307	,,	,,	Sagittal section of brain
	308	G	*australis*	Entire brain, dorsal aspect } reconstructed from sections
	309	,,	,,	,, ,, left side }
	310	H	*oweni*	,, ,, ventral aspect
	311	I	*australis*	Portion of retina with pecten



T.J.P. ad nat. del.
M.F. Parker chr. lith.

APTERYX. External Characters.

West. Newman imp.

17 (× 22)

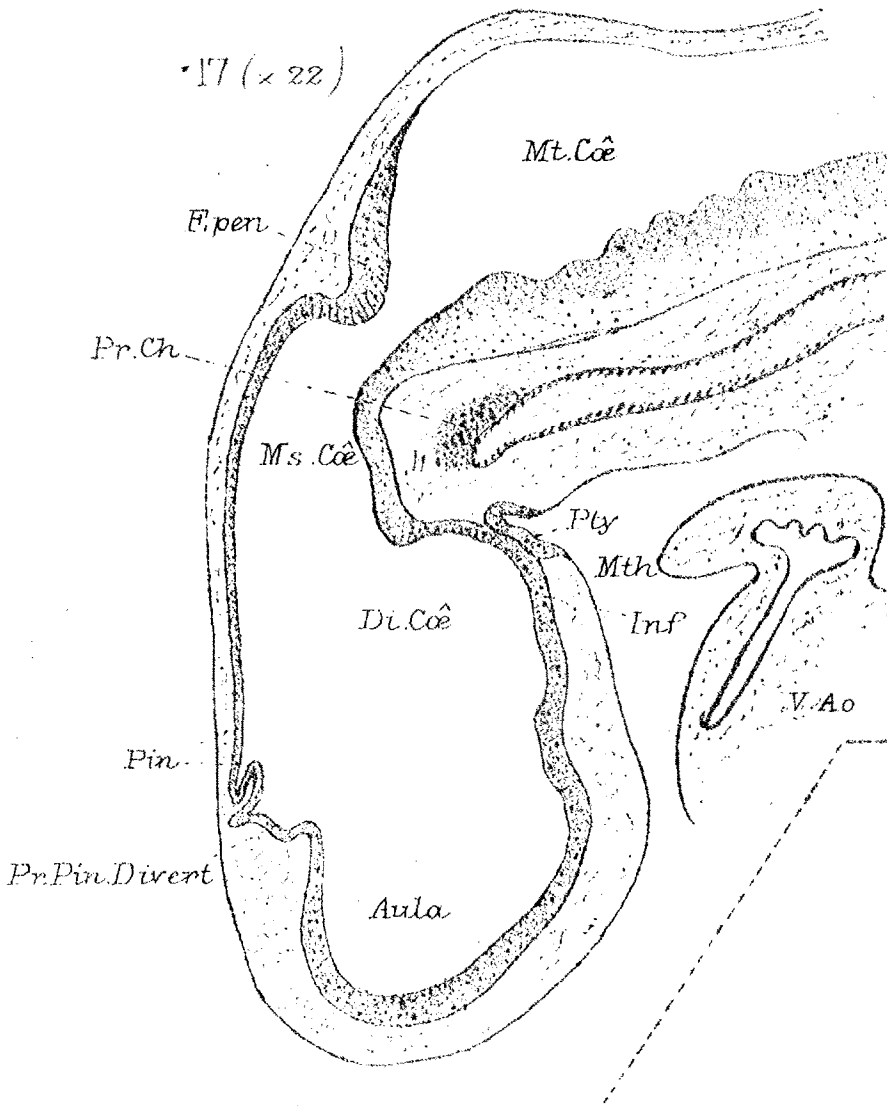

18 (× 150)

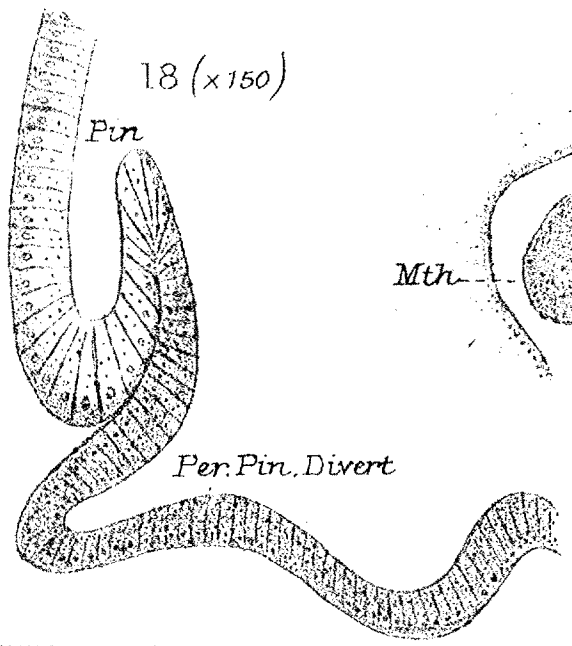

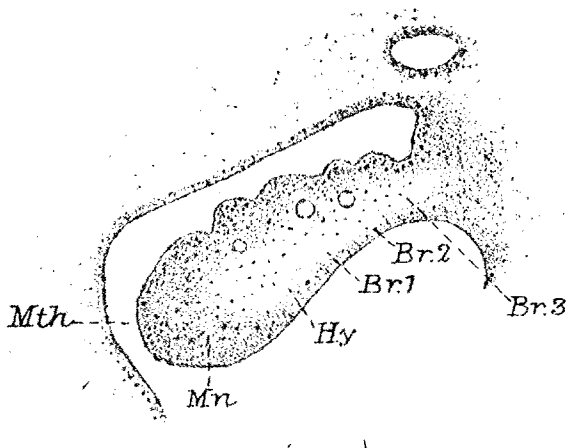

19 (× 22)

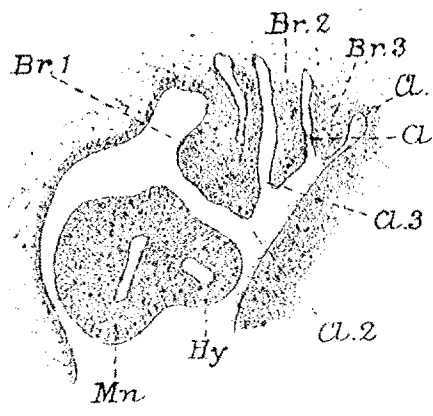

20 (× 22)

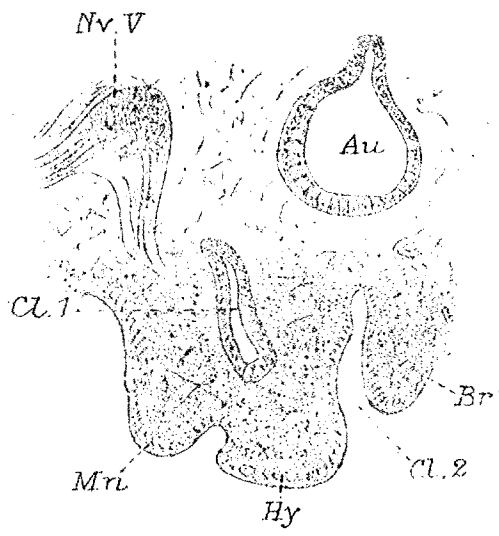

21 (× 22)

22 (× 22)

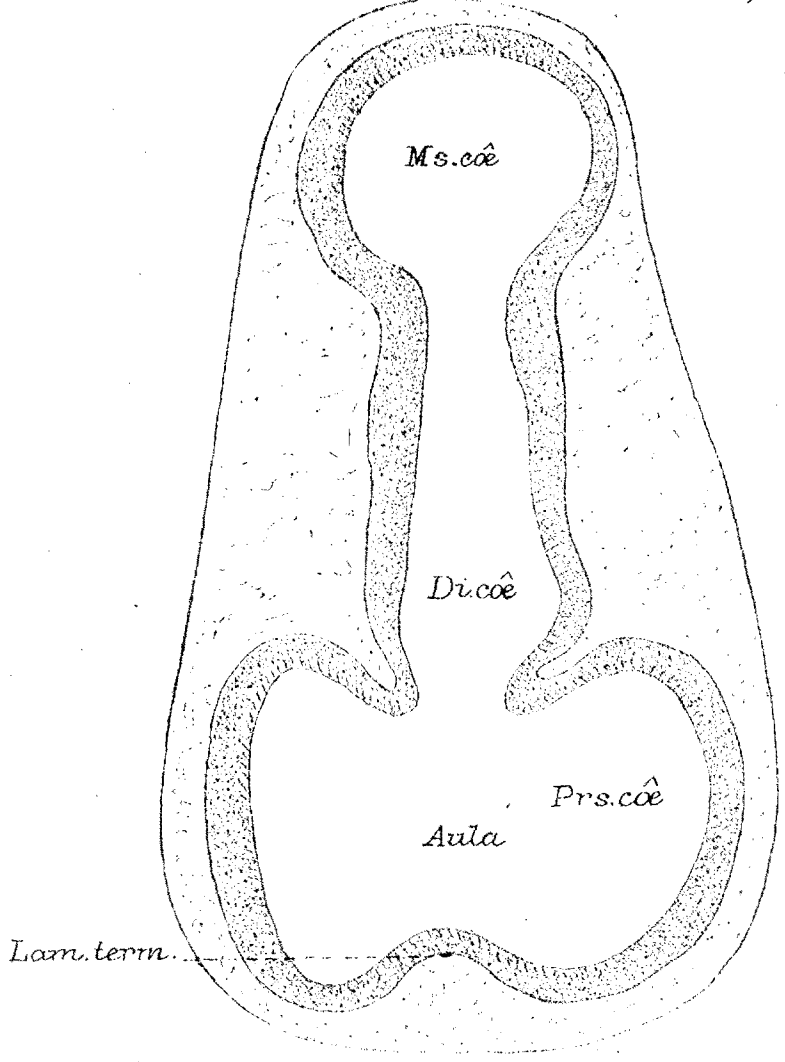

23 (× 22)

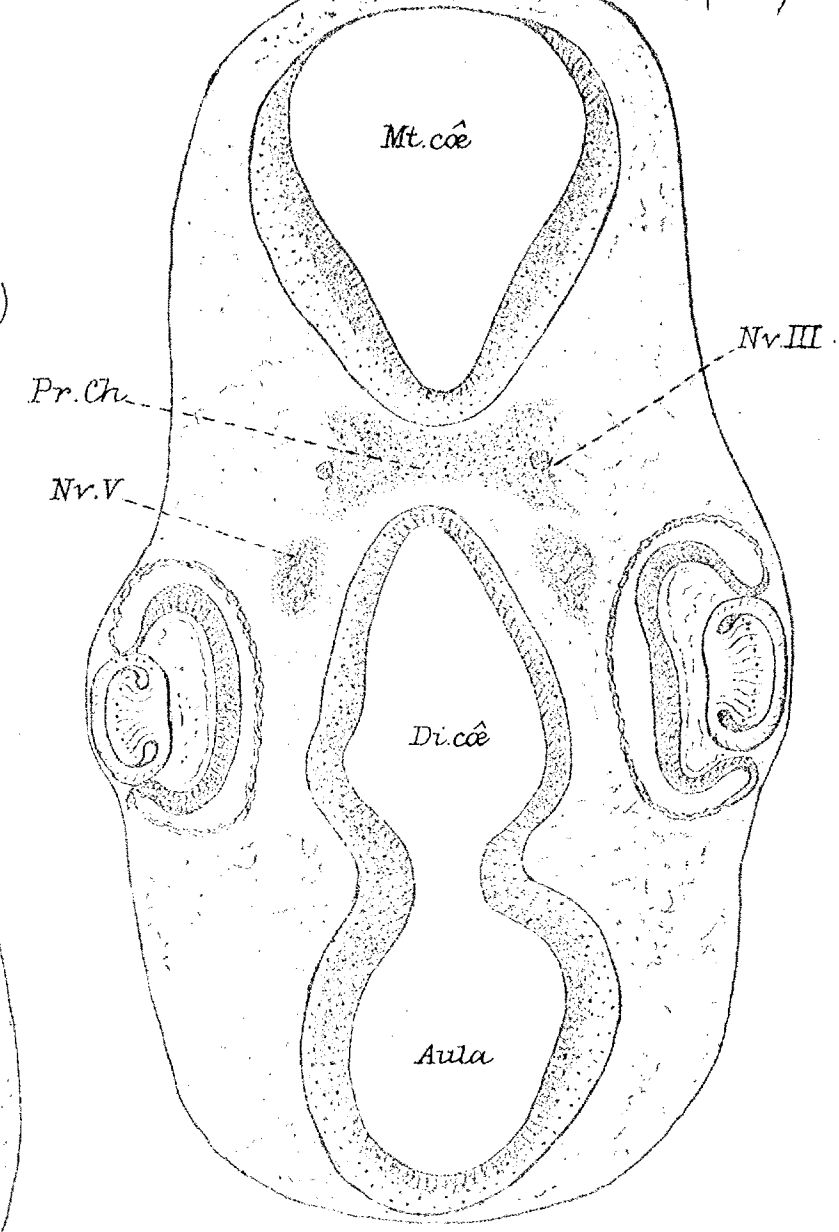

24 (× 22)

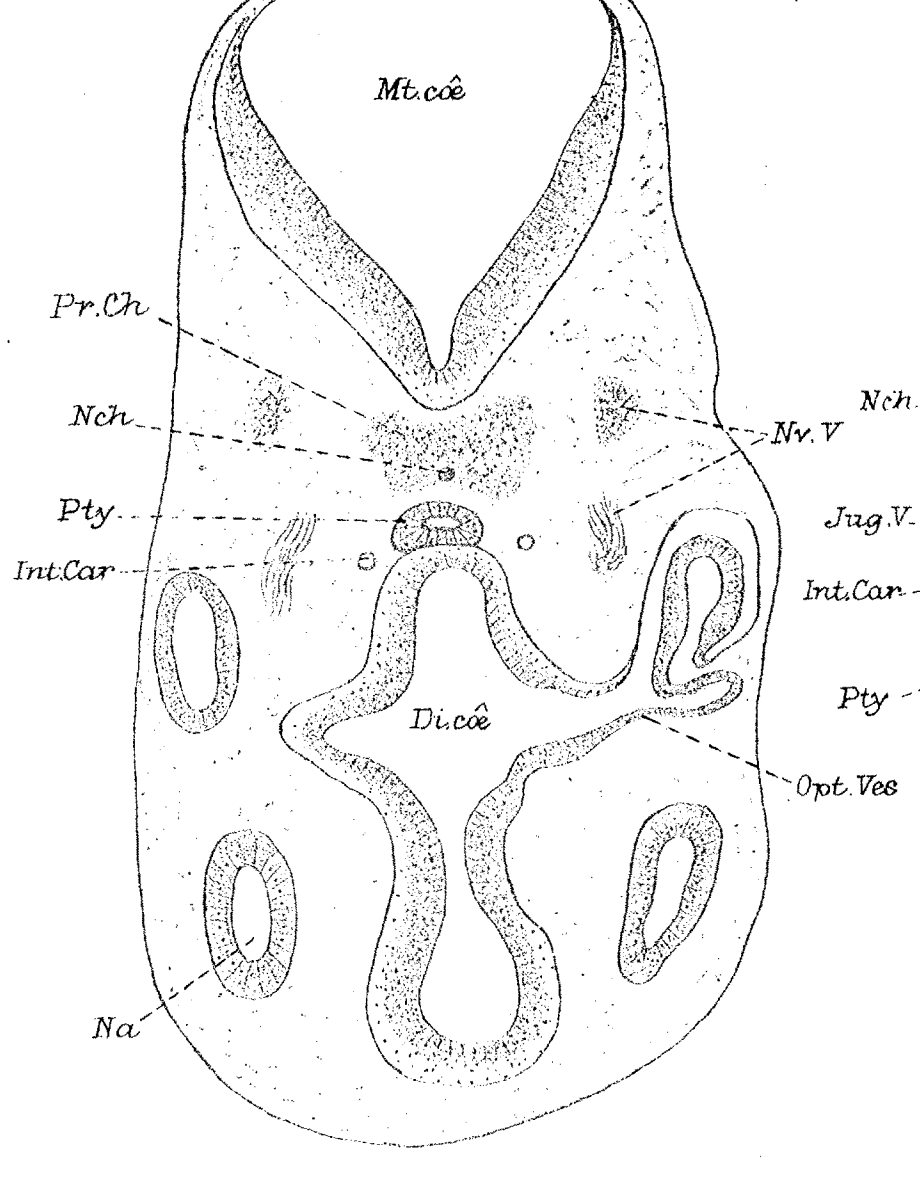

25 (× 22)

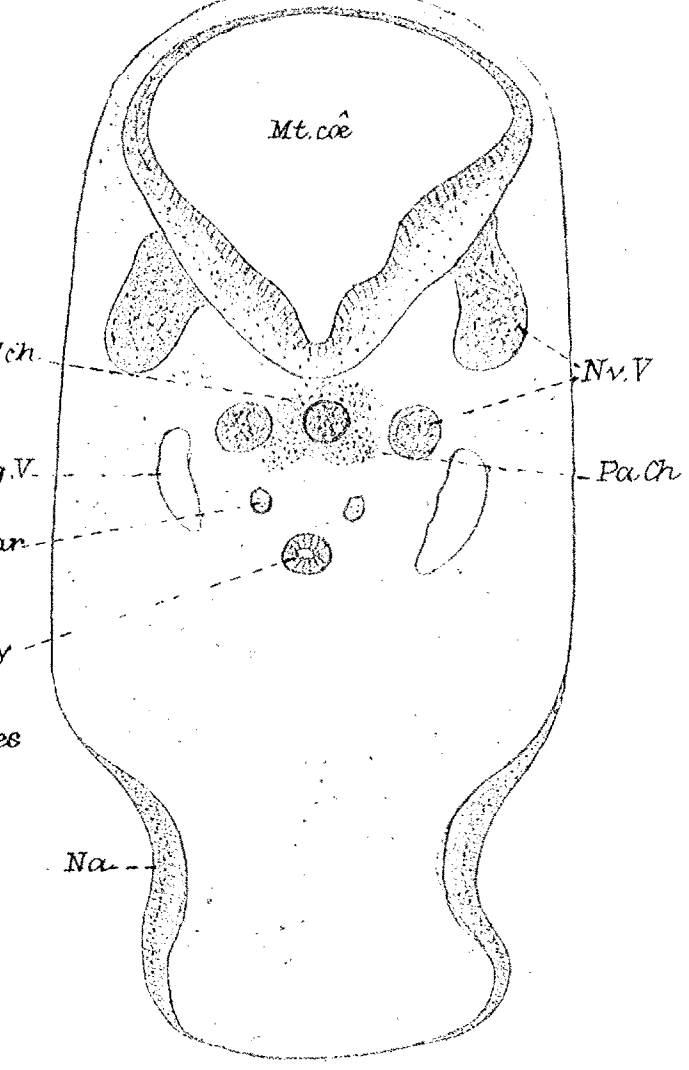

26 (× 22)

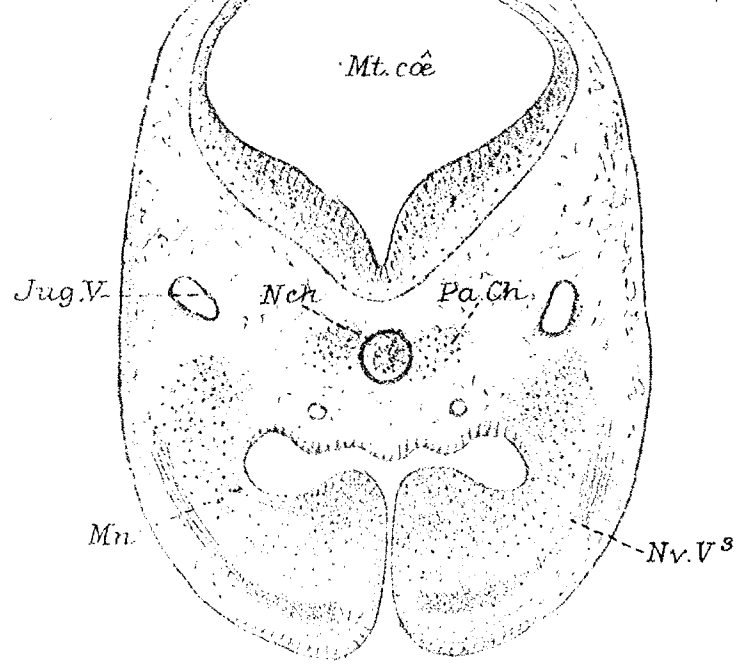

27 (× 22)

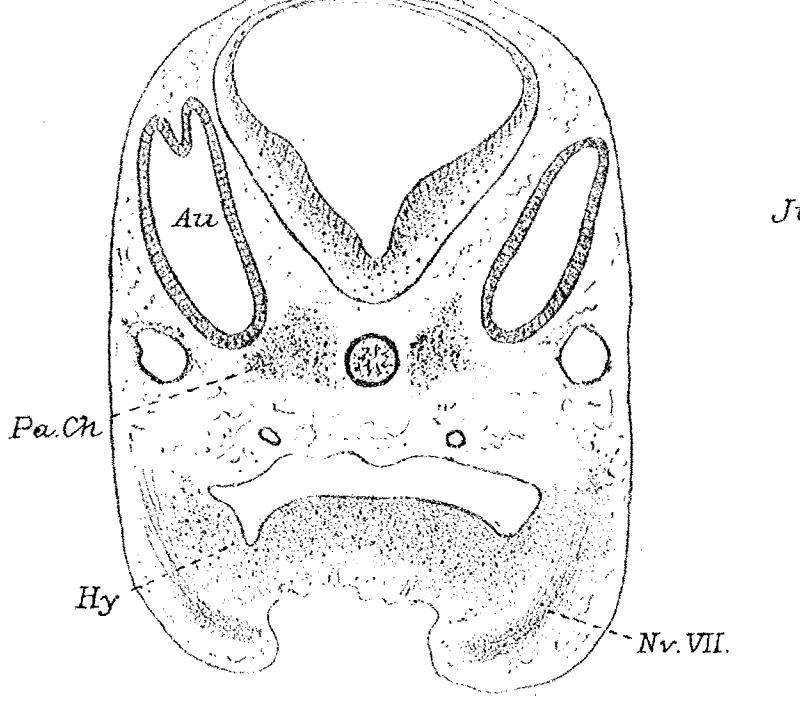

28 (× 22)

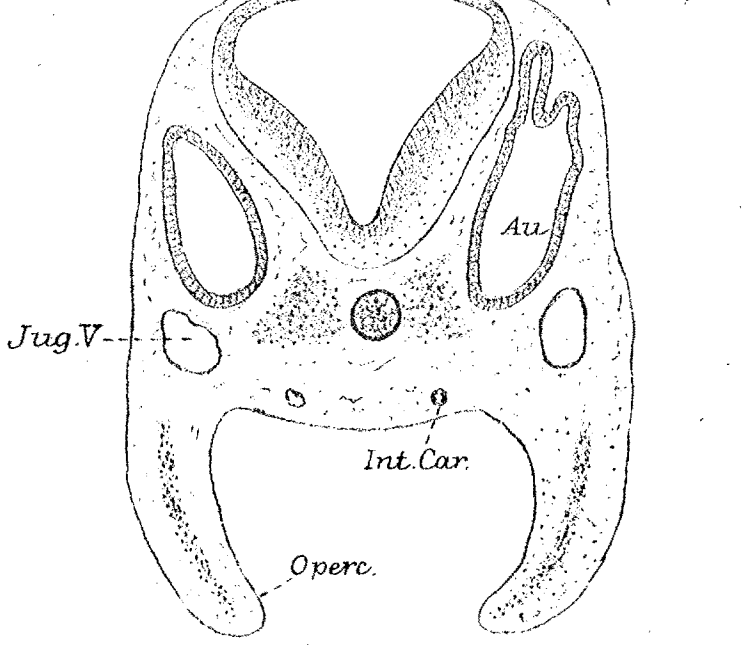

29 (× 22)

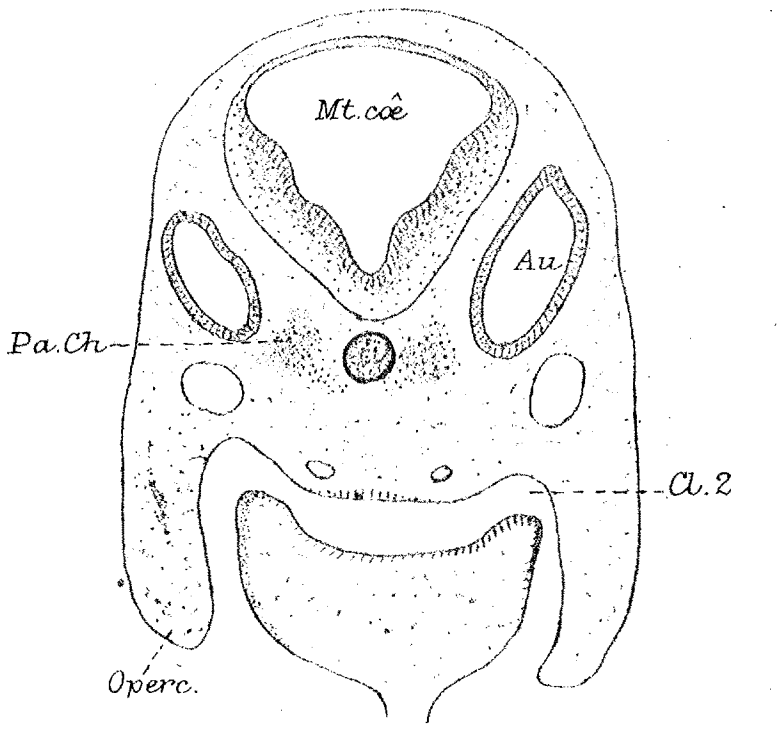

30 (× 22)

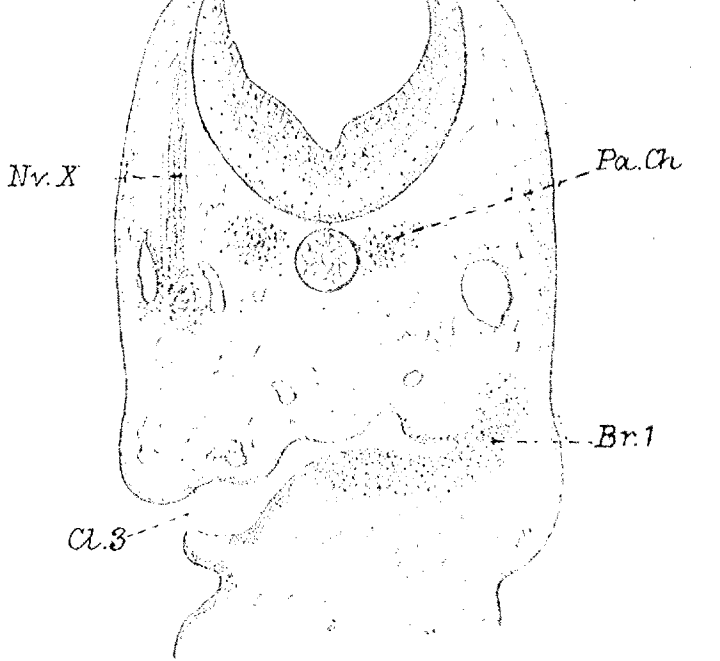

31 (× 22)

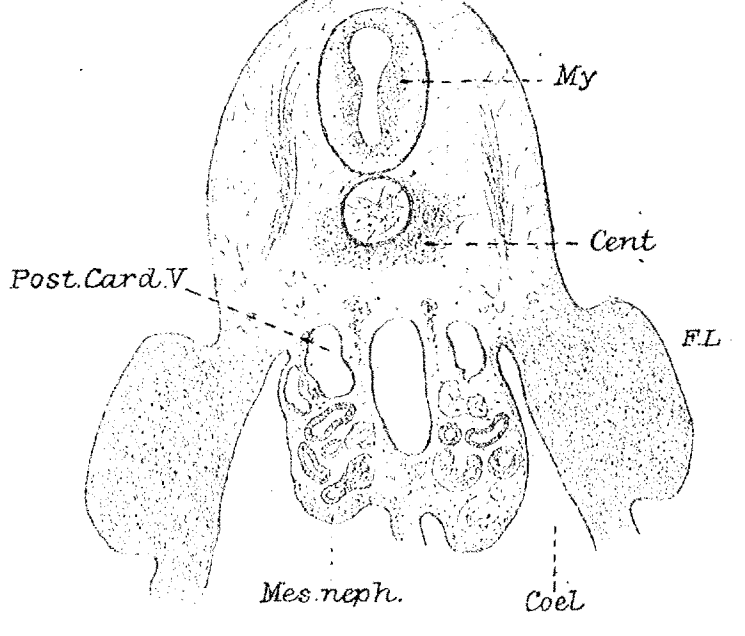

32 (× 22)

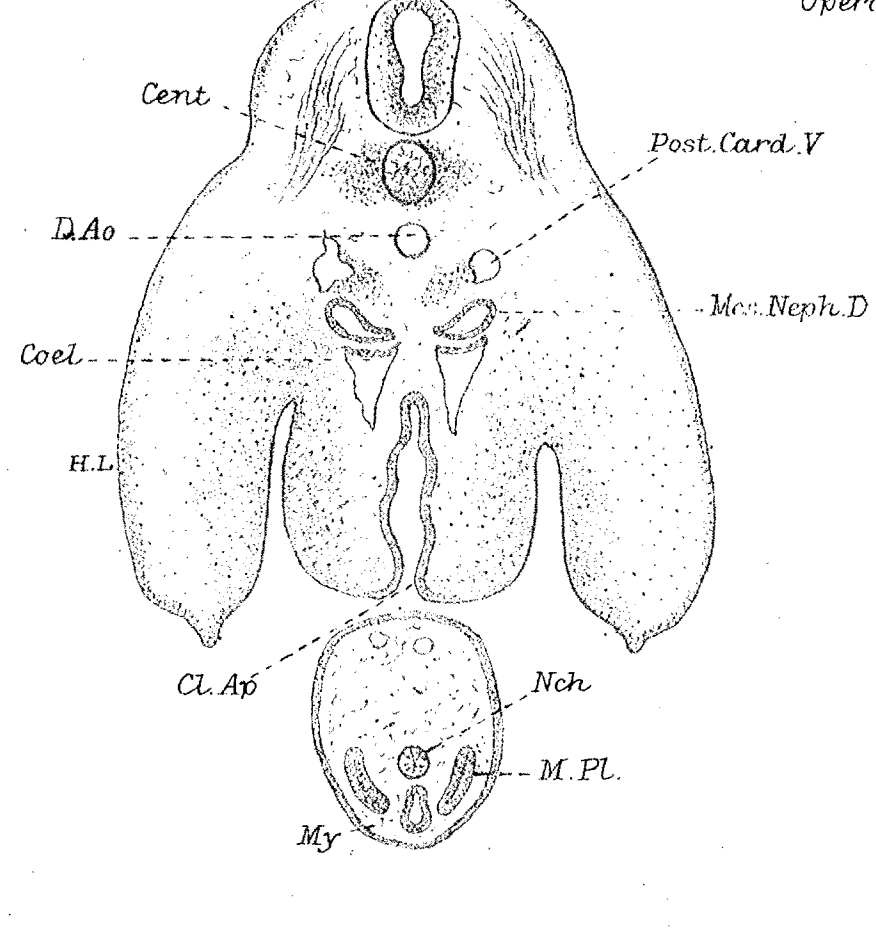

33 (× 22)

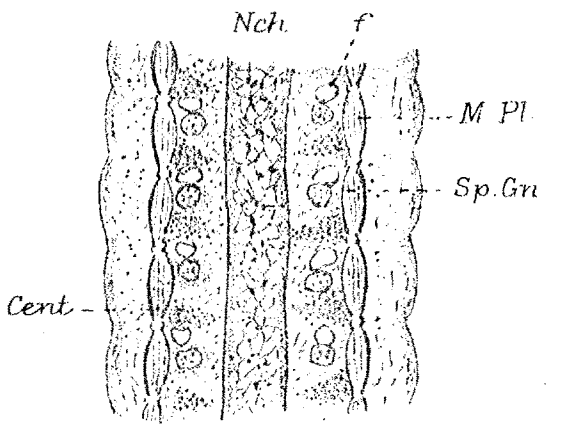

T.J.P. ad nat. del^{t}
M.P. Parker chr. lith.

West, Newman imp.

APTERYX. Sections of Stages A and B.

34 (×22)

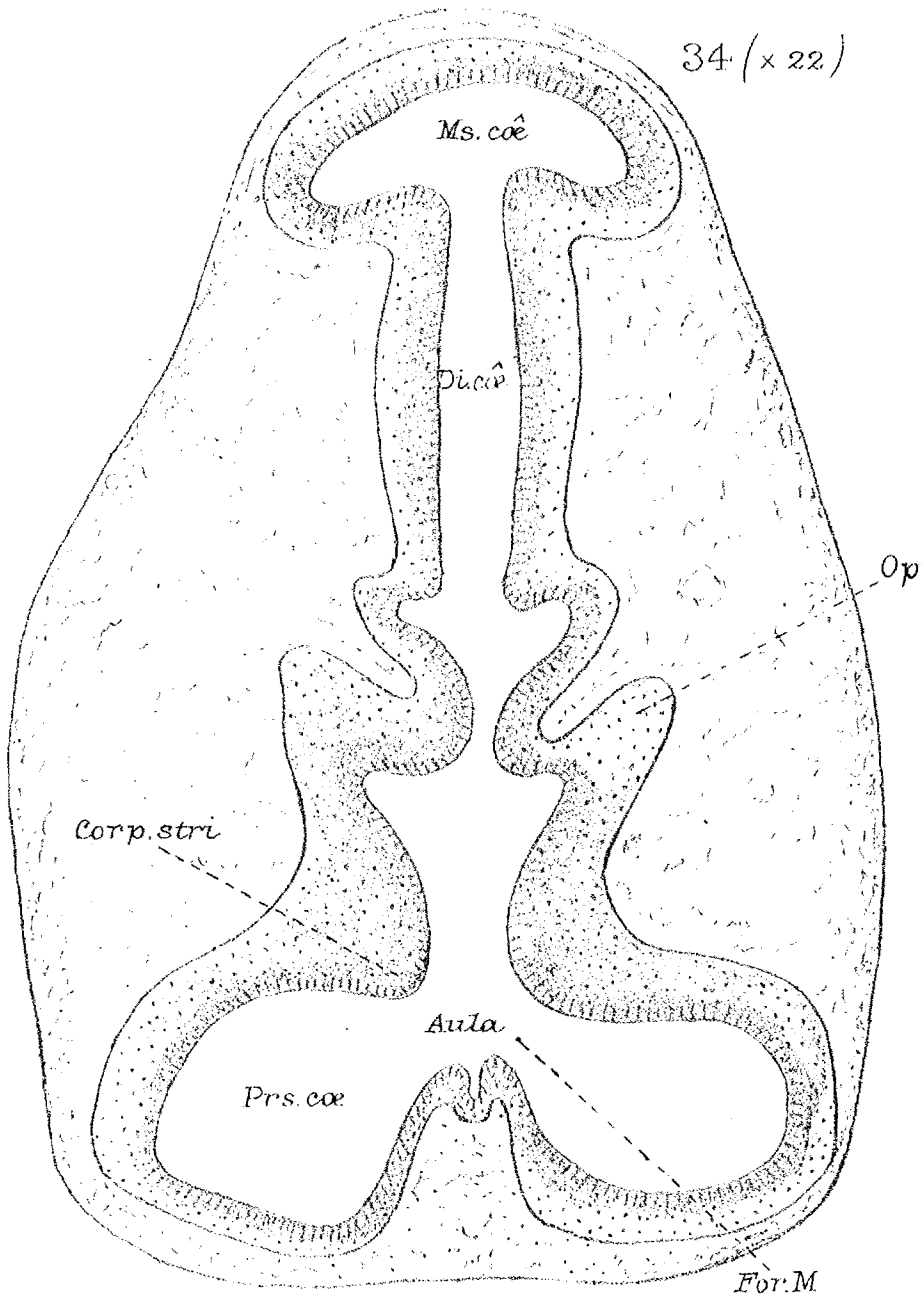

35 (×22)

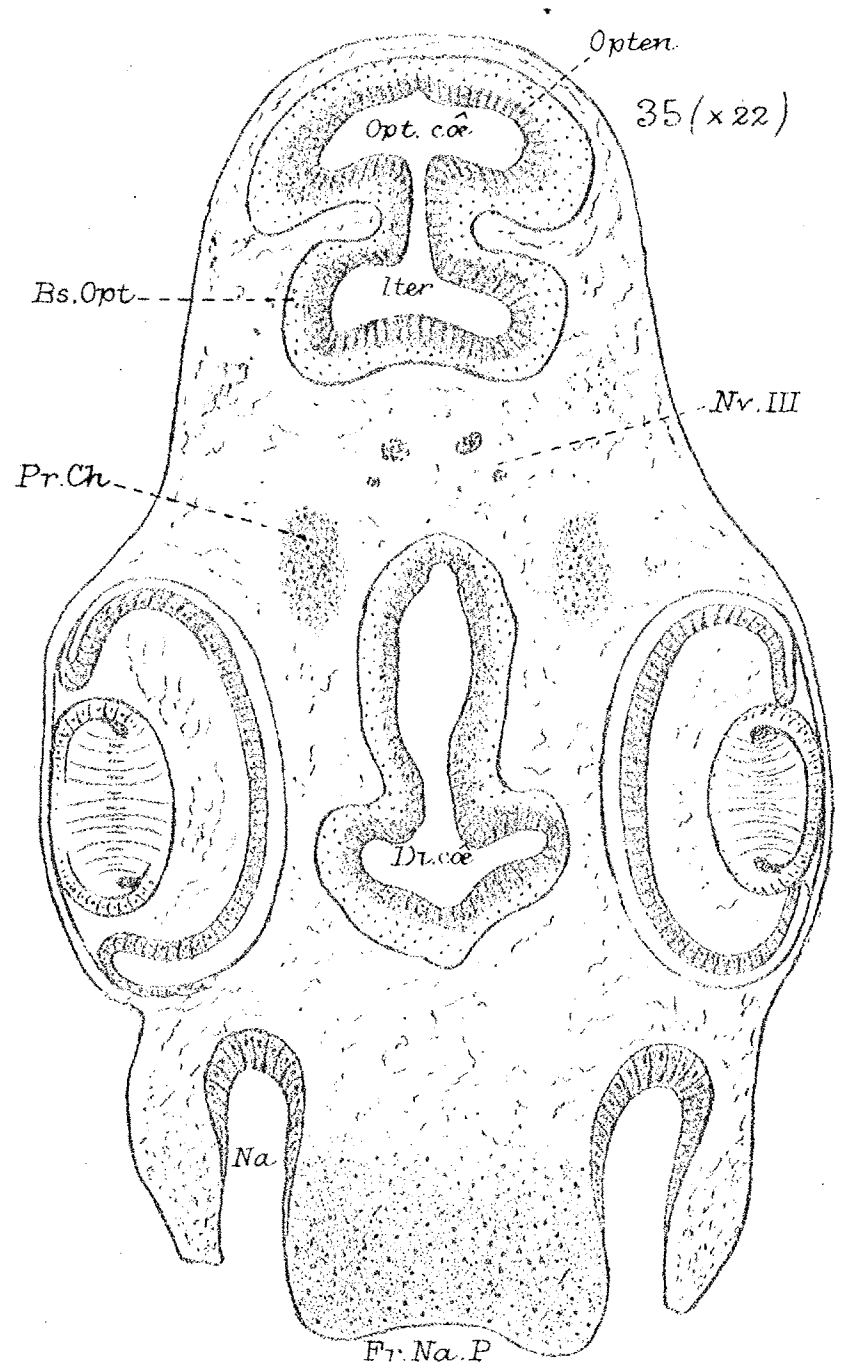

36 (×22)

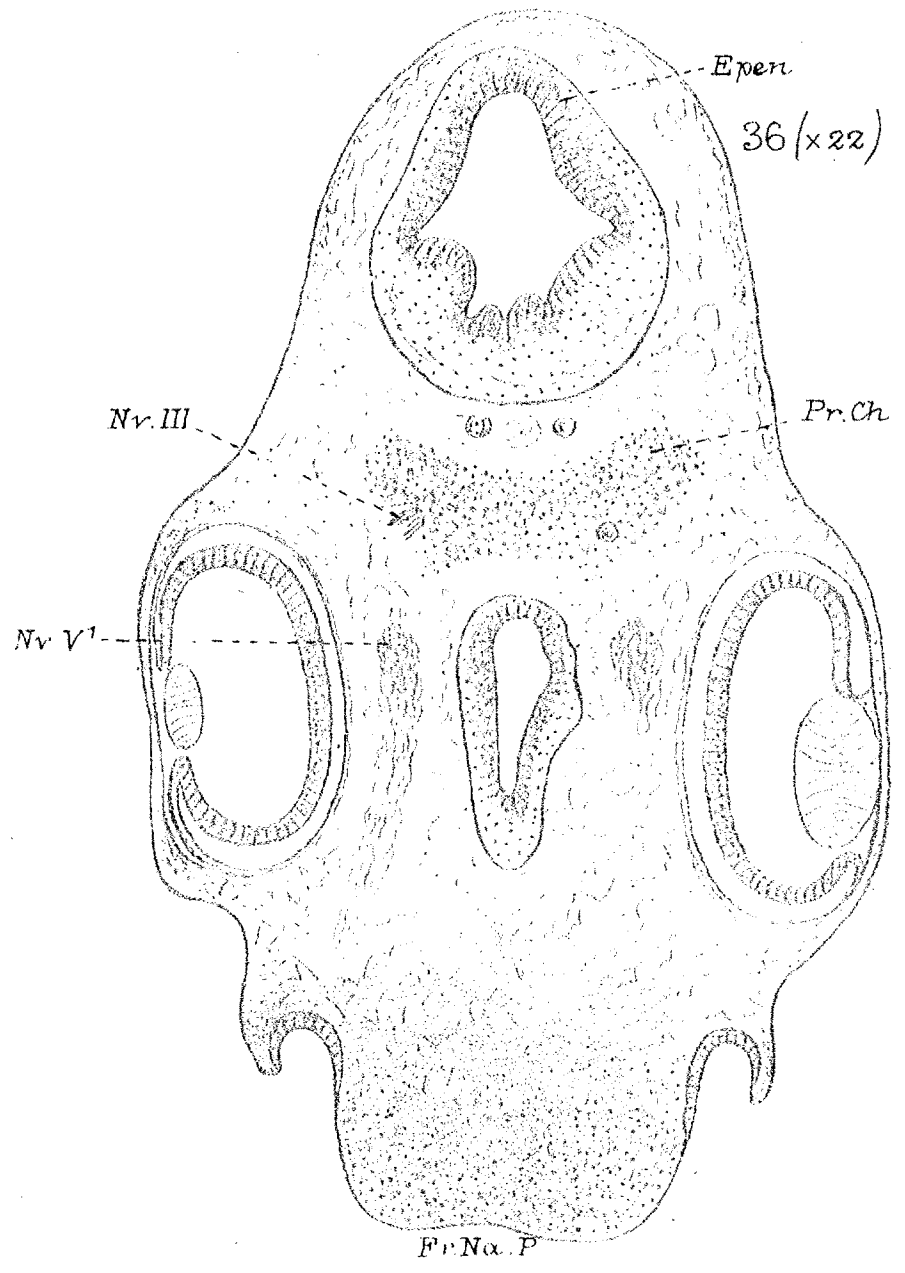

37 (×22)

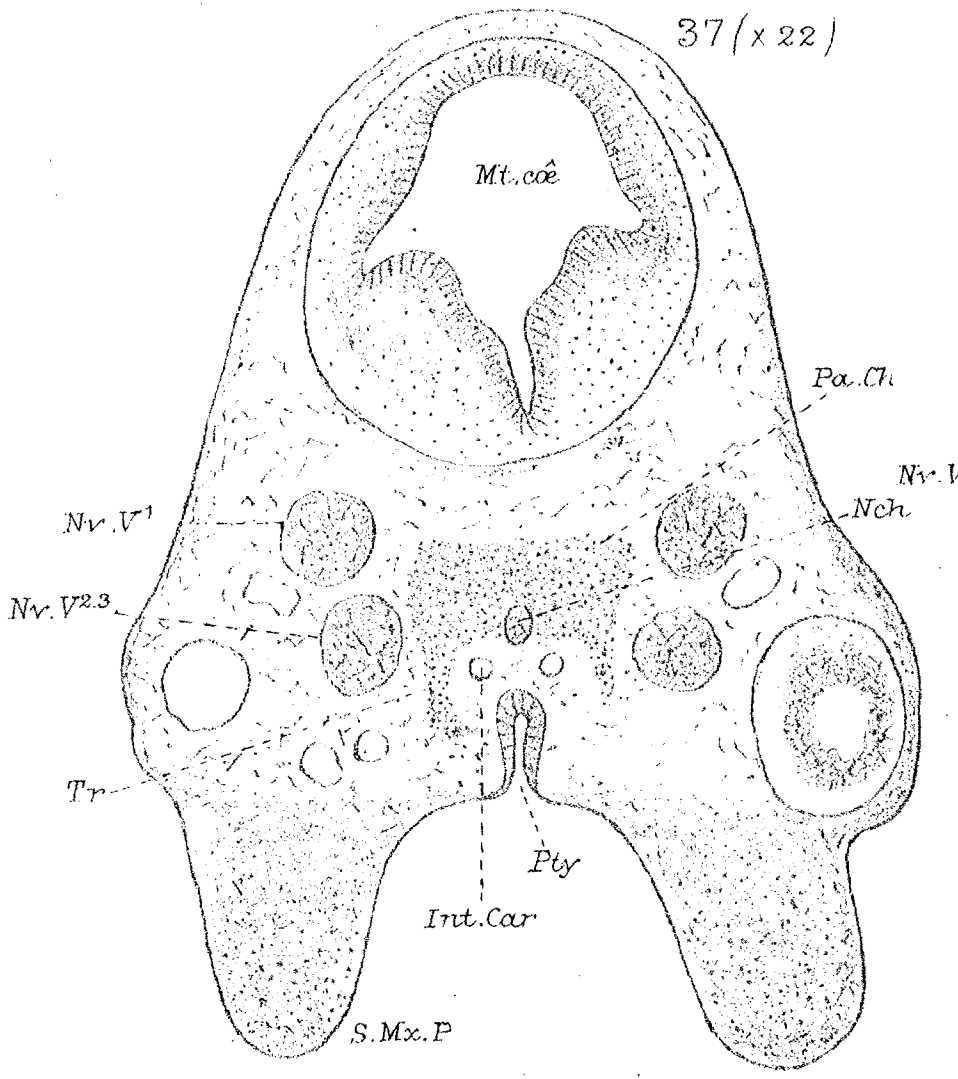

38 (×22)

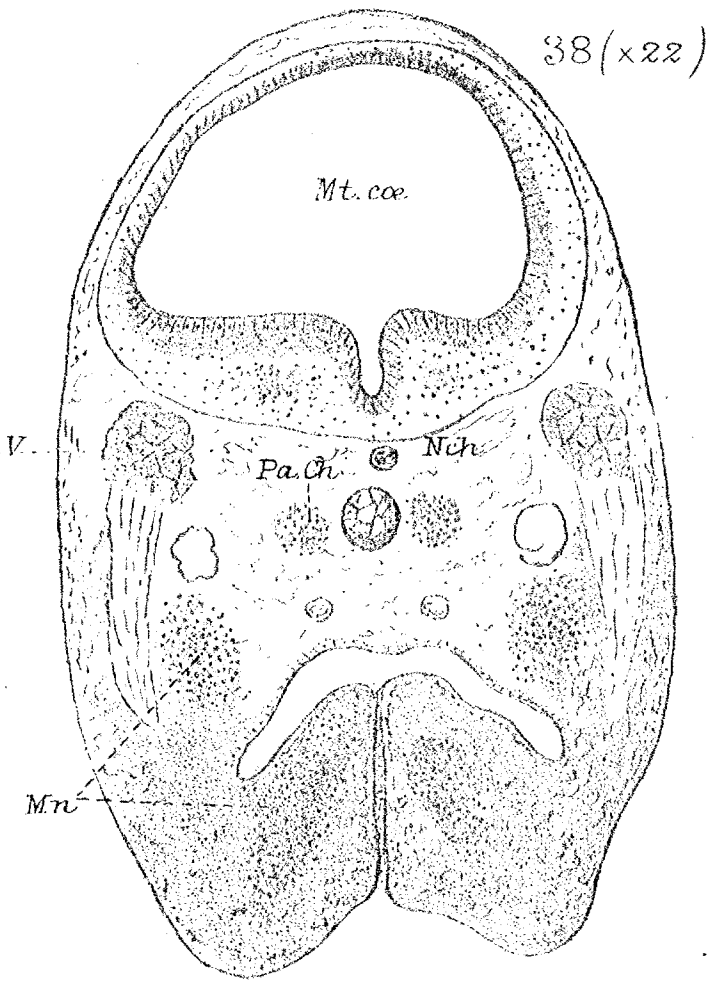

39 (×22)

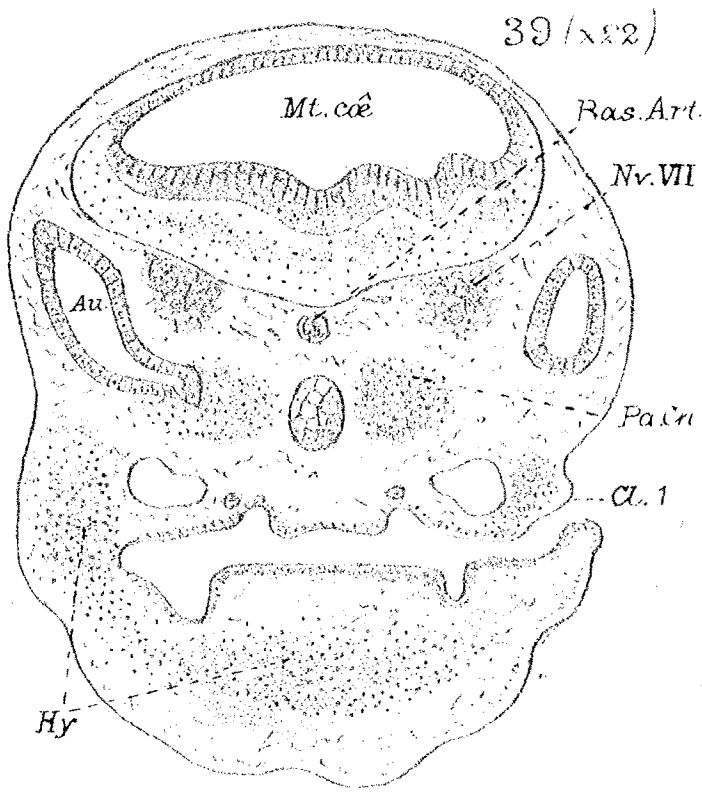

40 (×22)

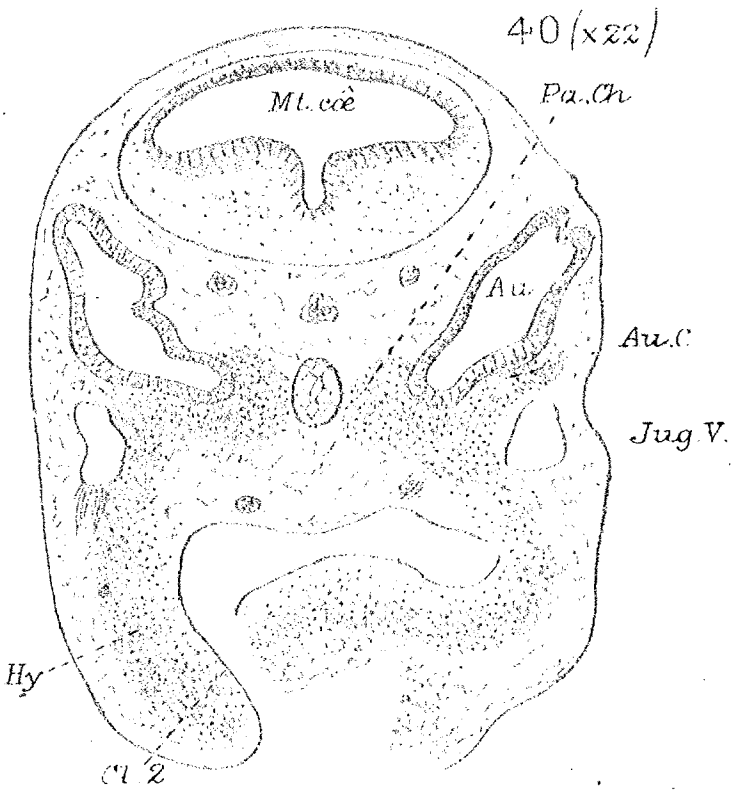

41 (×22)

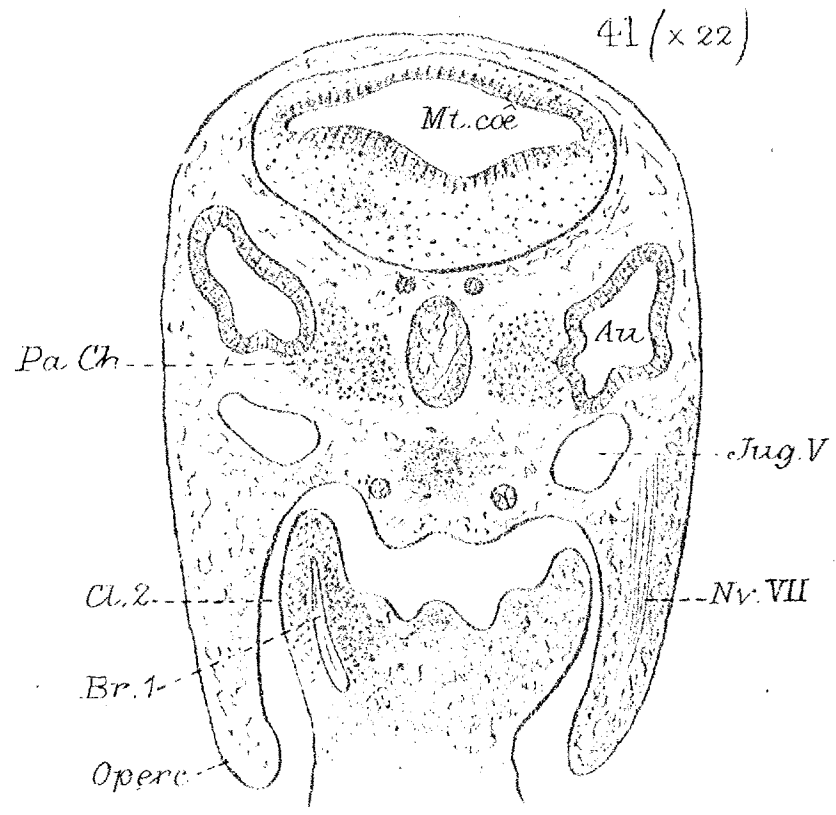

42 (×22)

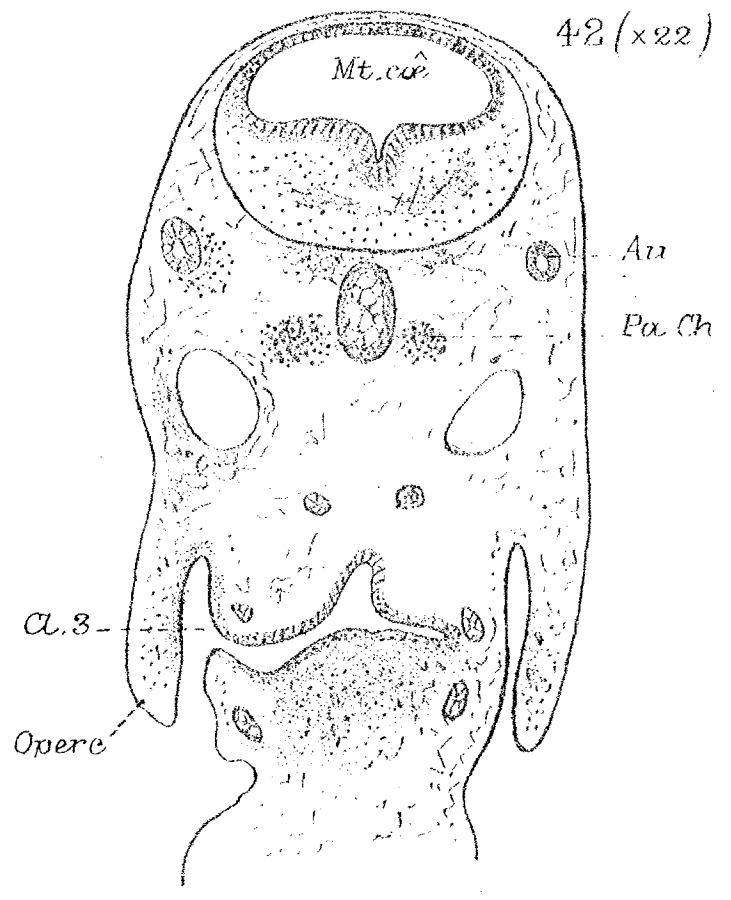

43 (×22)

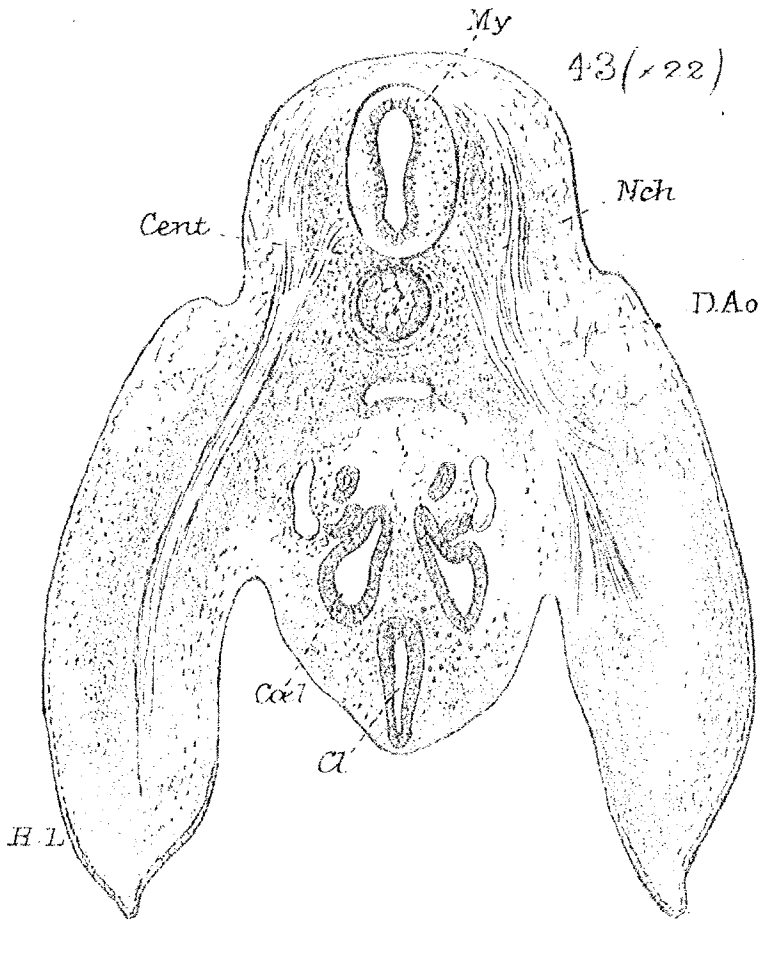

44 (×22)

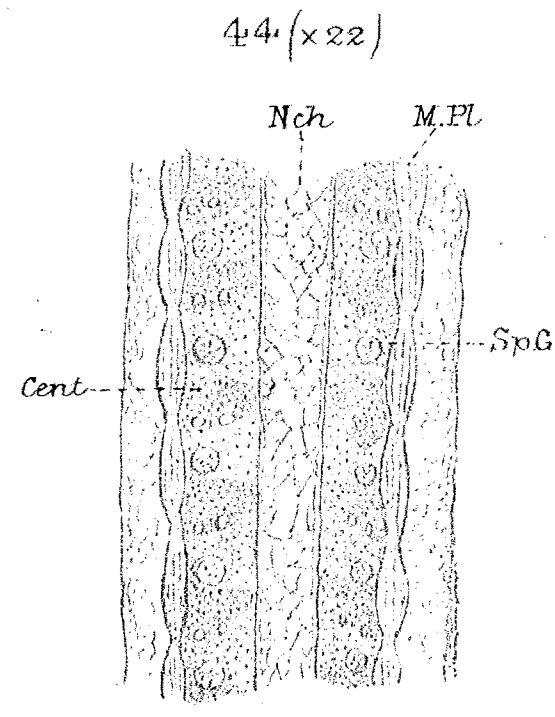

T. J. P. ad nat. del^{t}.
M. P. Parker chr. lith.

West, Newman imp.

APTERYX Sections of Stage C.

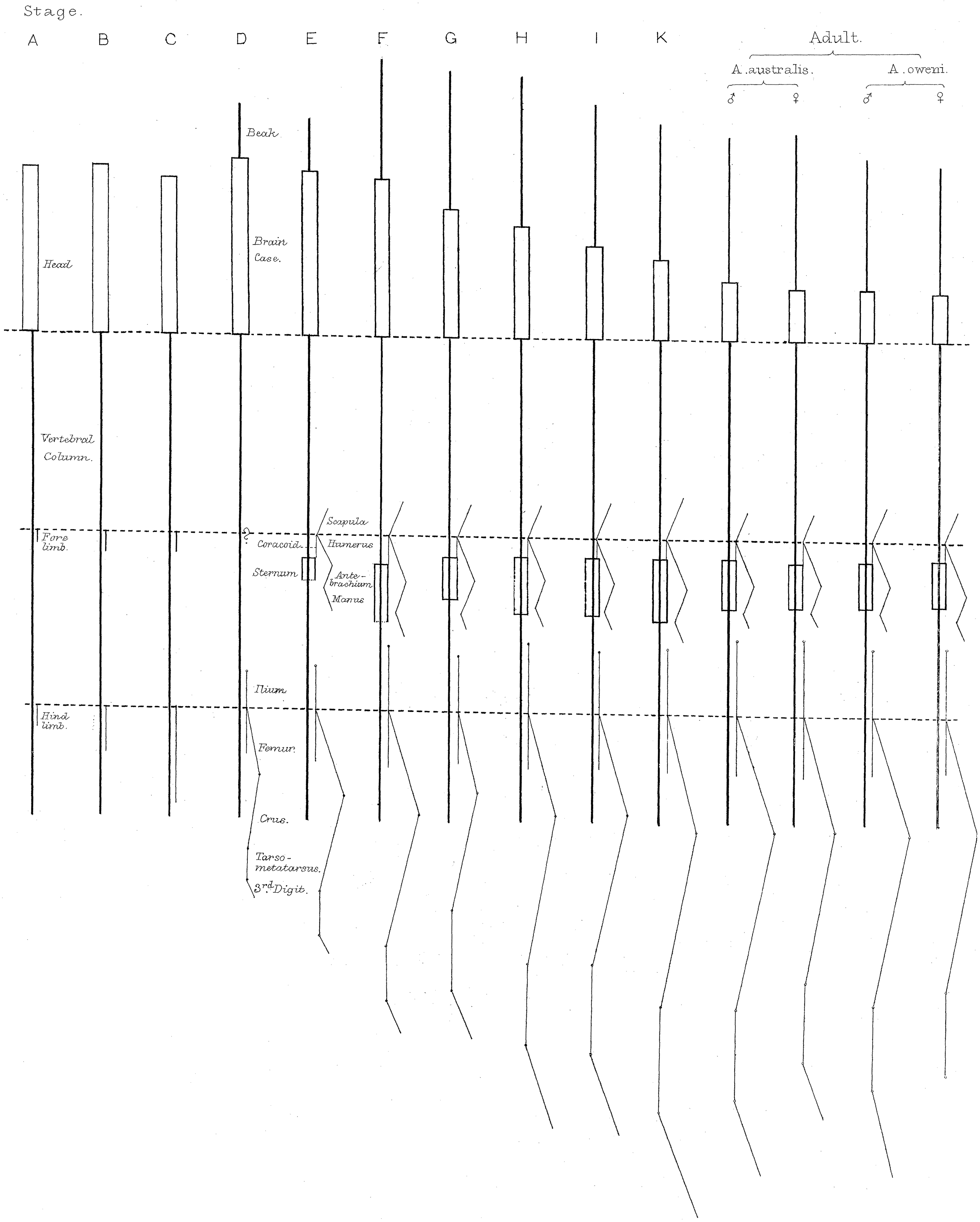

T.J.P. ad nat. del^{t}
M.P. Parker lith.

West, Newman imp.

APTERYX. Graphic Representation of Rate of Growth.

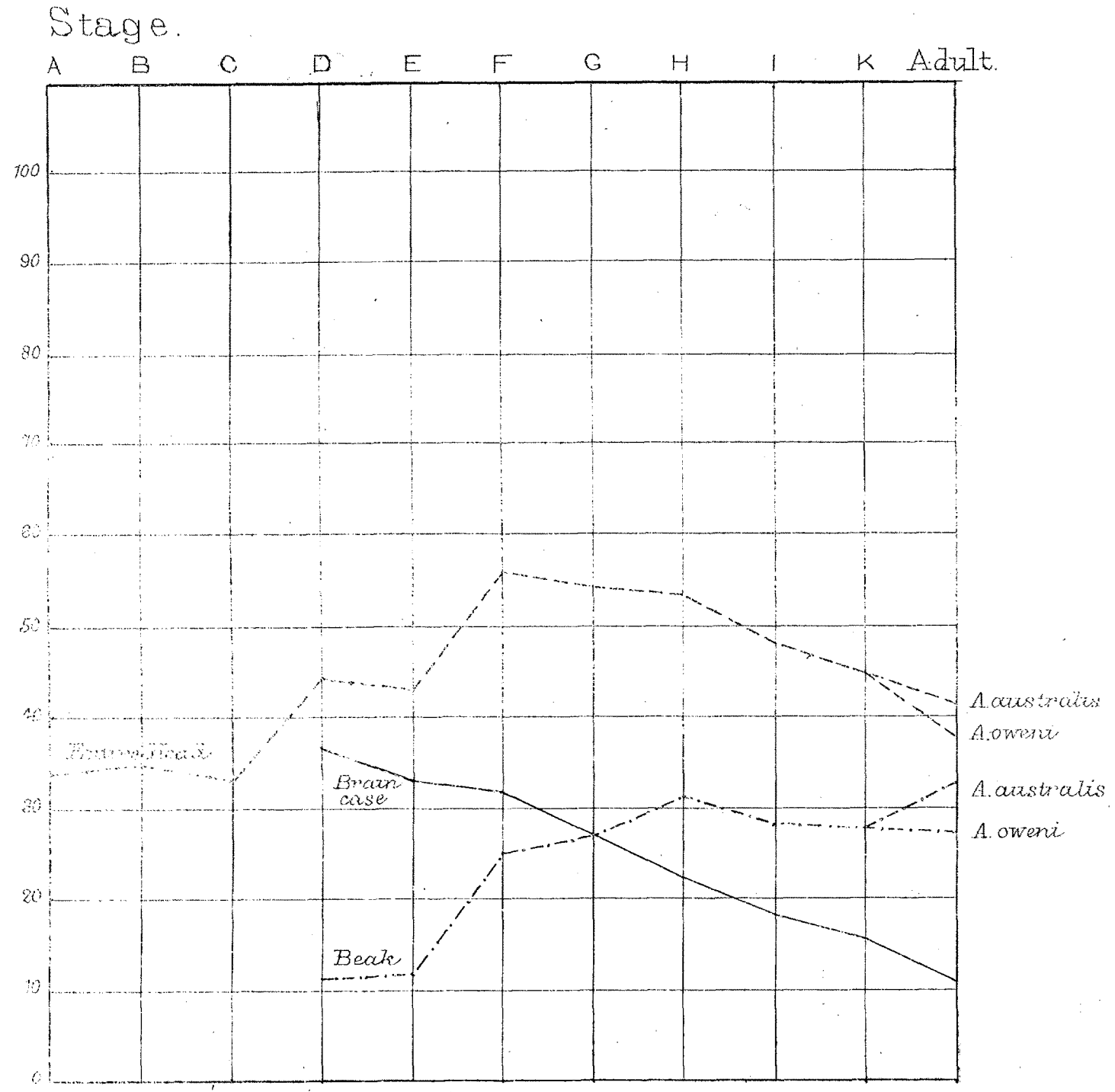

Fig. 46.

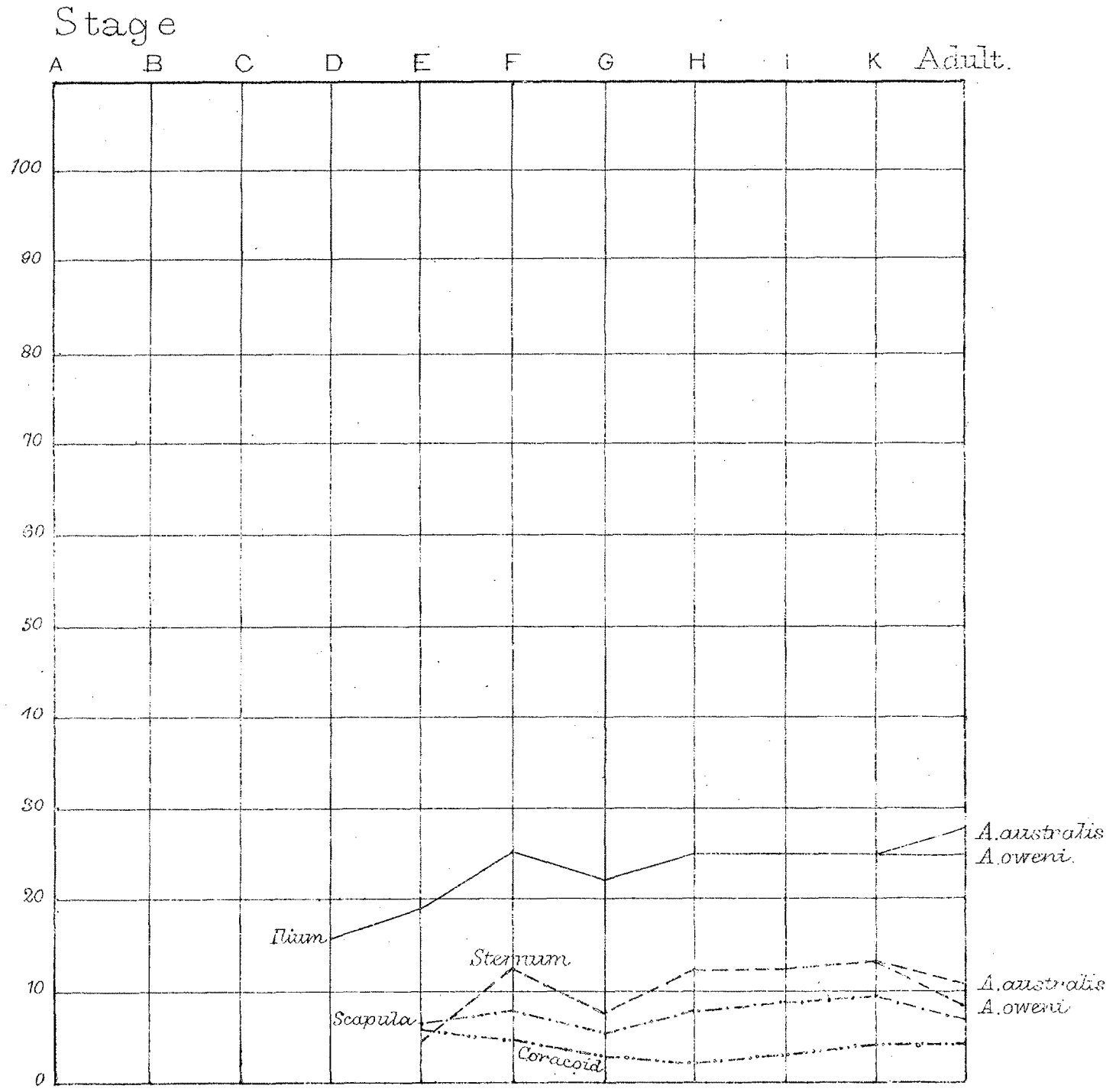

Fig. 47.

Length of Vertebral Column = 100.

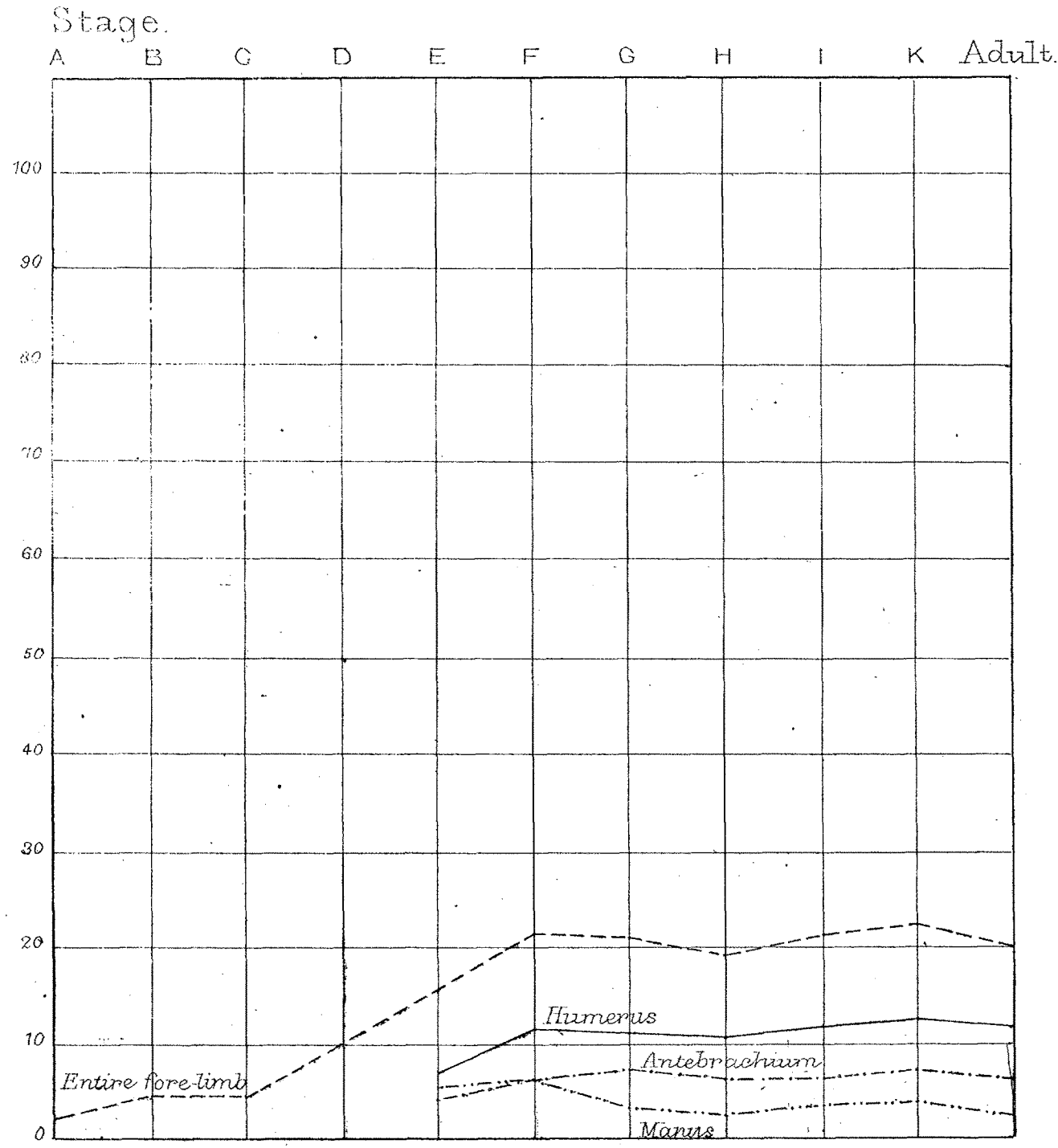

Fig. 48.

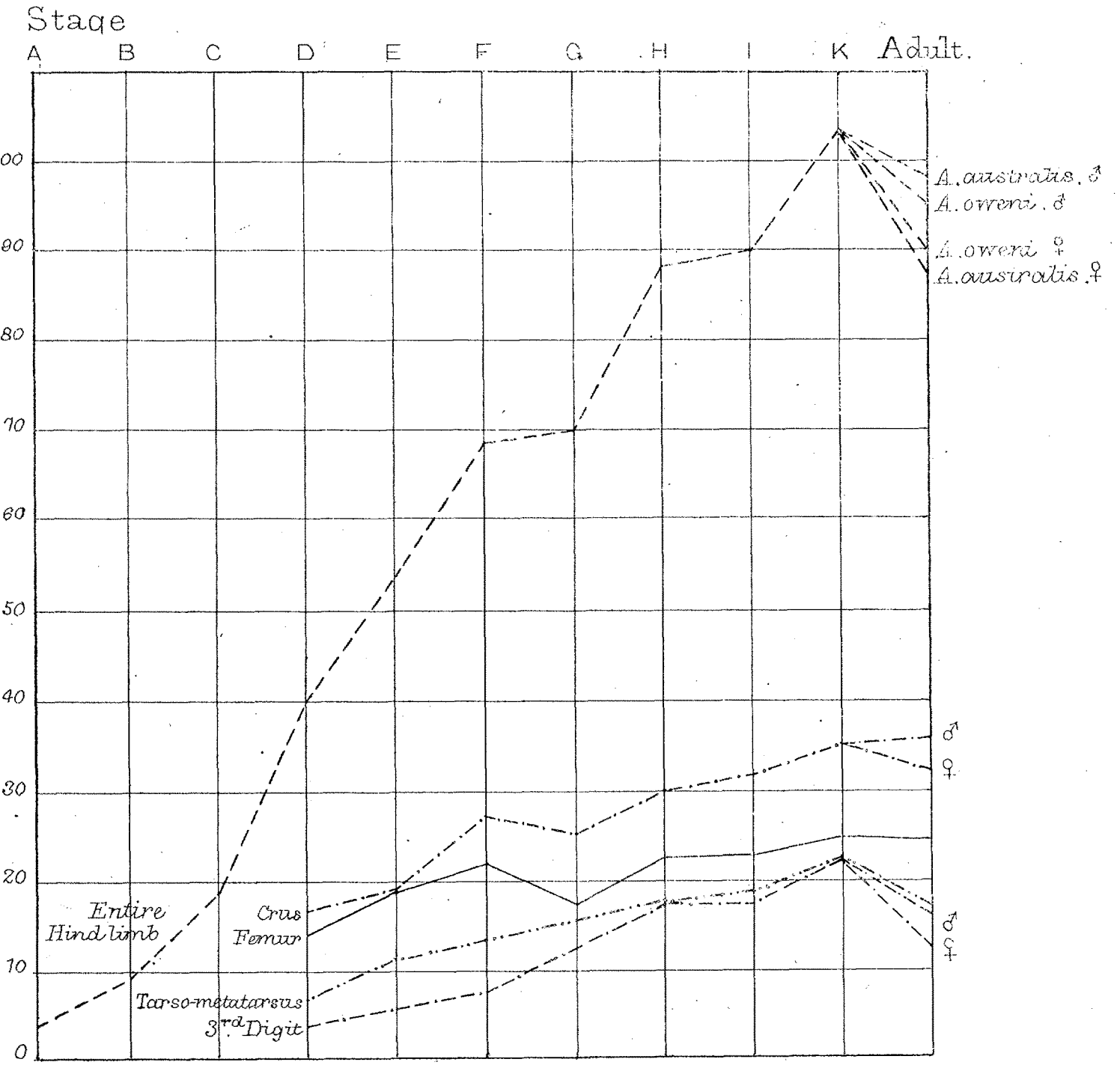

Fig. 49.

T. J. P. ad nat. delt.
M. P. Parker lith.

West, Newman imp.

APTERYX. Curves of Growth.

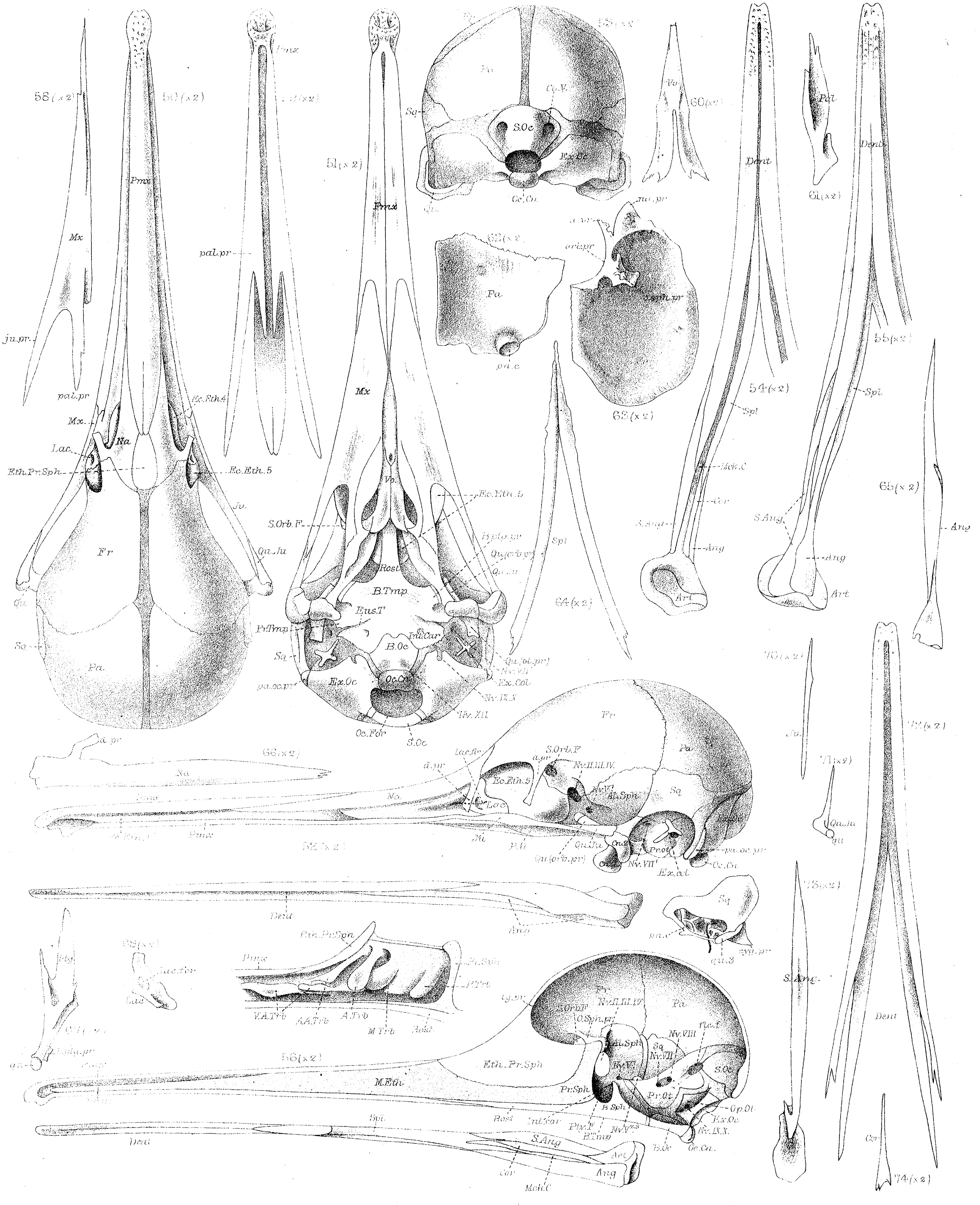

T.J.P. ad nat. del.t
M.P. Parker chr. lith.

West, Newman imp.

APTERYX. Skull of ripe embryo (Stage K.)

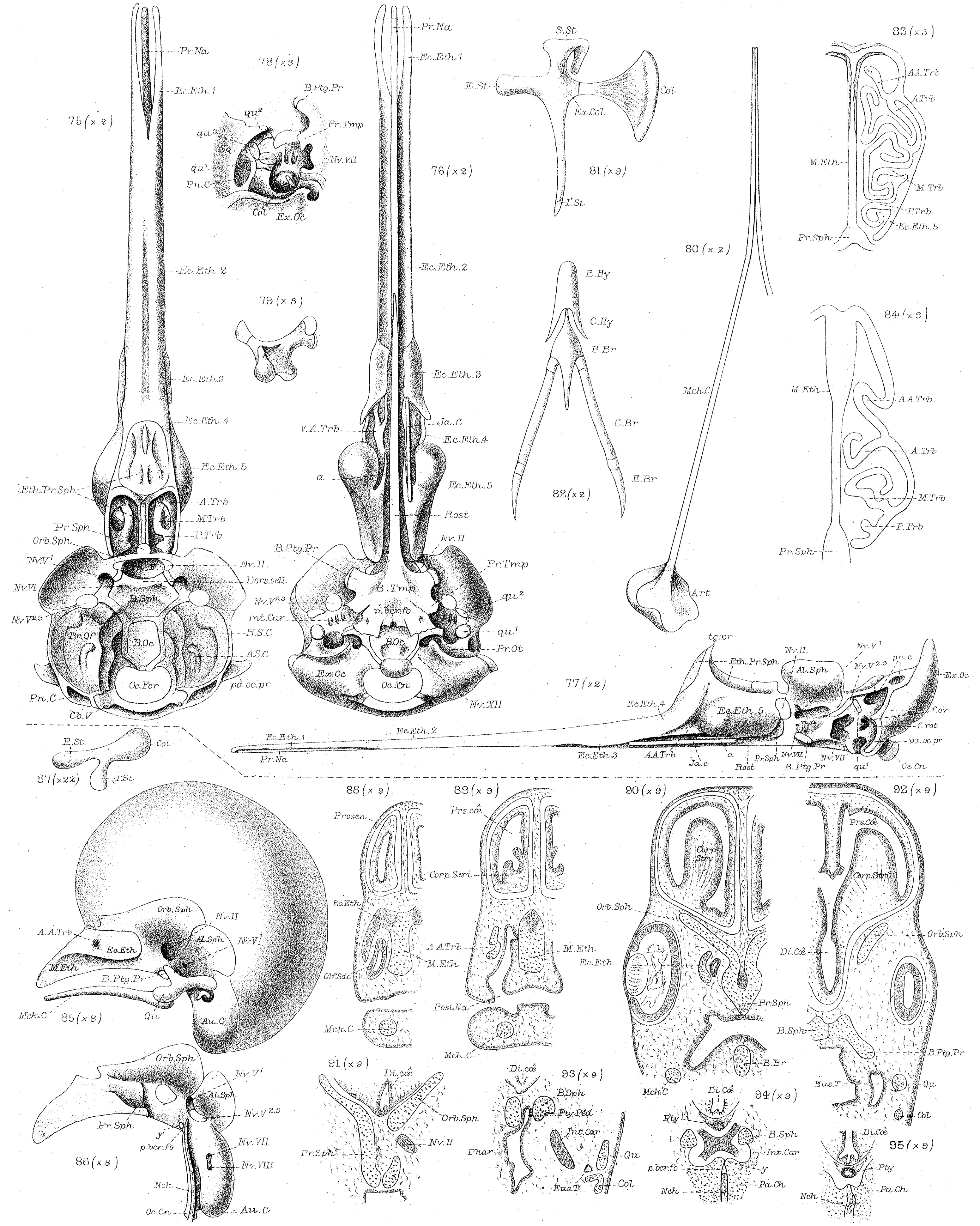

T.J.P. ad nat.del^t.
M.P.Parker chr.lith.

APTERYX. Skull: Stages K and D.

West, Newman imp.

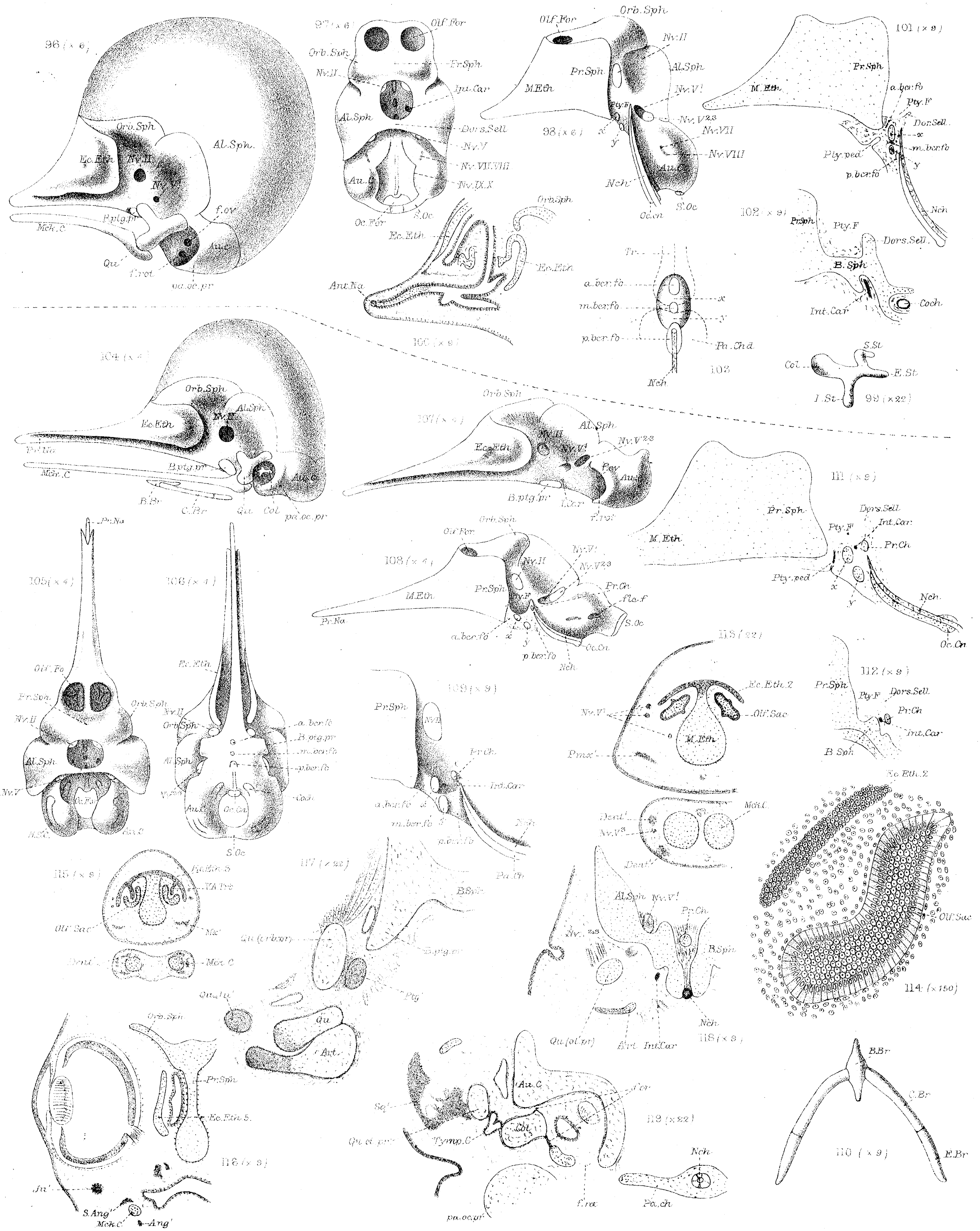

T.J.P. ad nat. del.†
M.P. Parker chr. lith.

West Newman imp.

APTERYX. Skull: Stages E and F.

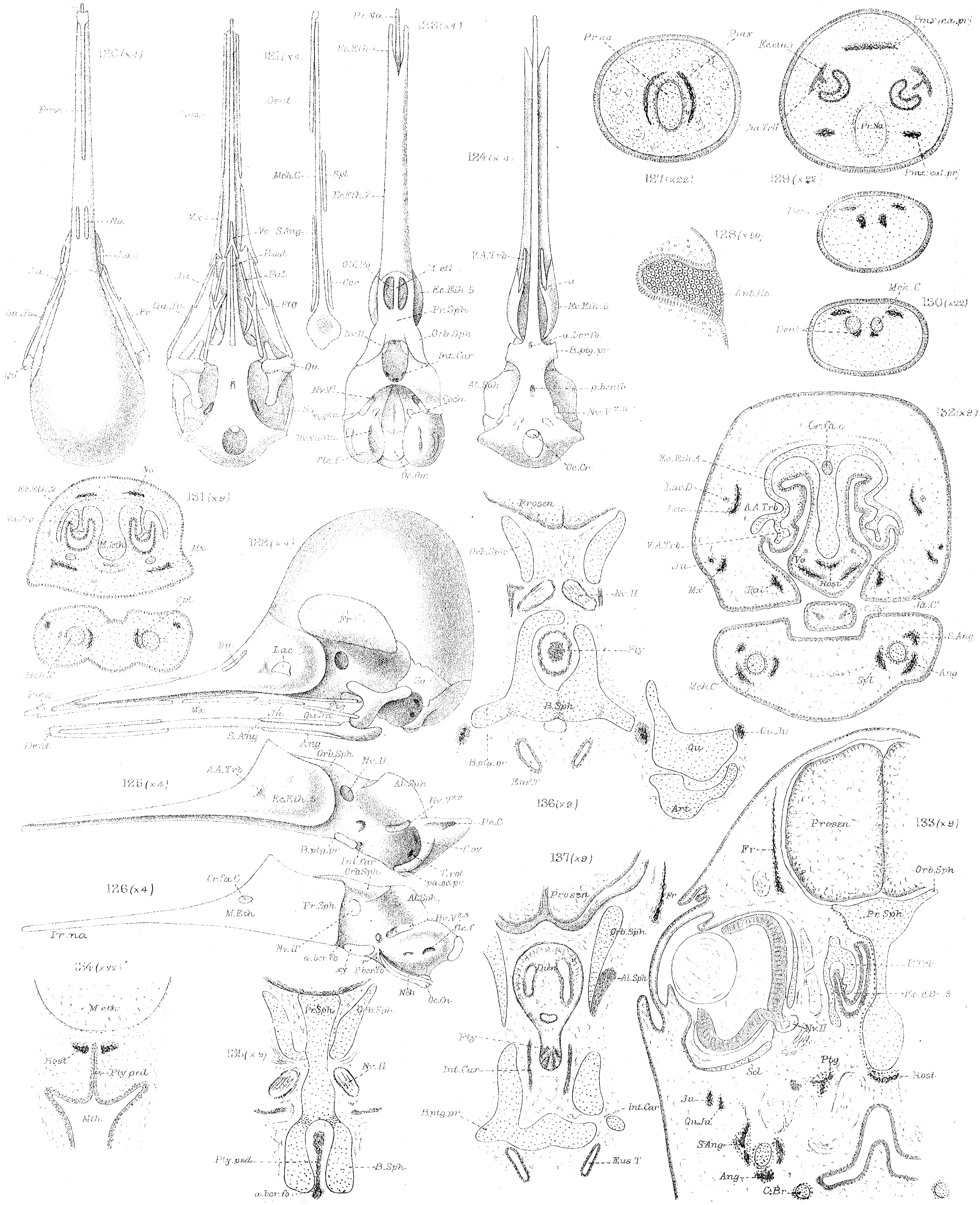

T.J.P. ad nat. del.t
M.P. Parker chr. lith.

West, Newman imp.

APTERYX. Skull: Stage G.

138 (× 9)

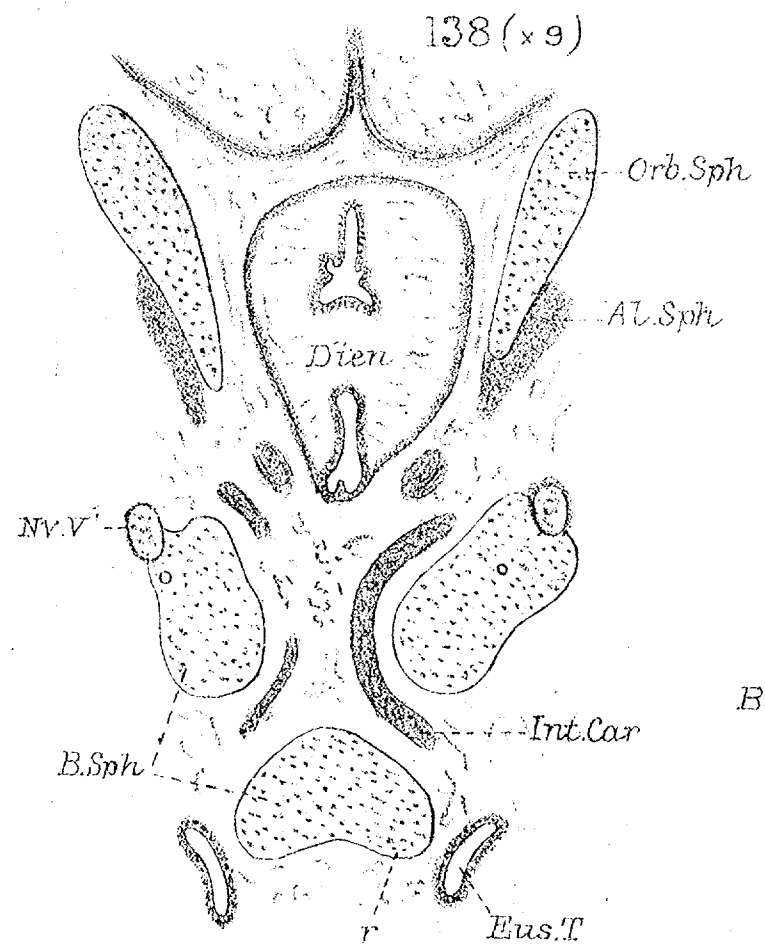

140 (× 9)

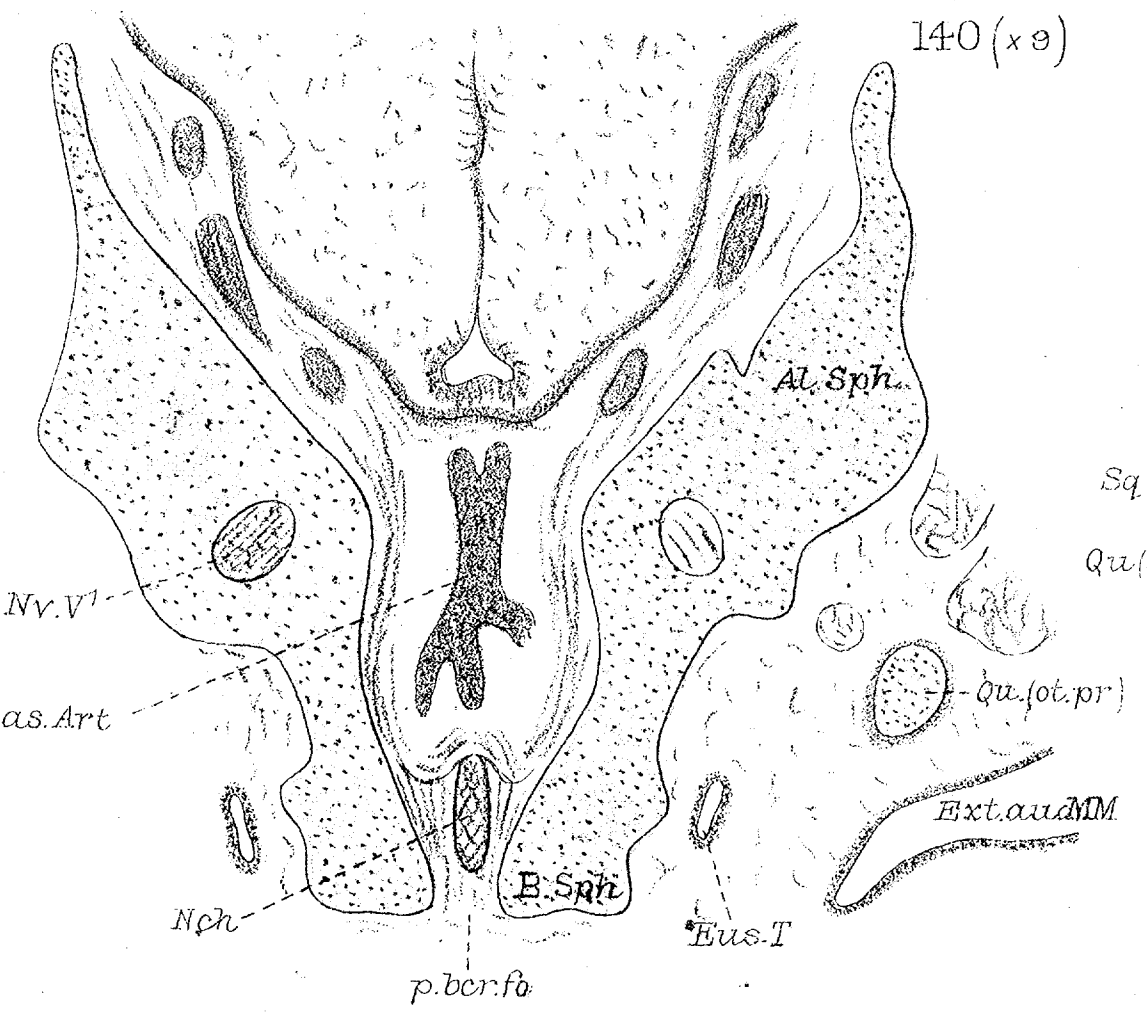

141 (× 9)

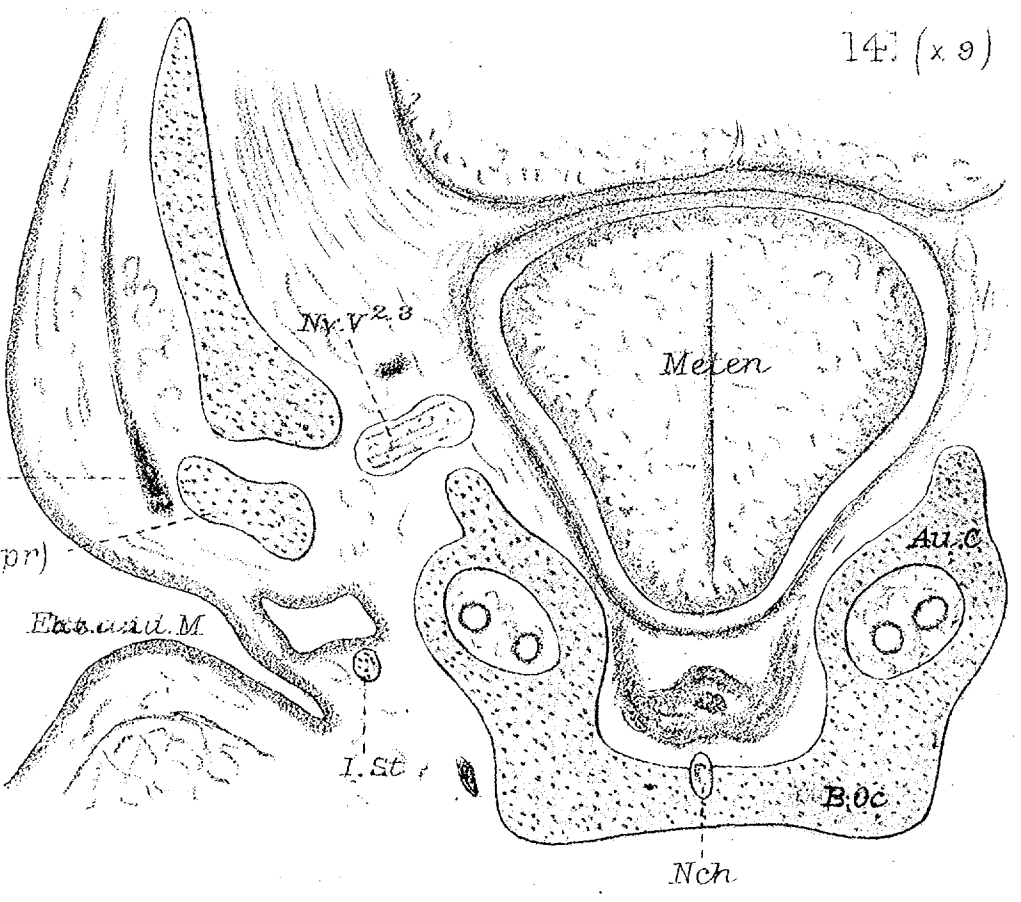

139 (× 9)

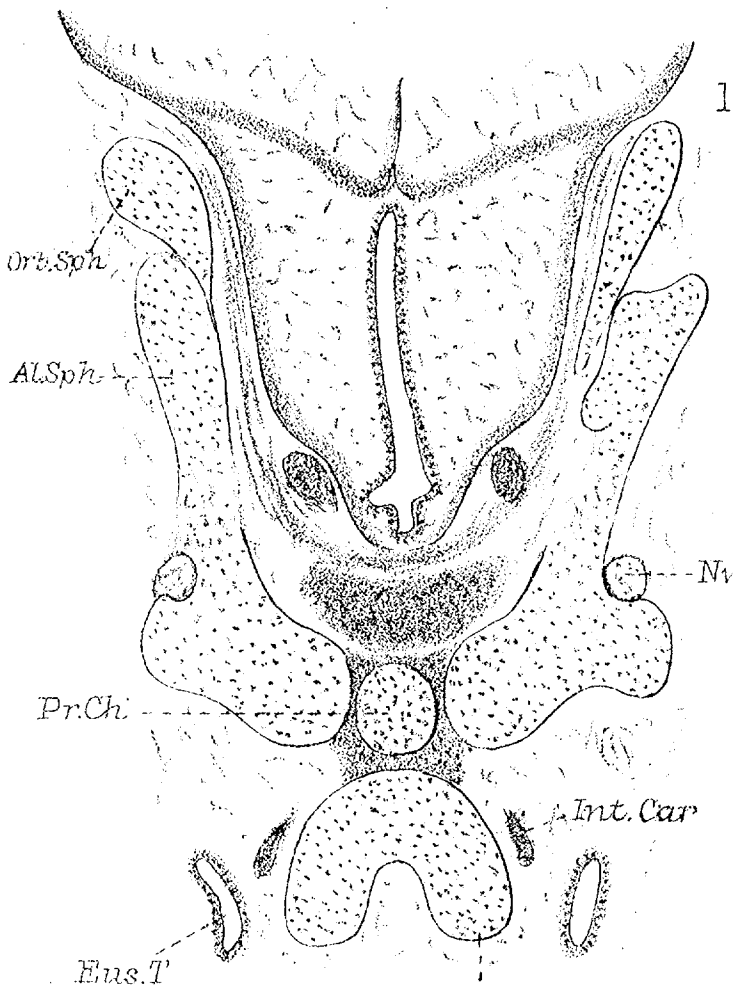

142 (× 9)

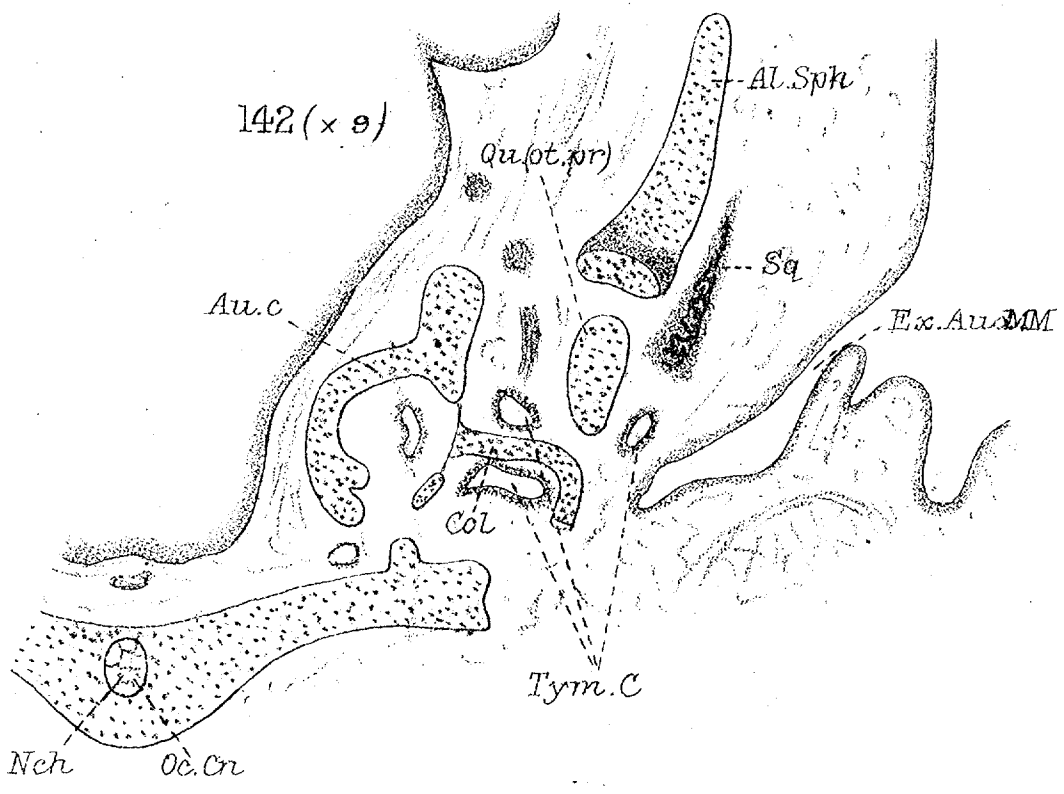

143 (× 9)

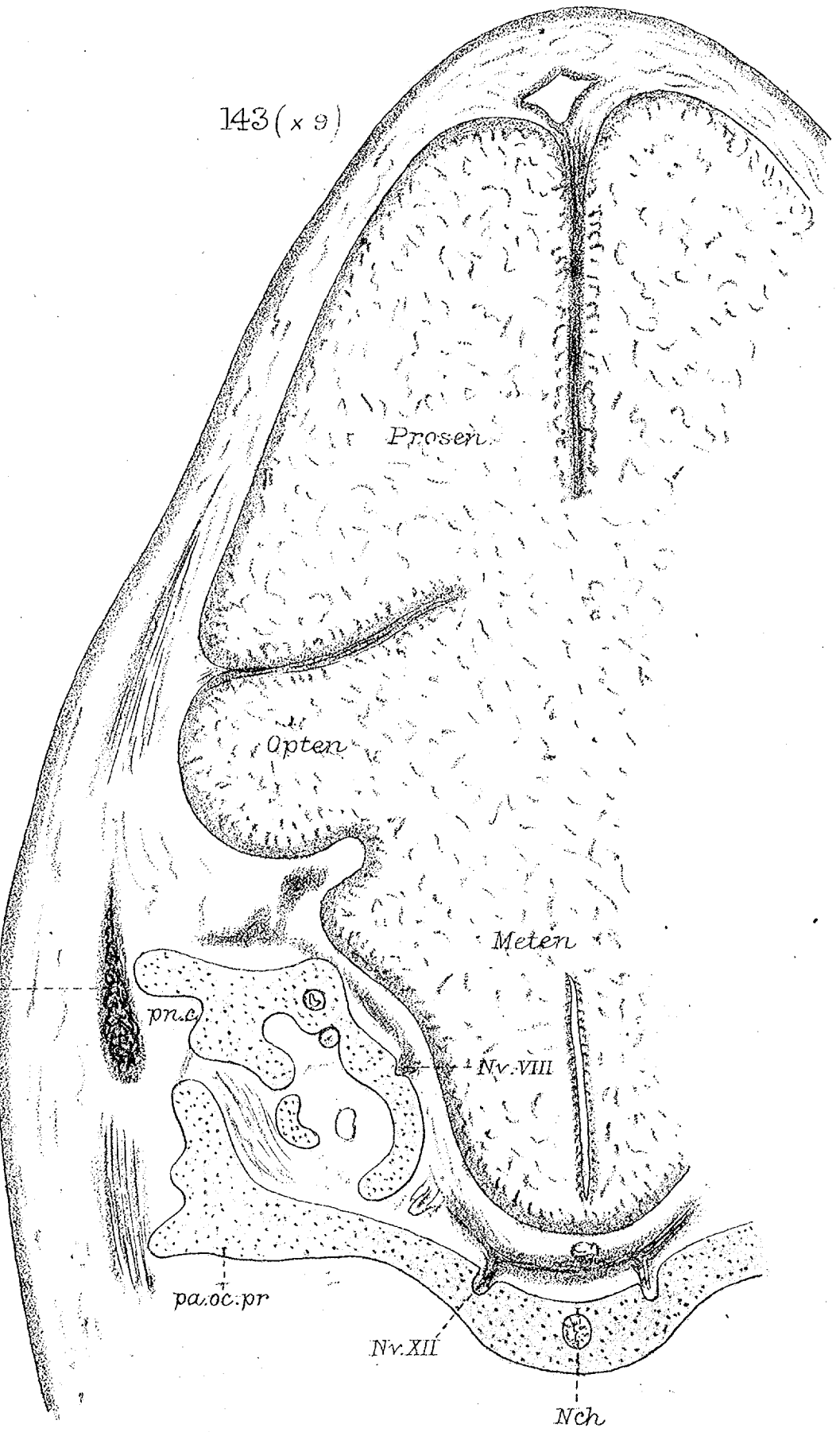

145 (× 9)

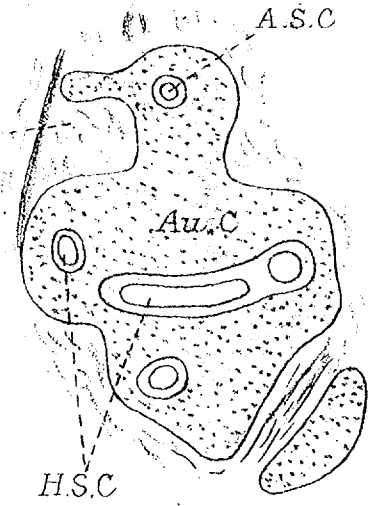

144 (× 9)

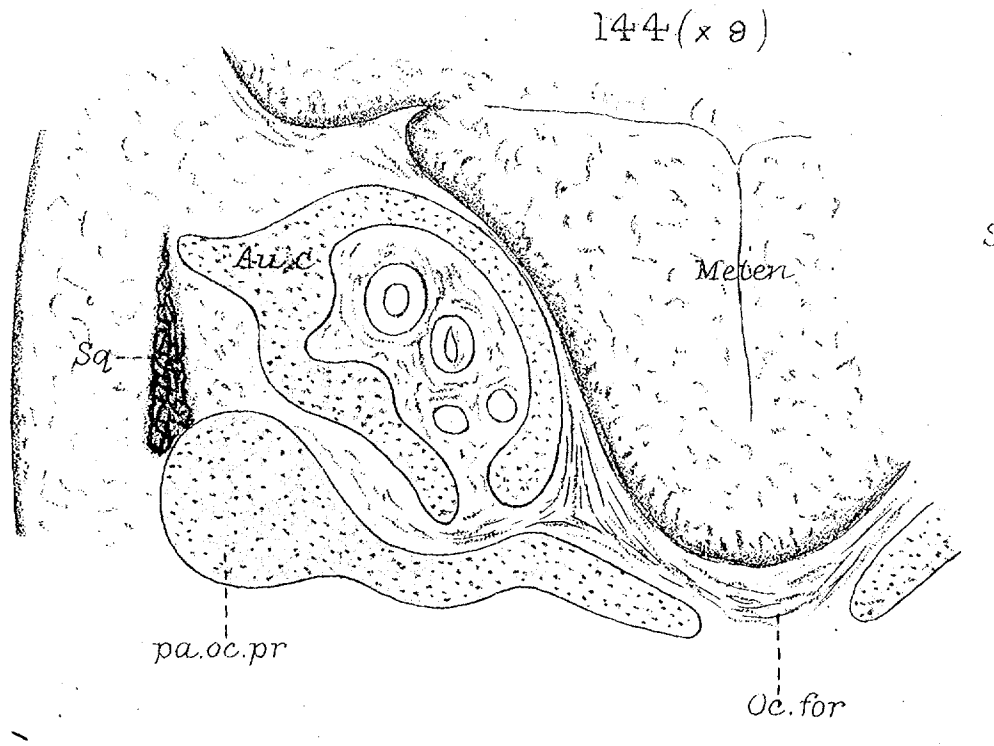

146 (× 2)

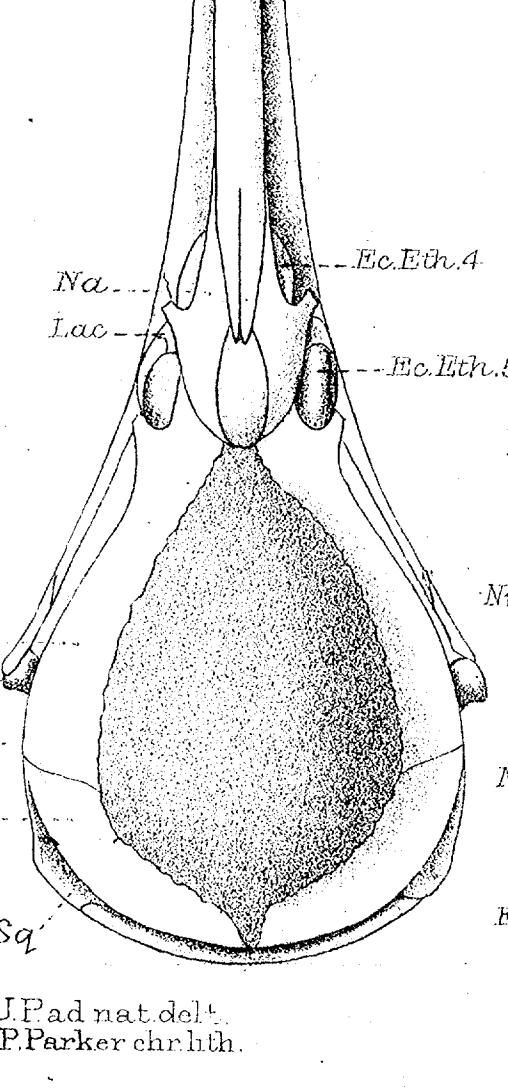

148 (× 2)

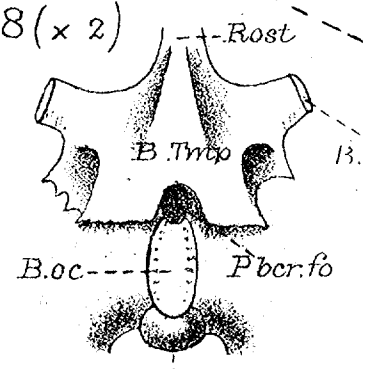

147 (× 2)

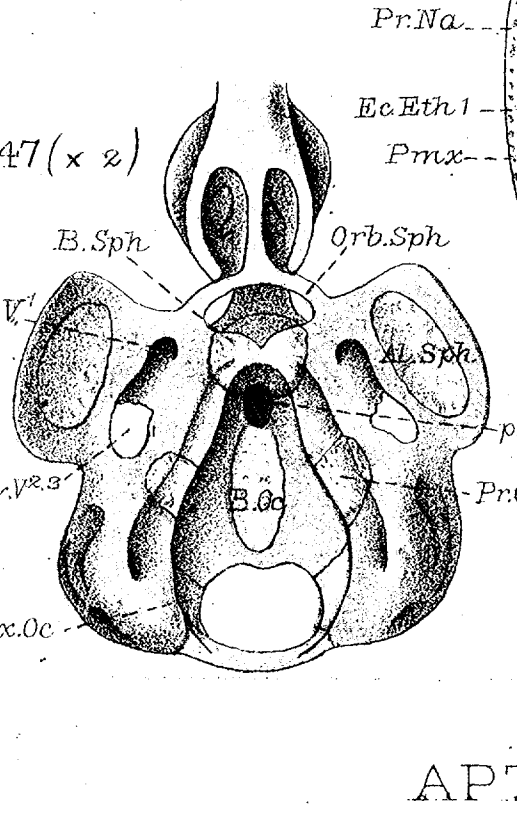

149 (× 22)

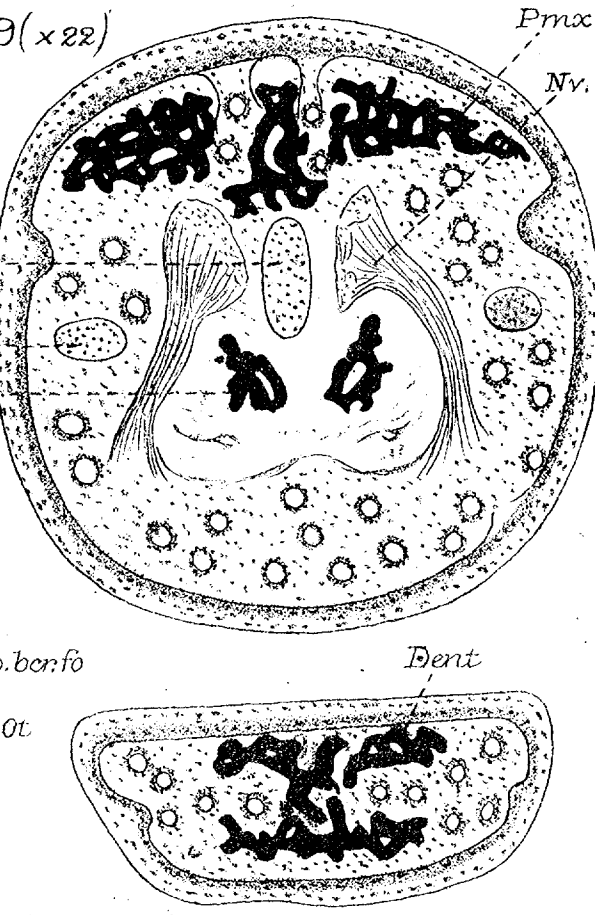

150 (× 22)

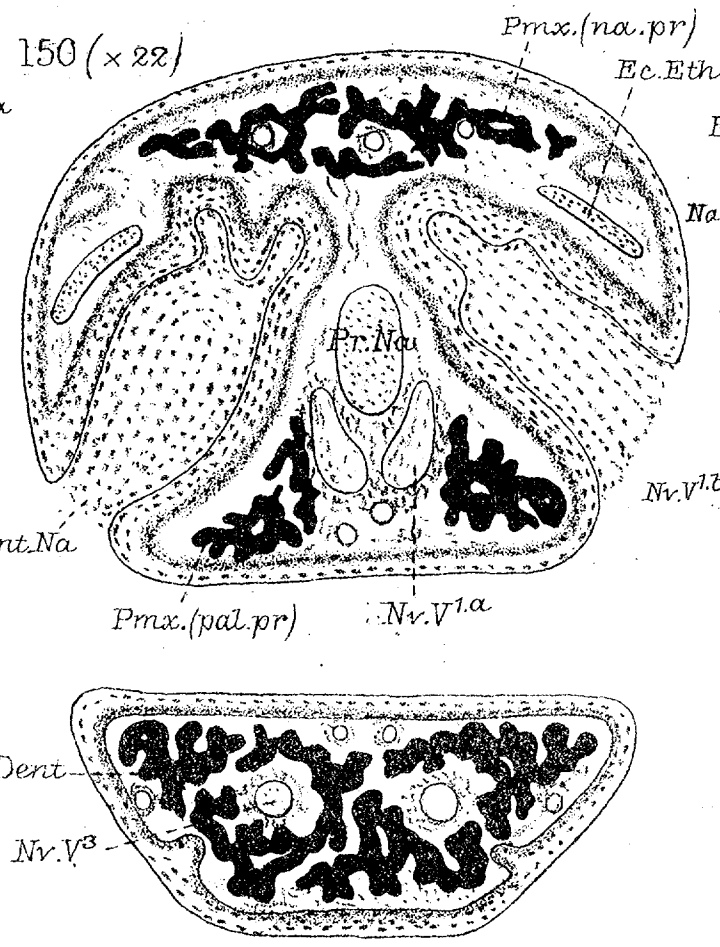

151 (× 22)

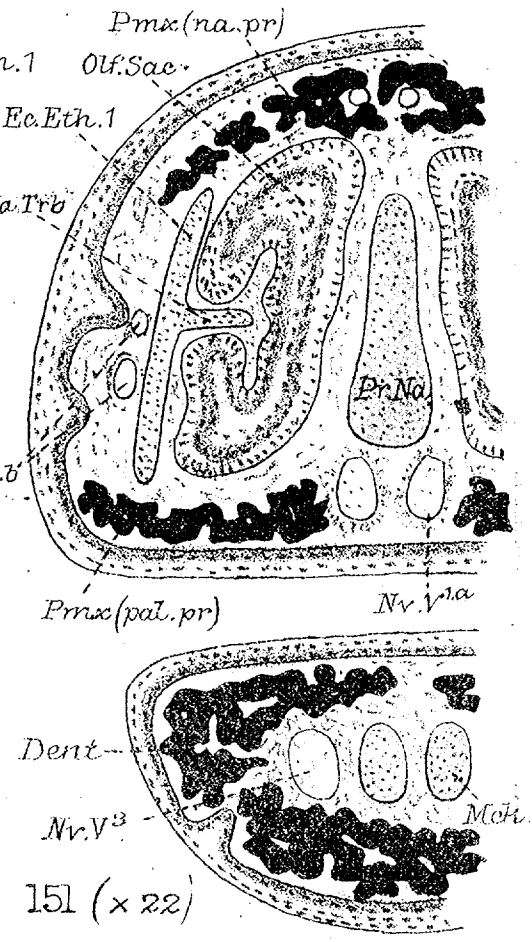

T.J.P. ad nat. del^t.
M.P. Parker chr. lith.

APTERYX. Skull: Stages G and H.

West, Newman imp.

152 (×22)

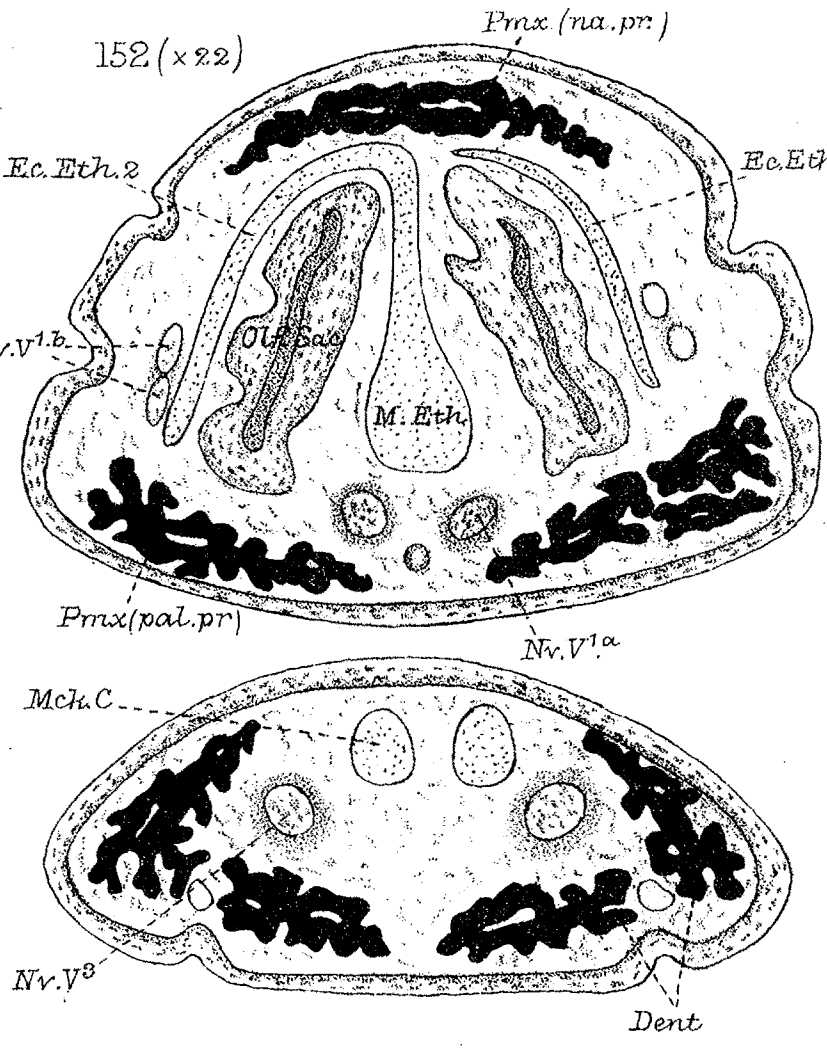

153 (×9)

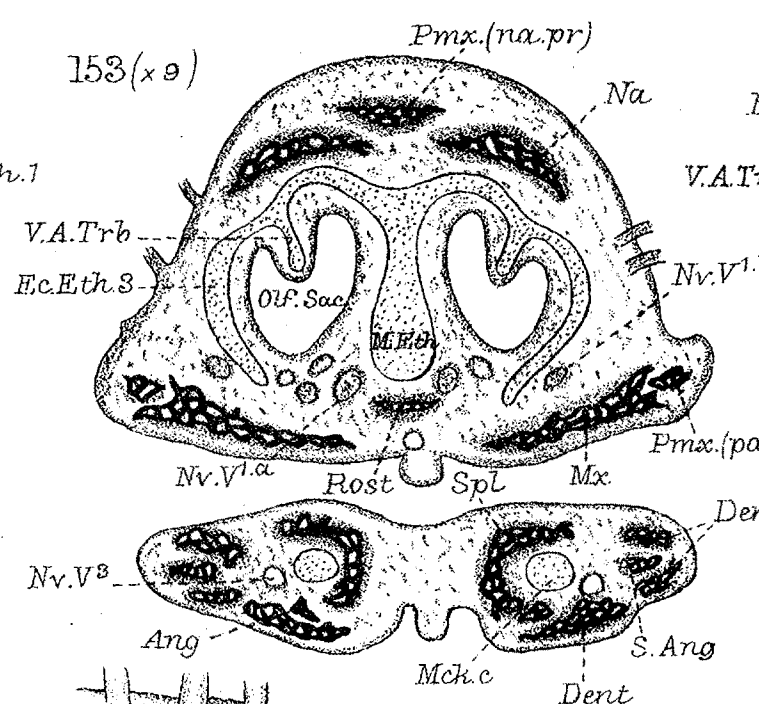

154 (×9)

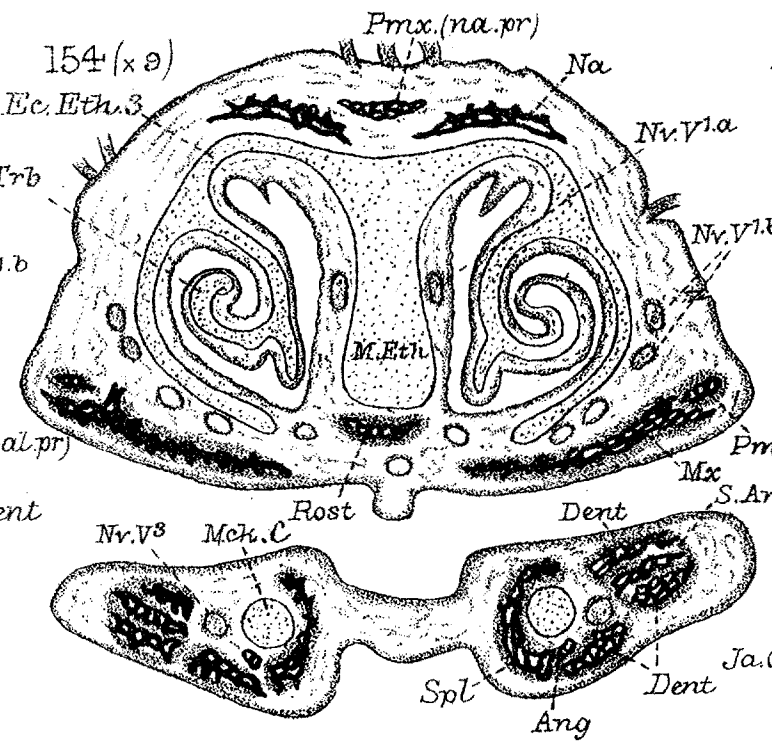

155 (×9)

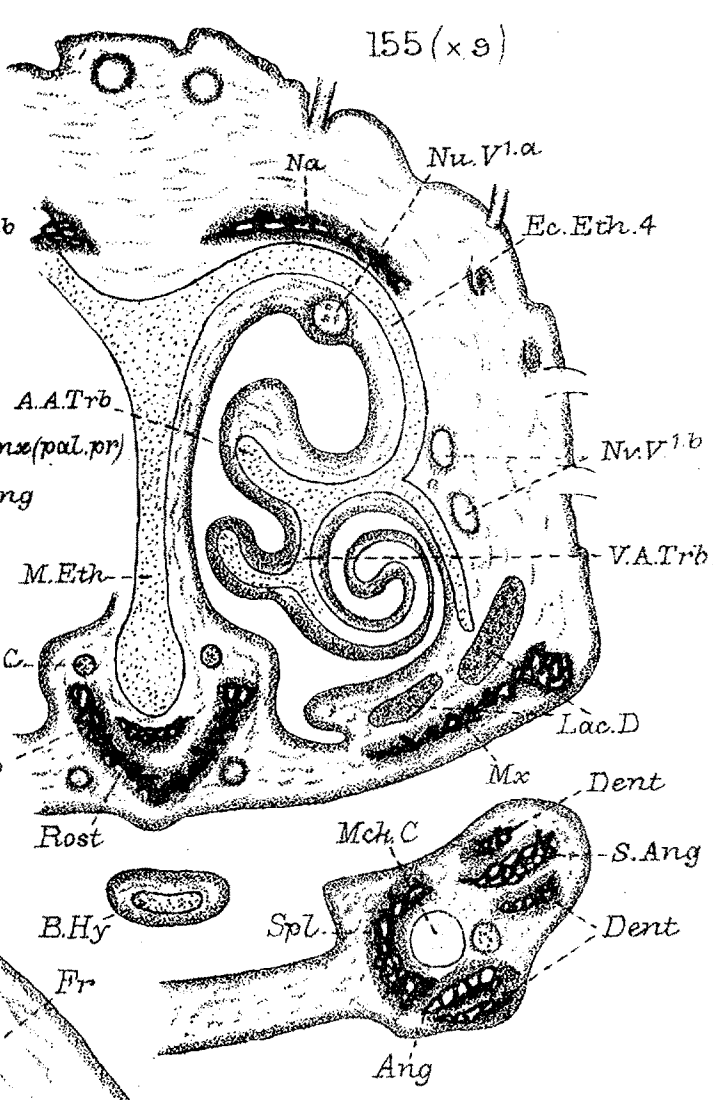

156 (×9)

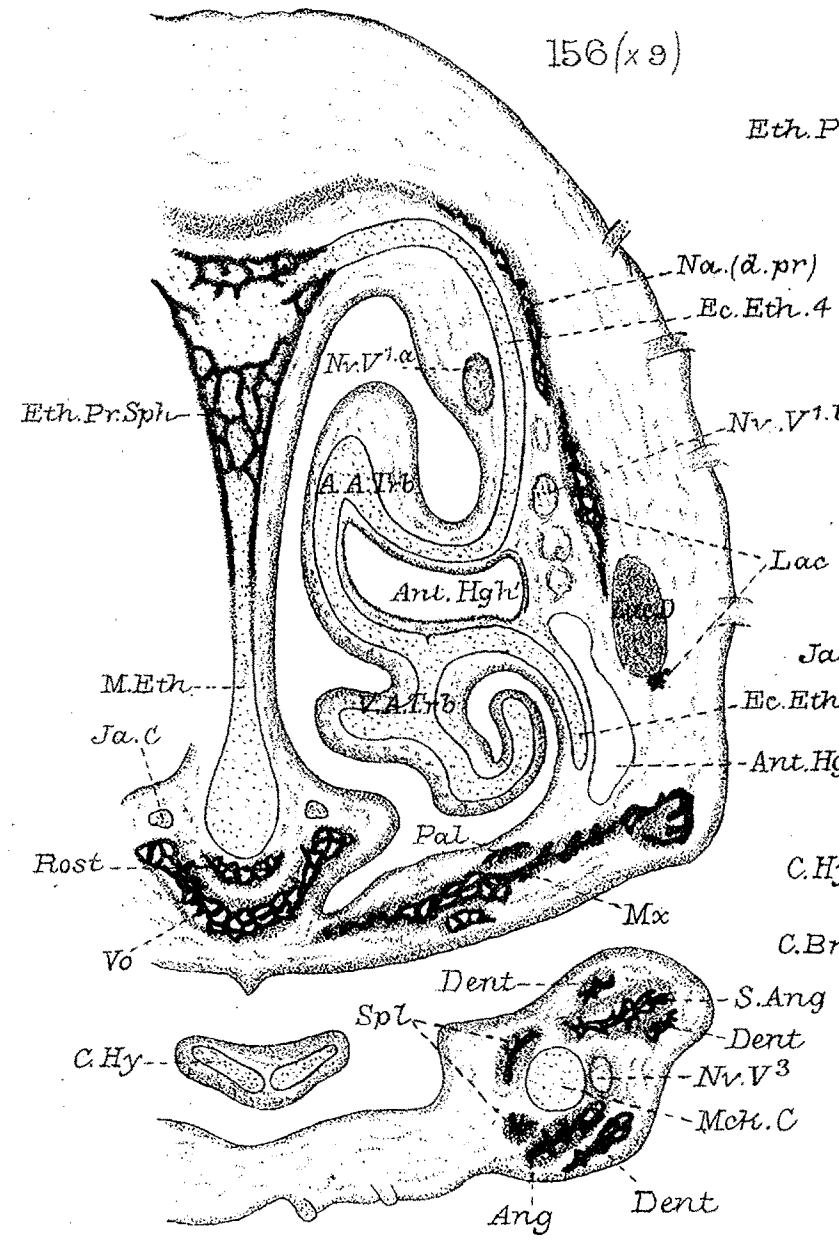

157 (×9)

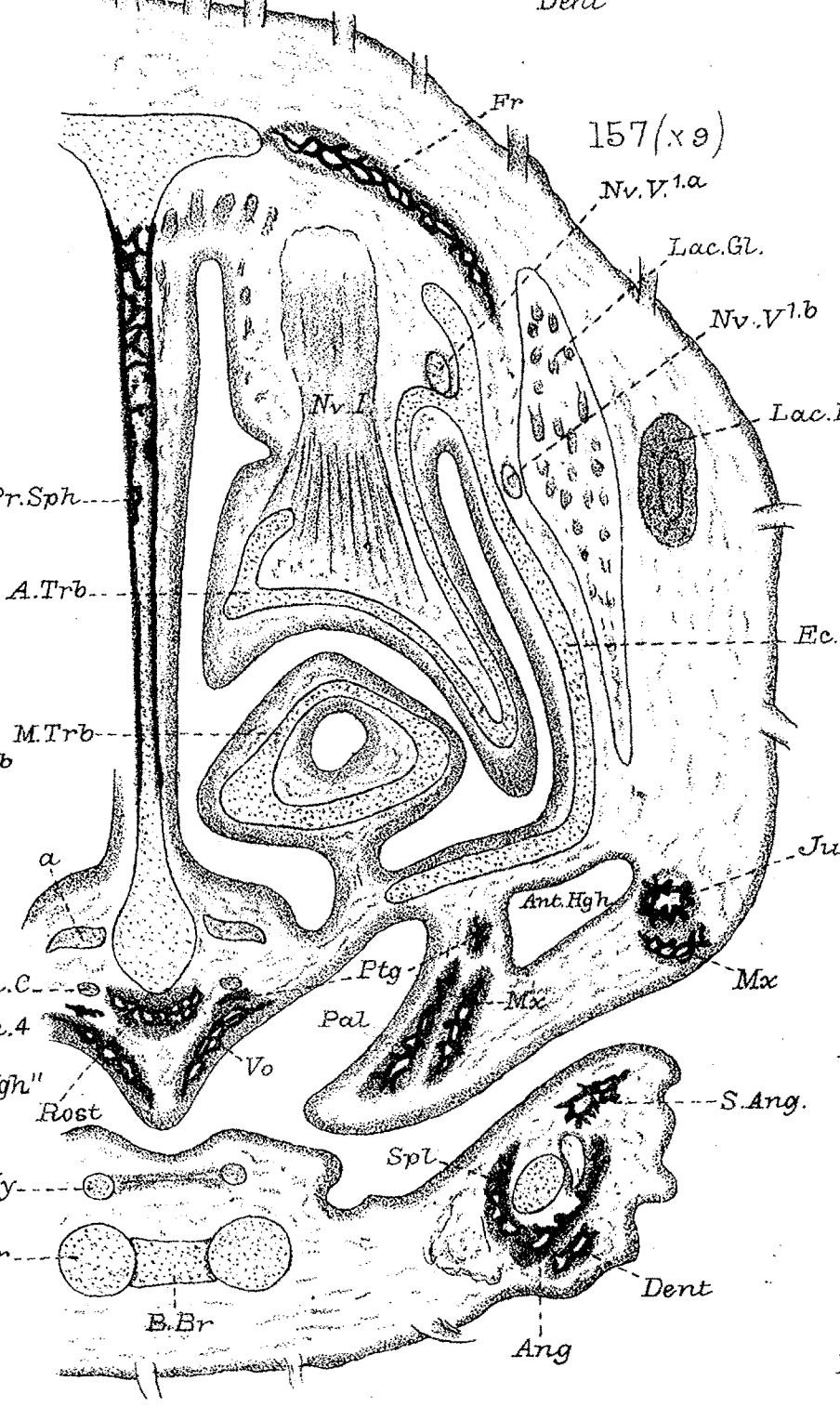

158 (×9)

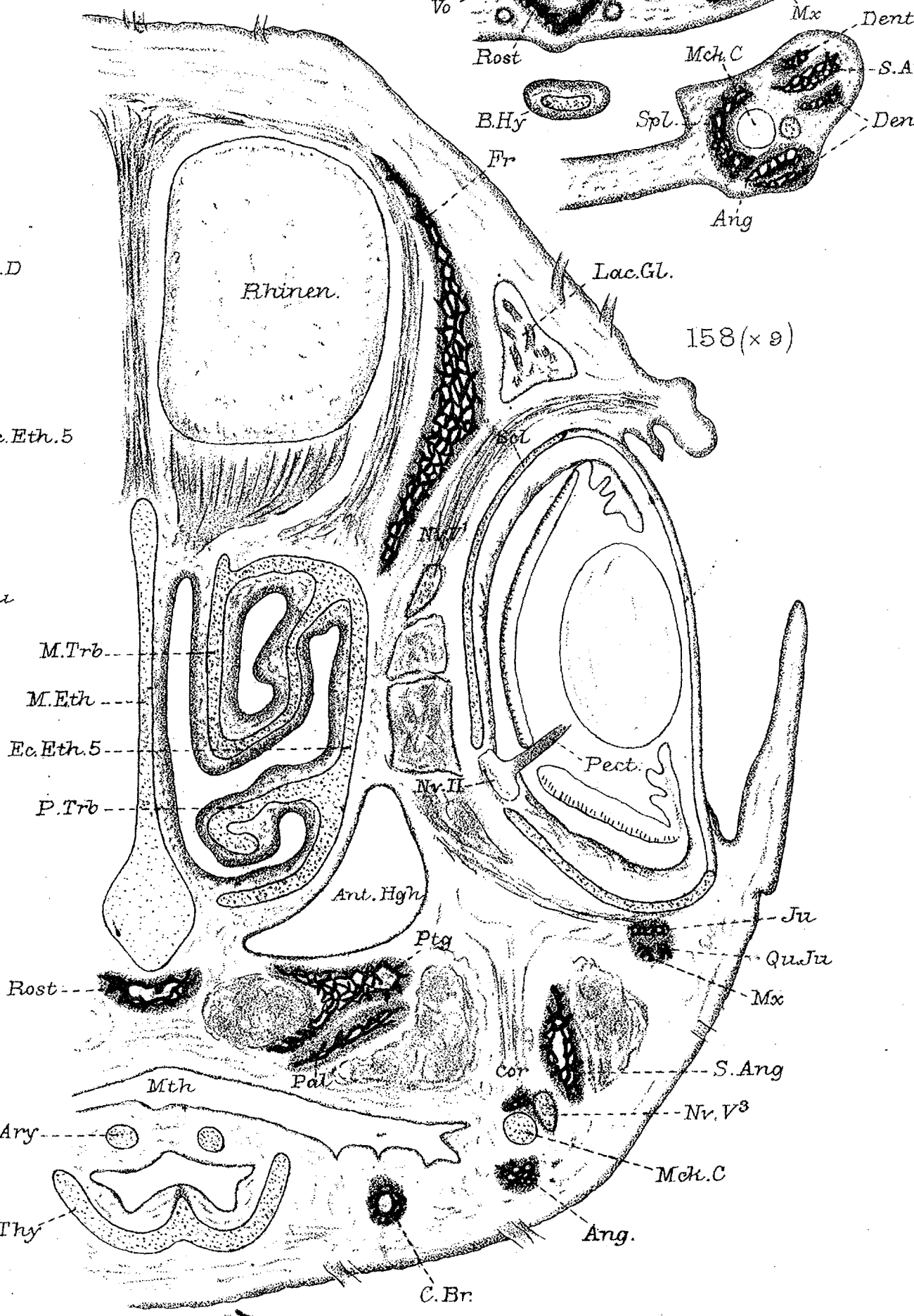

160 (×9)

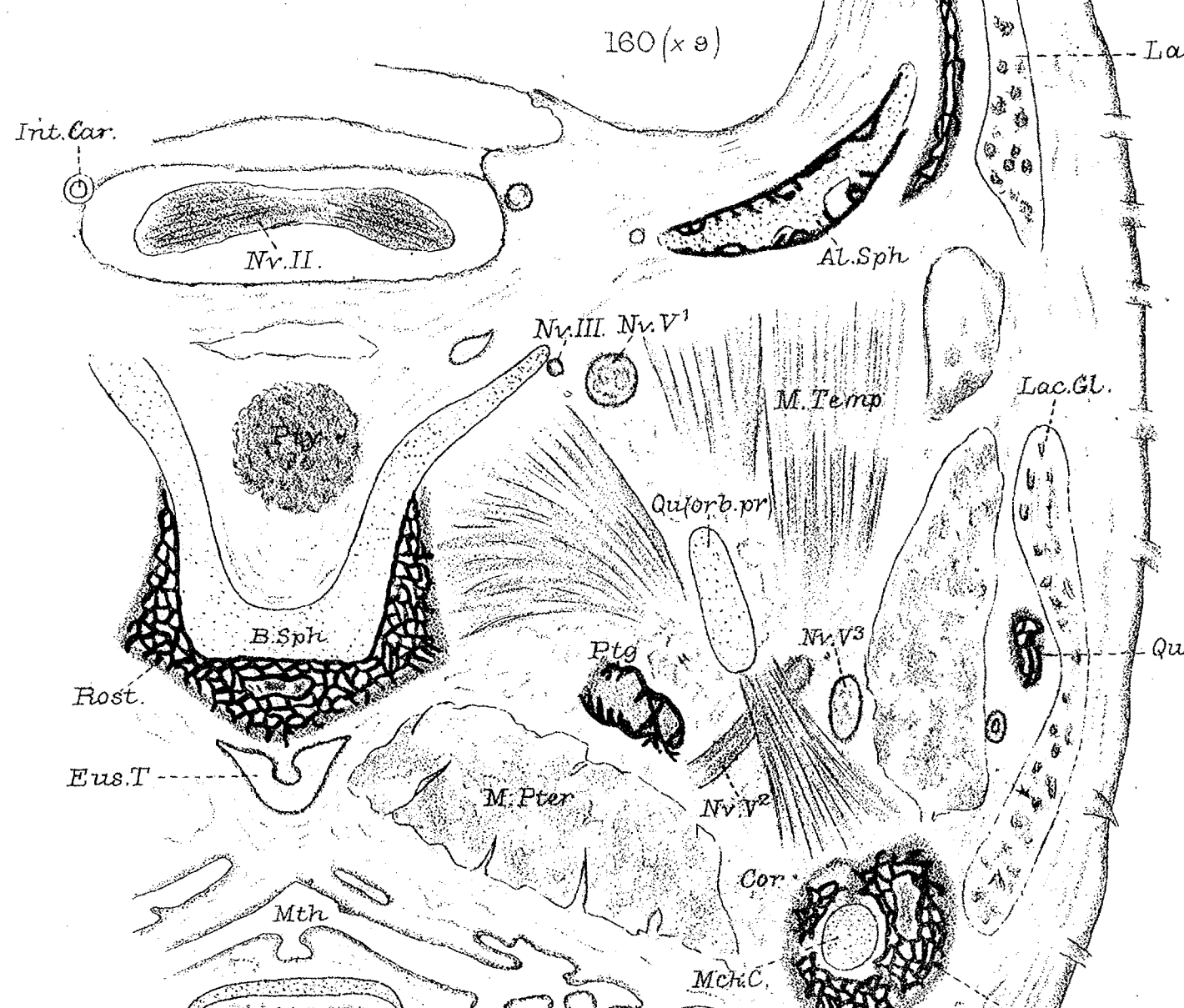

159 (×9)

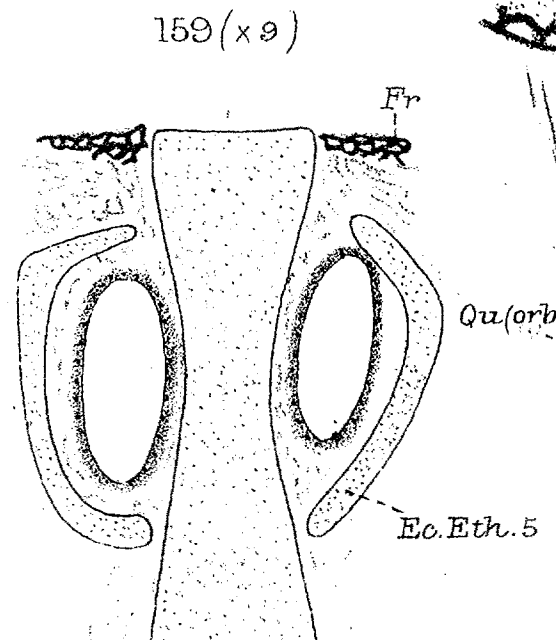

161 (×9)

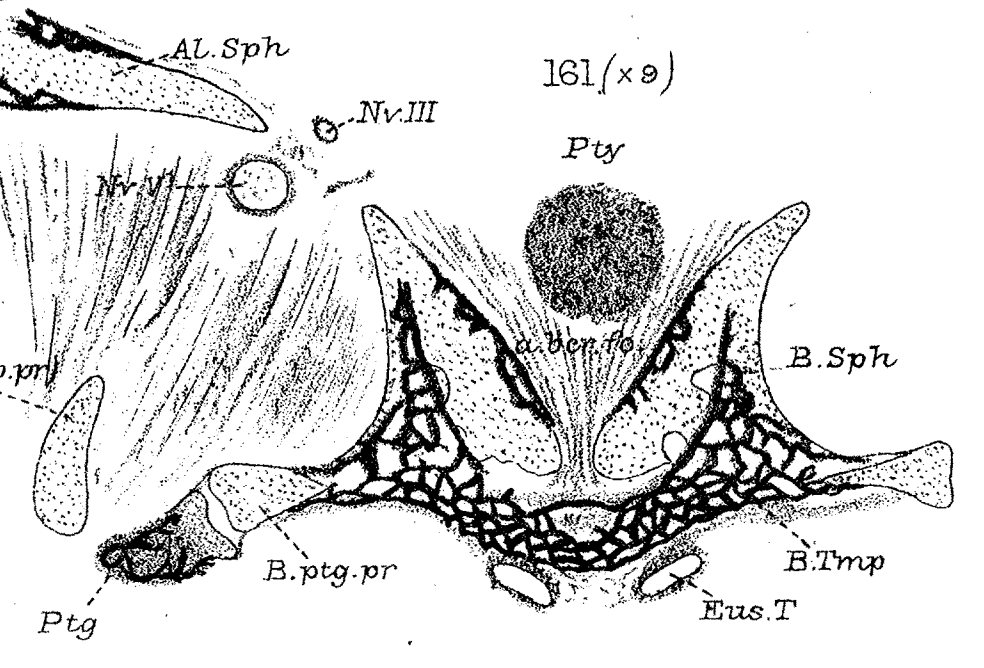

162 (×9)

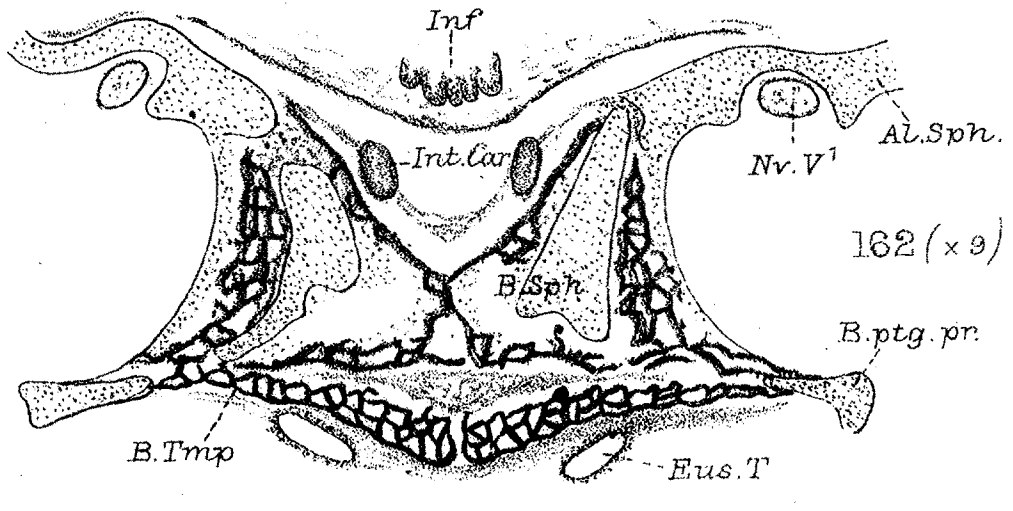

T.J.P. ad nat. del^t. M.P. Parker chr. lith.   West, Newman imp.

APTERYX. Skull: Stage H.

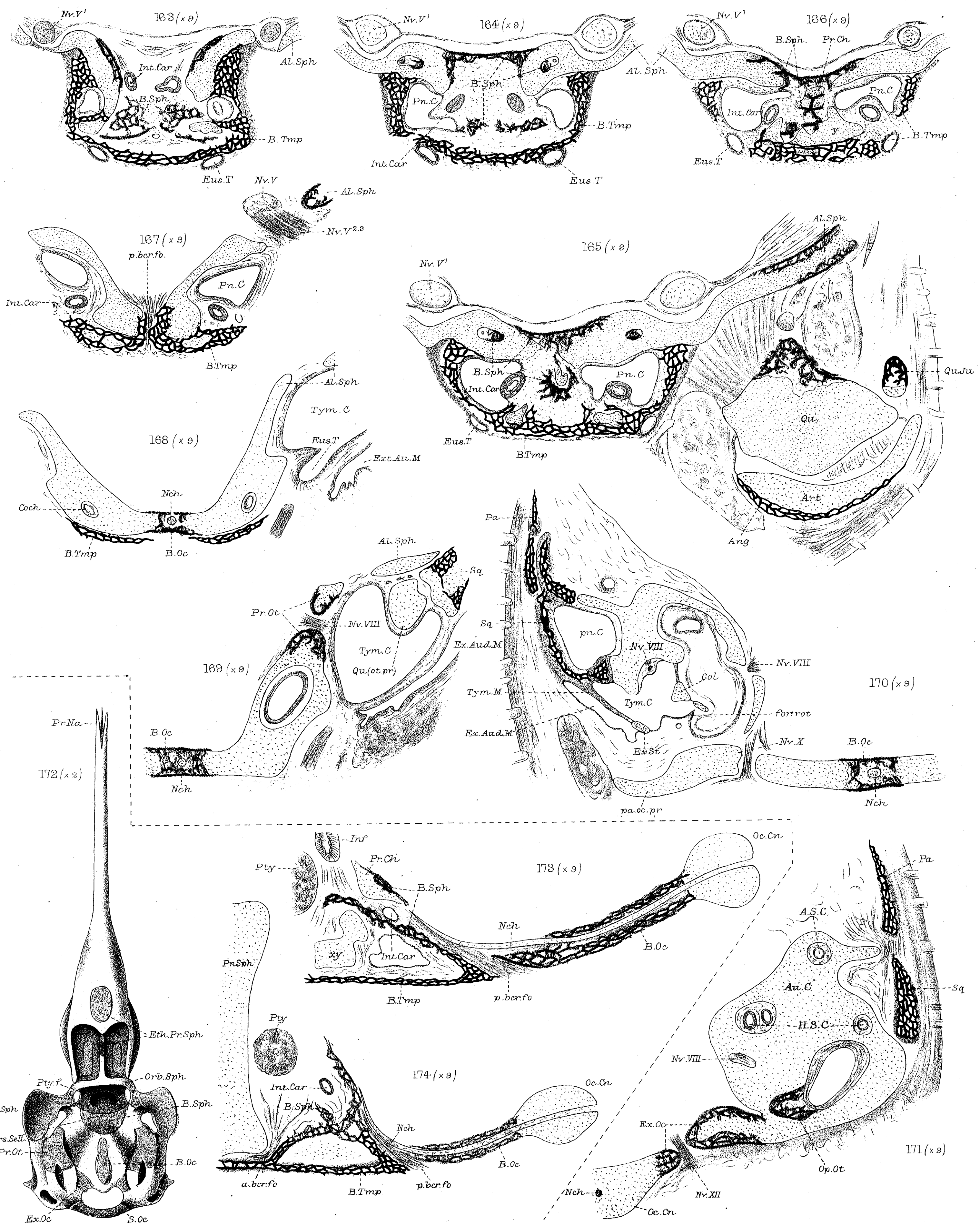

T.J.P. ad nat. del^t. M.P. Parker chr. lith.

West, Newman imp.

APTERYX. Skull: Stages H and I.

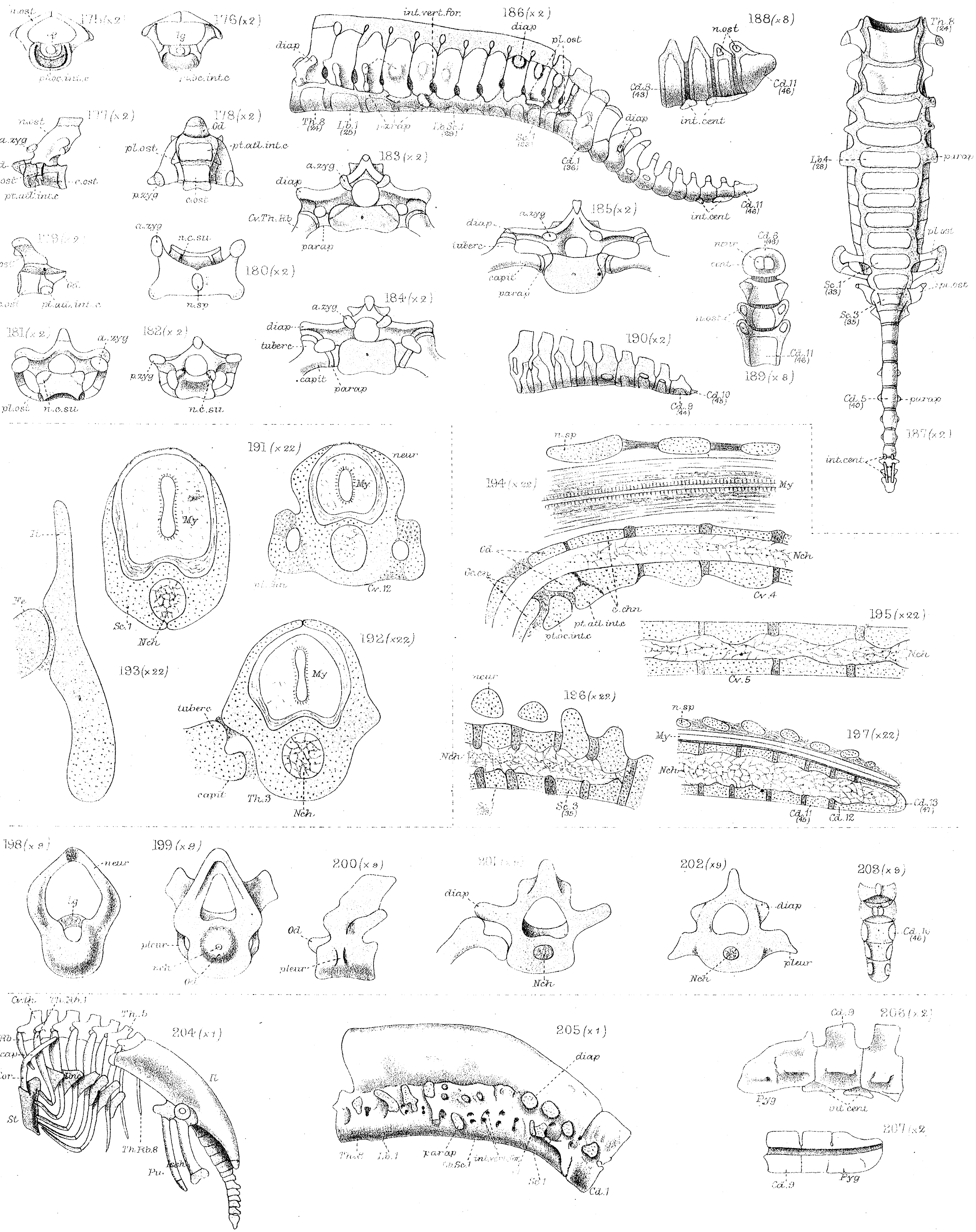

APTERYX. Vertebral column & ribs.

T.J.P. ad nat. del^t
M.P. Parker chr. lith.
West, Newman imp.

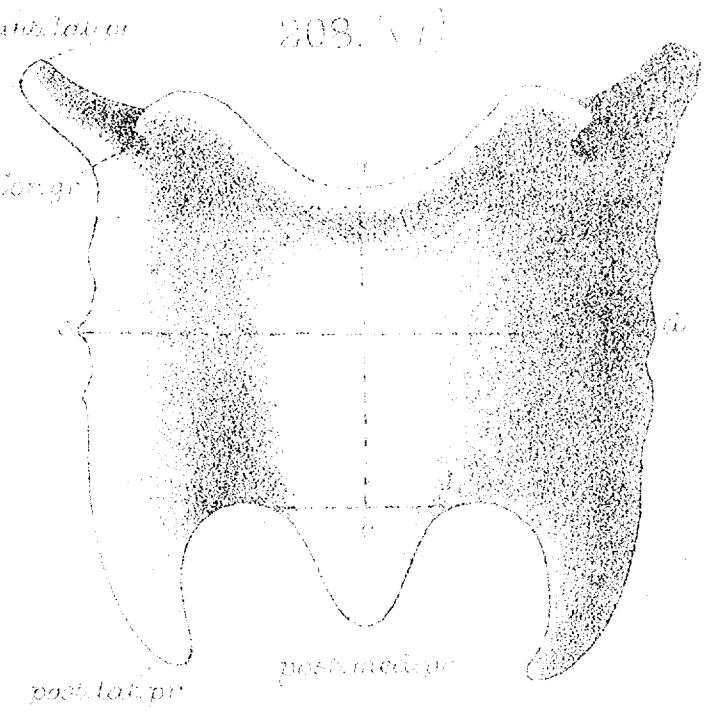
208. (× 1)

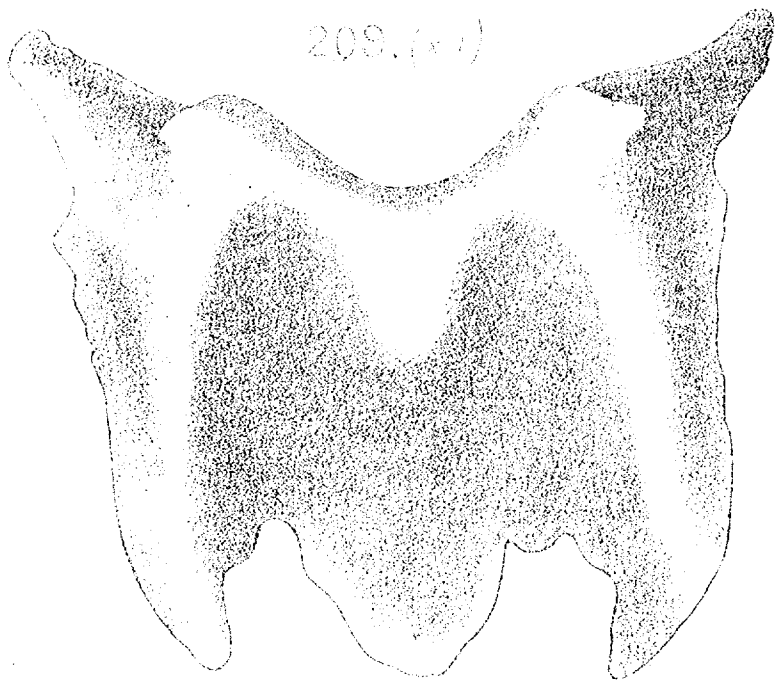
209. (× 1)

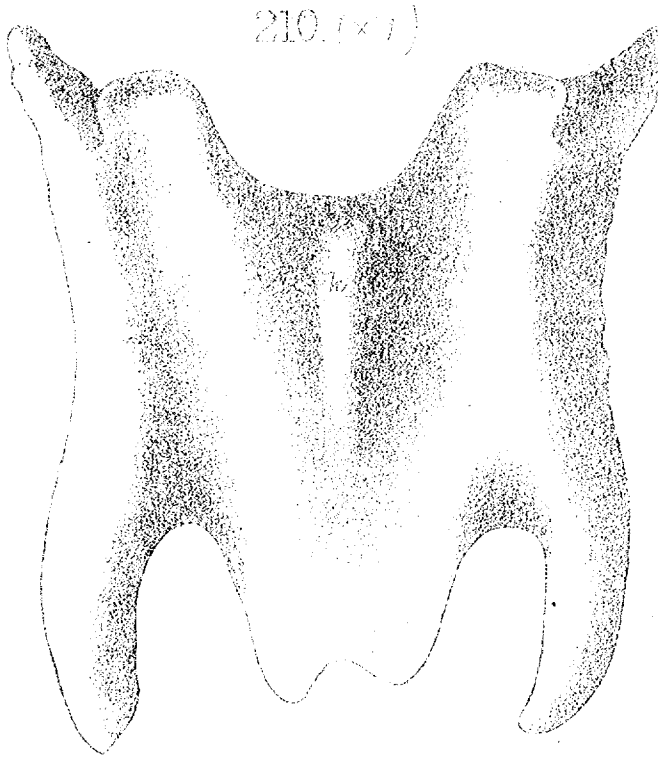
210. (× 1)

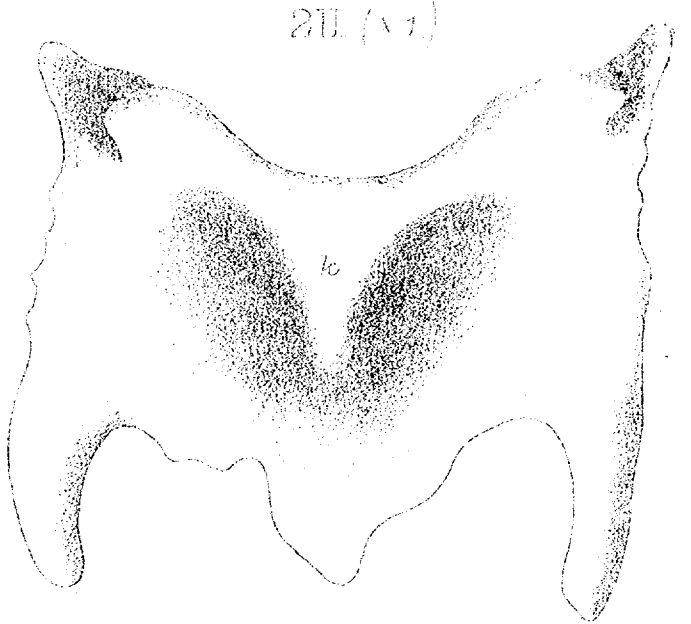
211. (× 1)

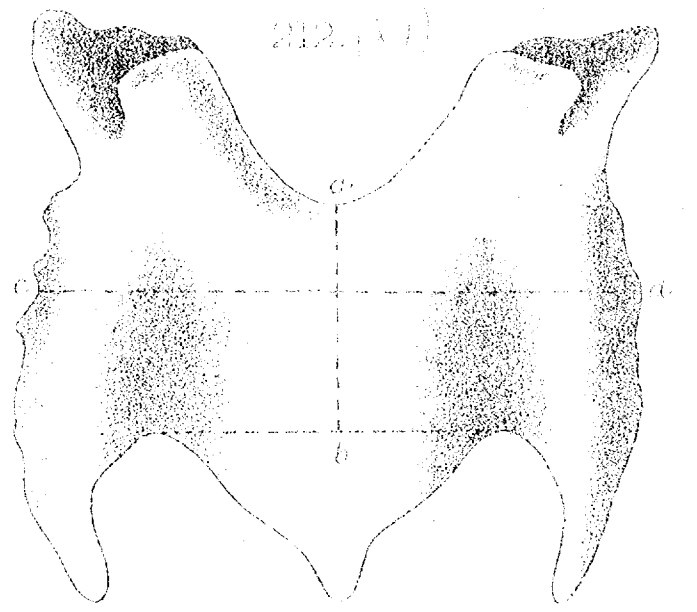
212. (× 1)

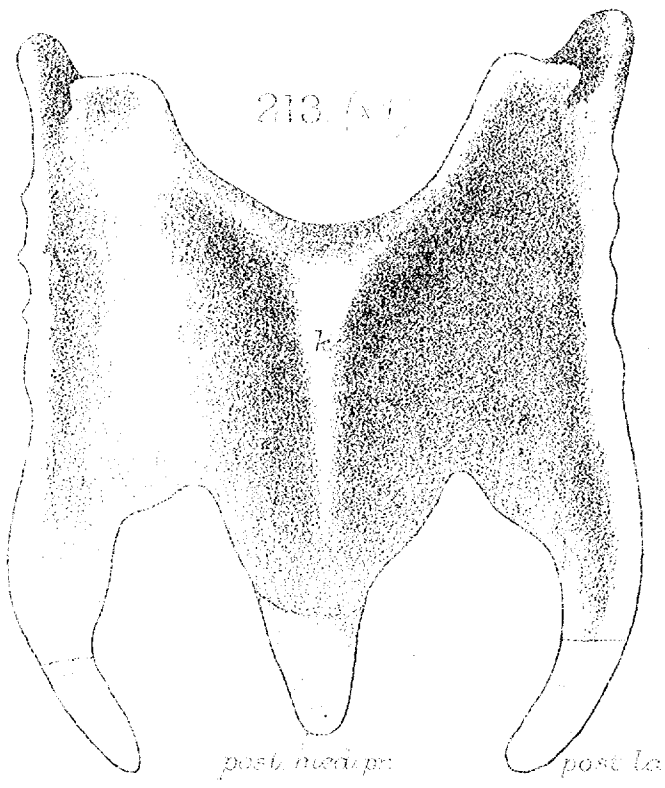
213. (× 1)

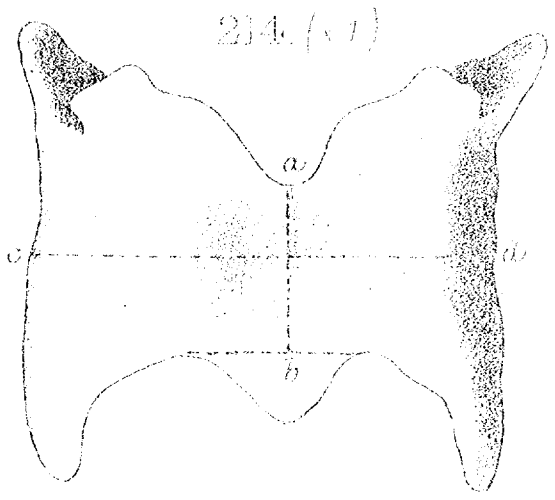
214. (× 1)

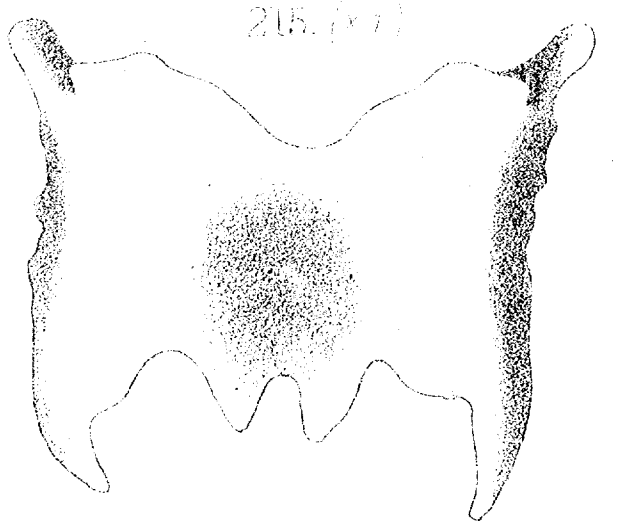
215. (× 1)

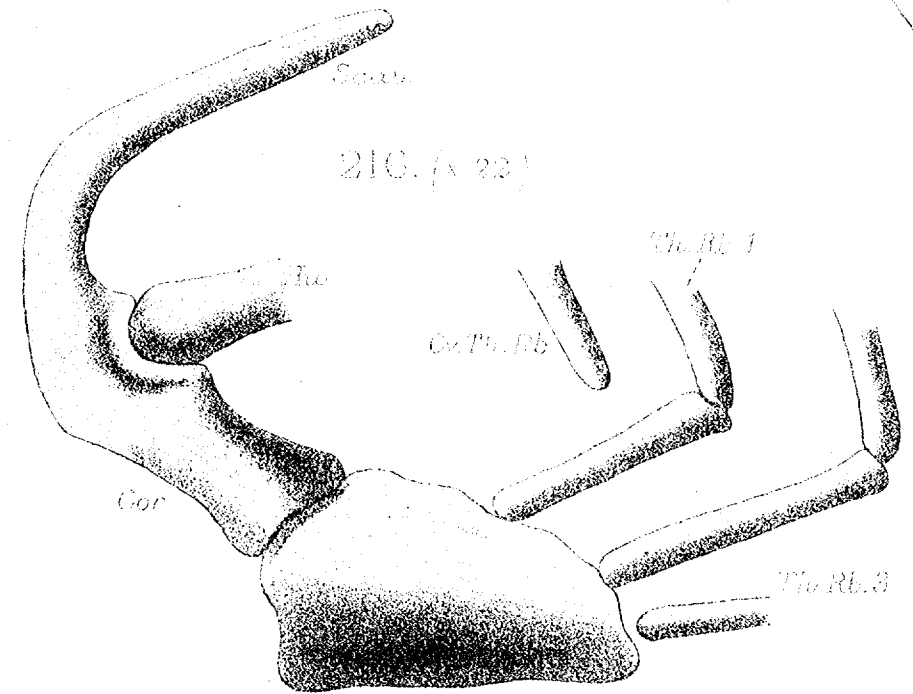
216. (× 22)

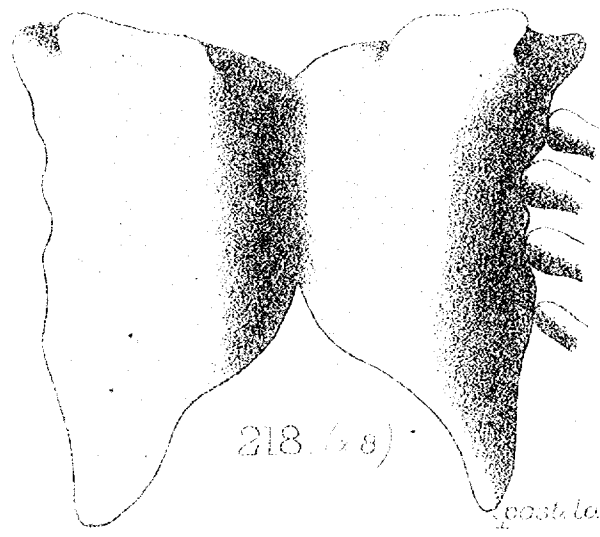
218. (× 8)

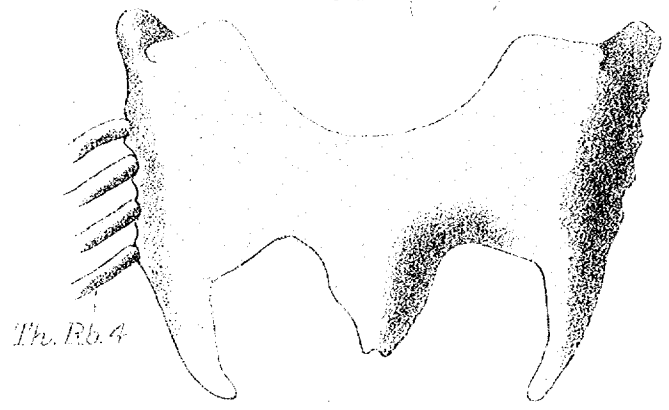
220. (× 2·5)

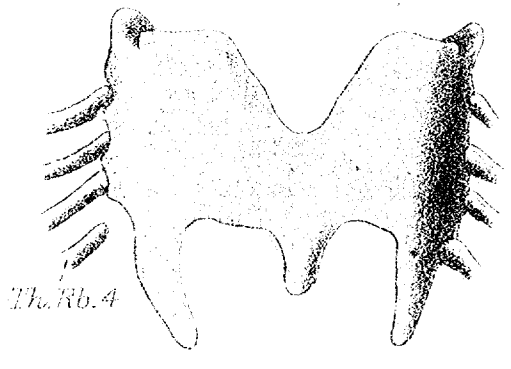
221. (× 2·5)


219. (× 8)

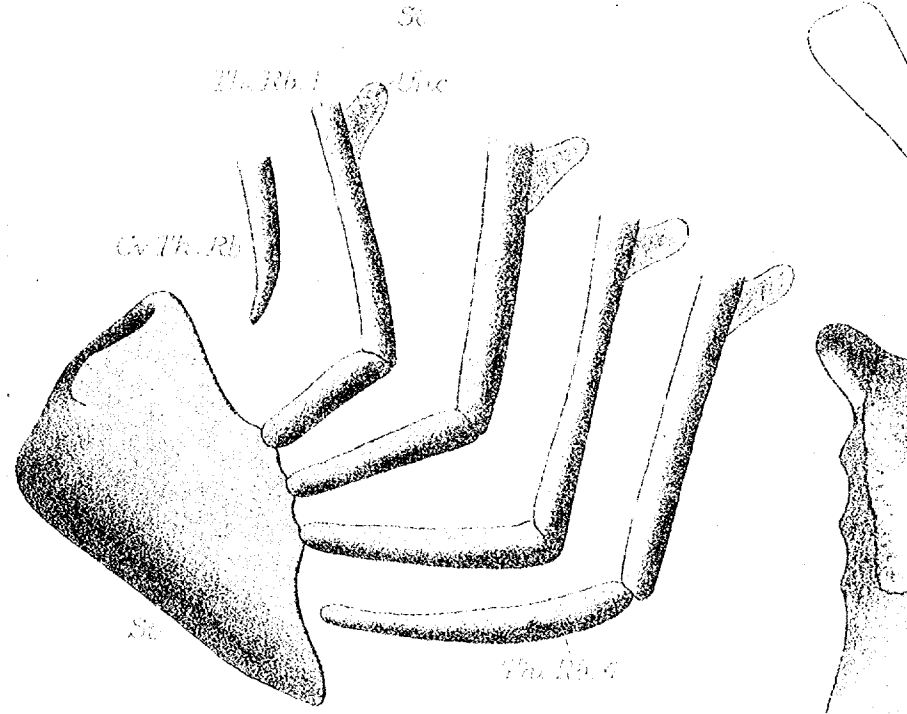
217. (× 2)

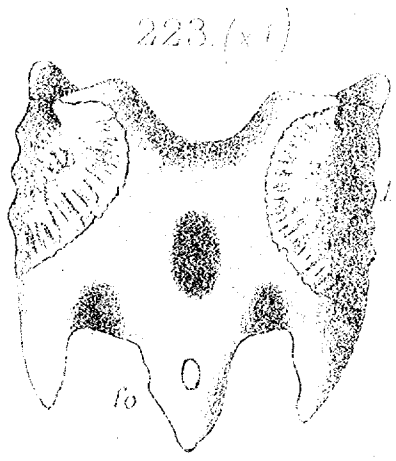
223. (× 1)

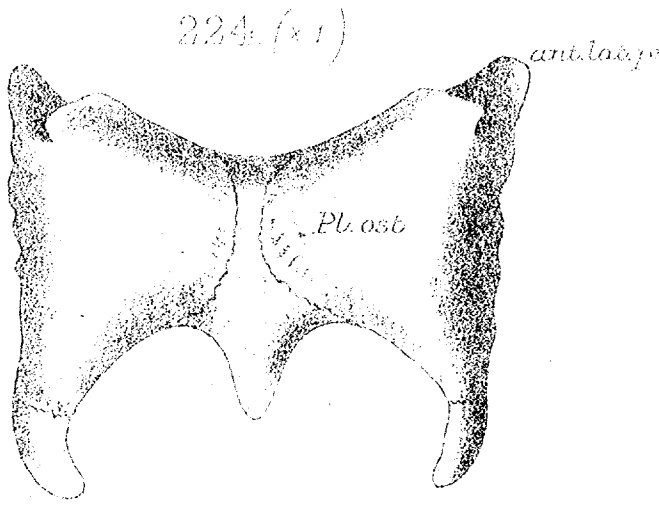
224. (× 1)

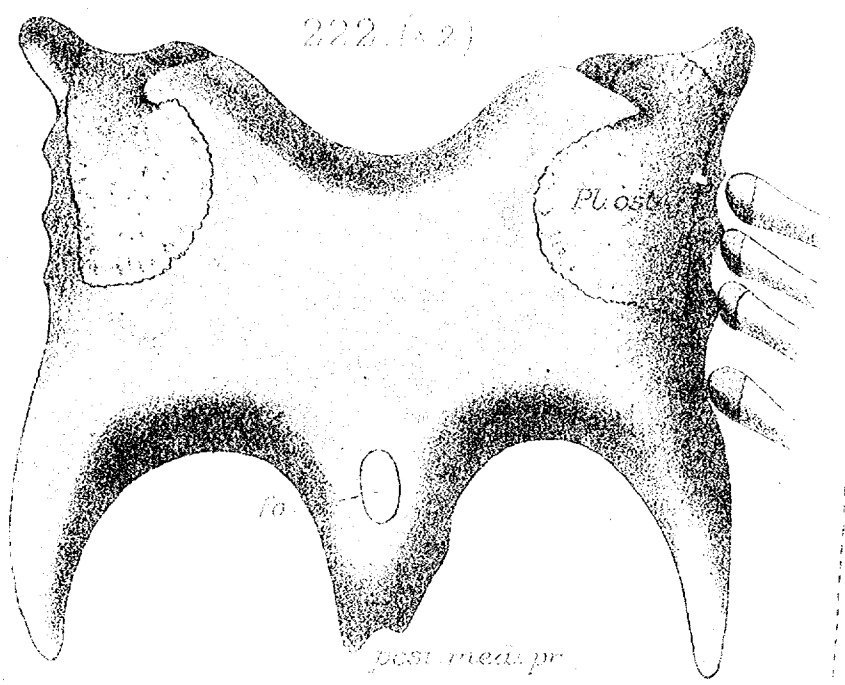
222. (× 2)

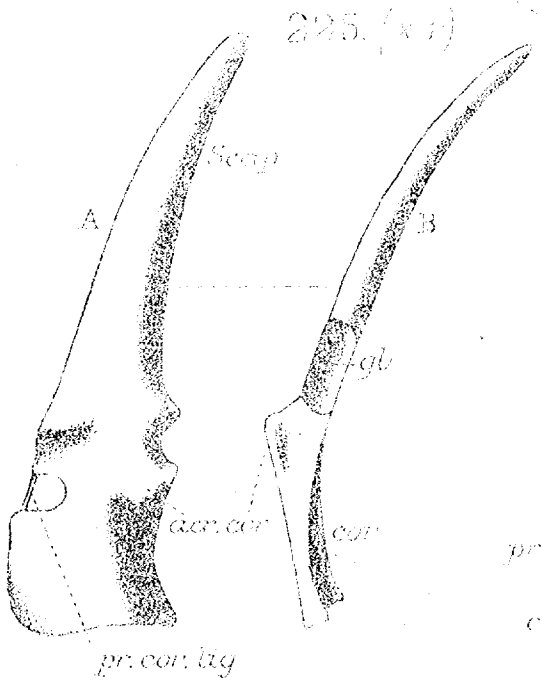
225. (× 1)

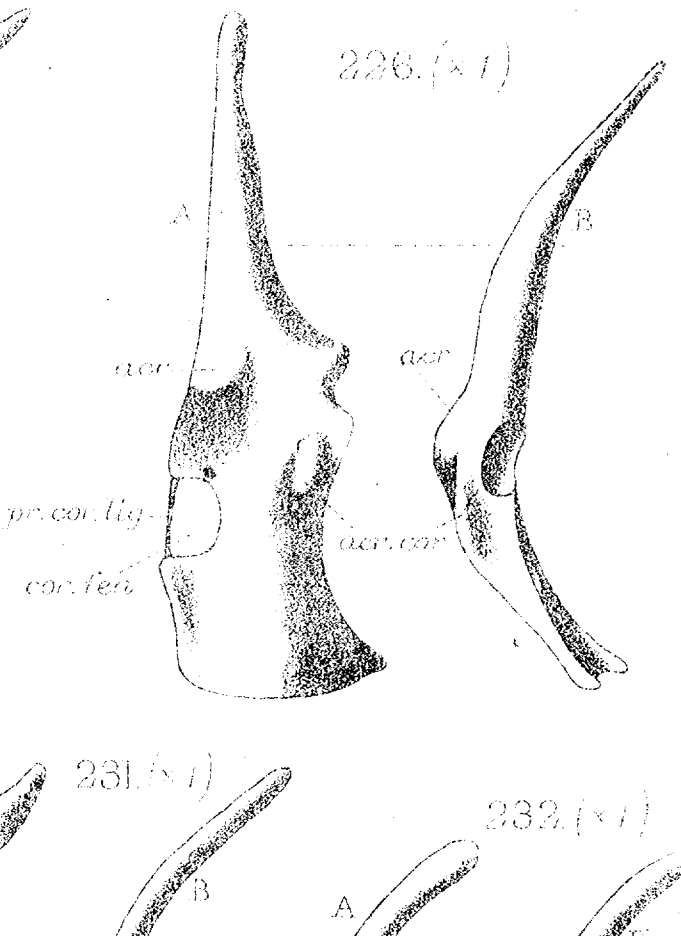
226. (× 1)

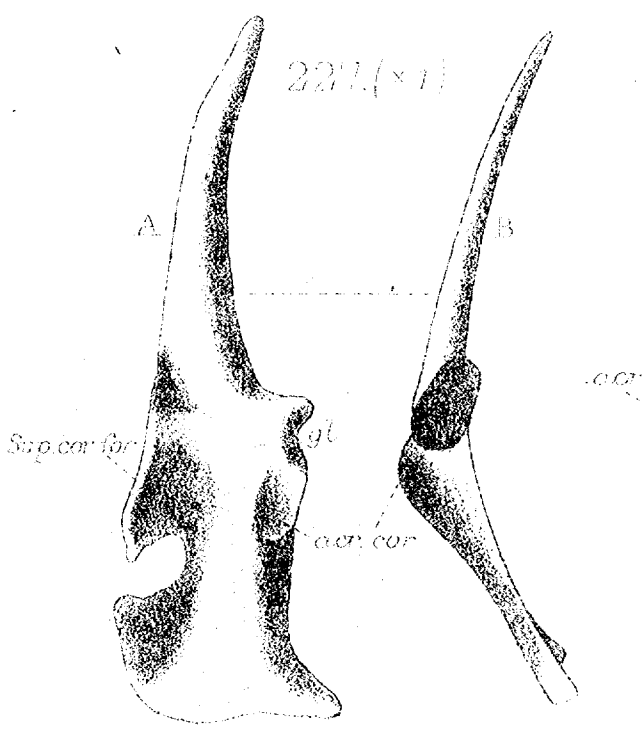
227. (× 1)

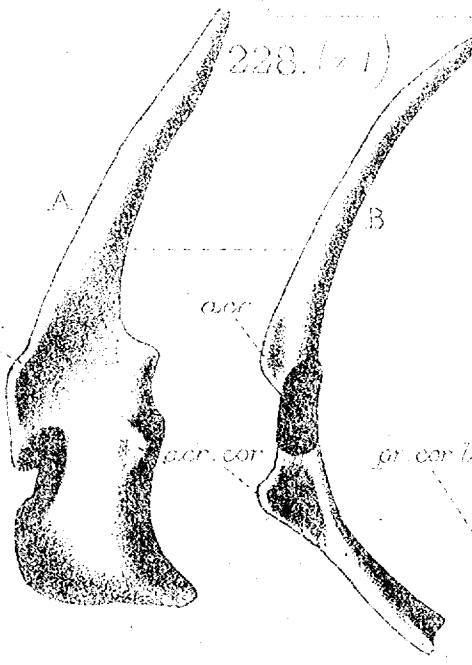
228. (× 1)

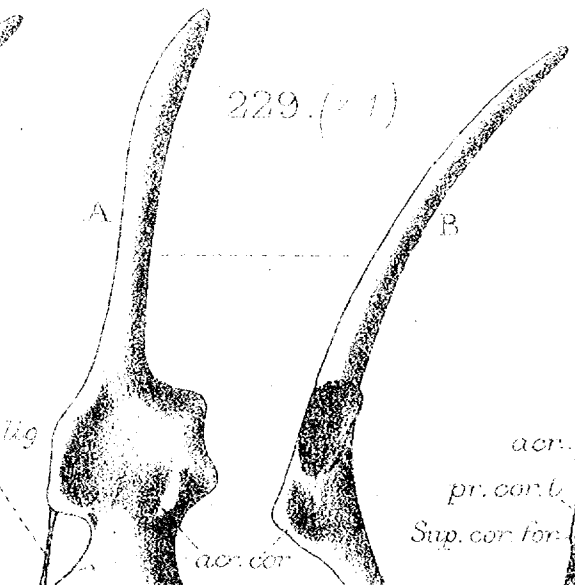
229. (× 1)

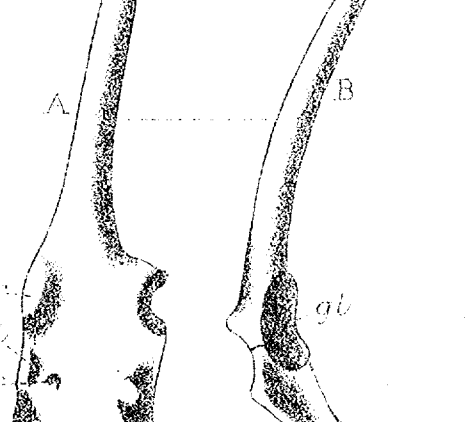
230. (× 1)

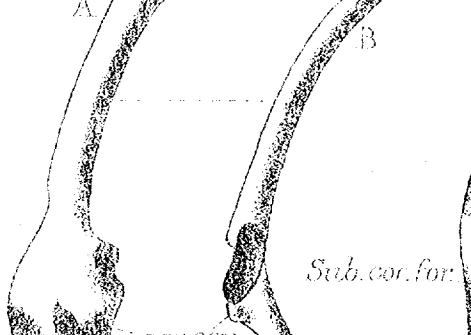
231. (× 1)


232. (× 1)

T.J.P. ad nat. del.
M.P. Parker chr. lith.

APTERYX. Sternum and Shoulder-Girdle.

West, Newman imp.

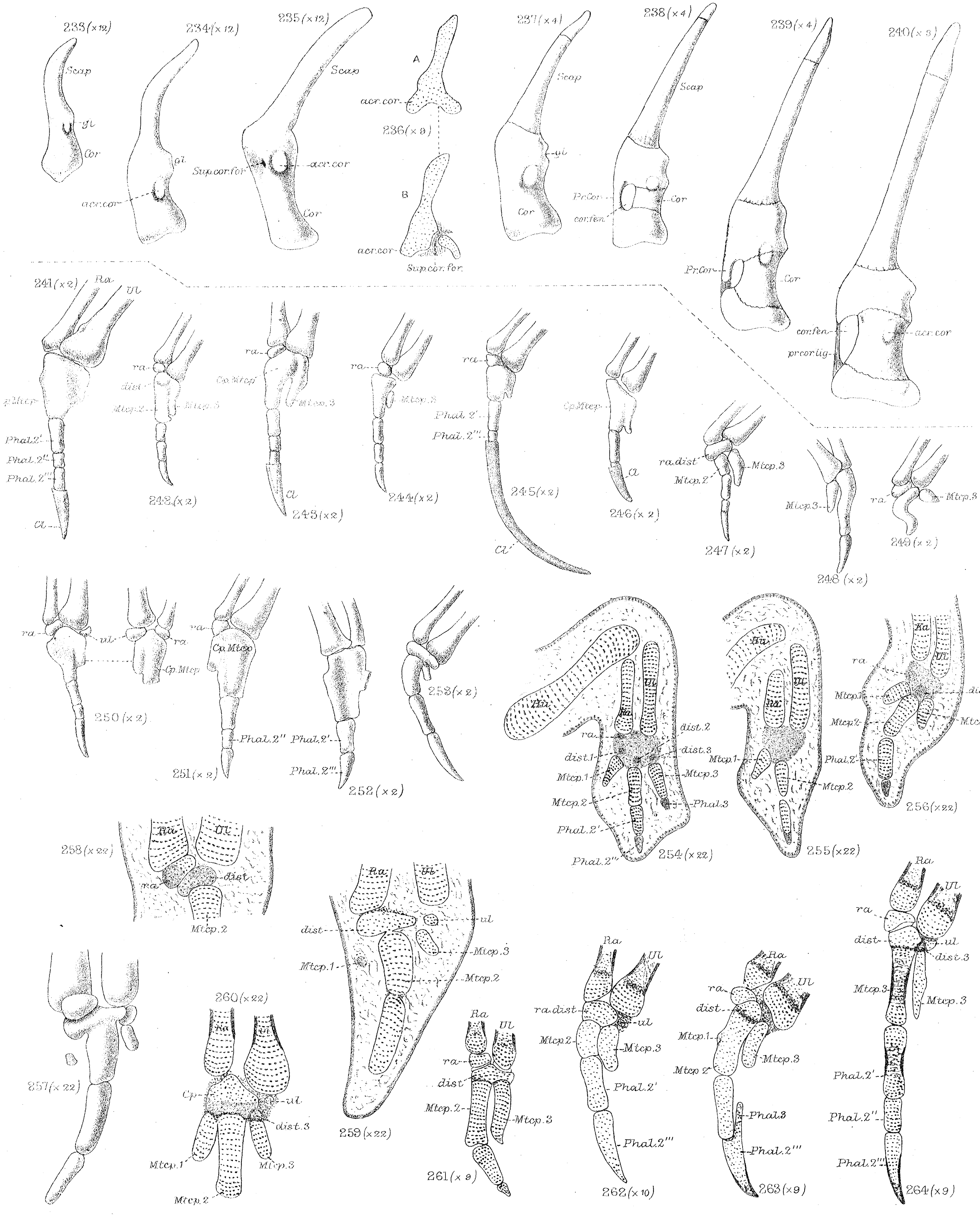

T.J. Pad nat. del.
M.P. Parker chr. lith.

APTERYX. Shoulder-Girdle and Fore-limb.

West, Newman imp.

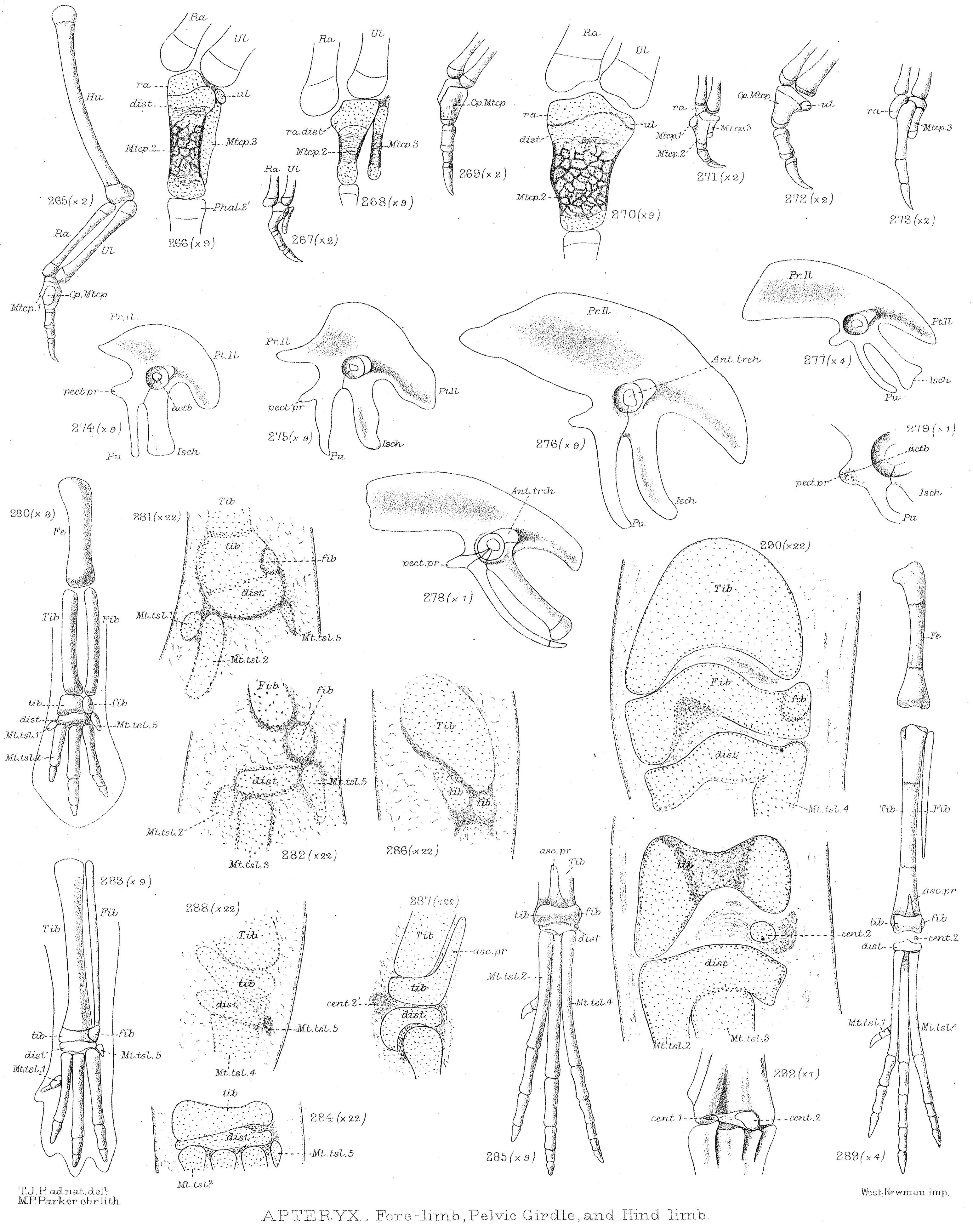

T. J. P. ad nat. delt
M. P. Parker chr. lith

West, Newman imp.

APTERYX. Fore-limb, Pelvic Girdle, and Hind-limb.

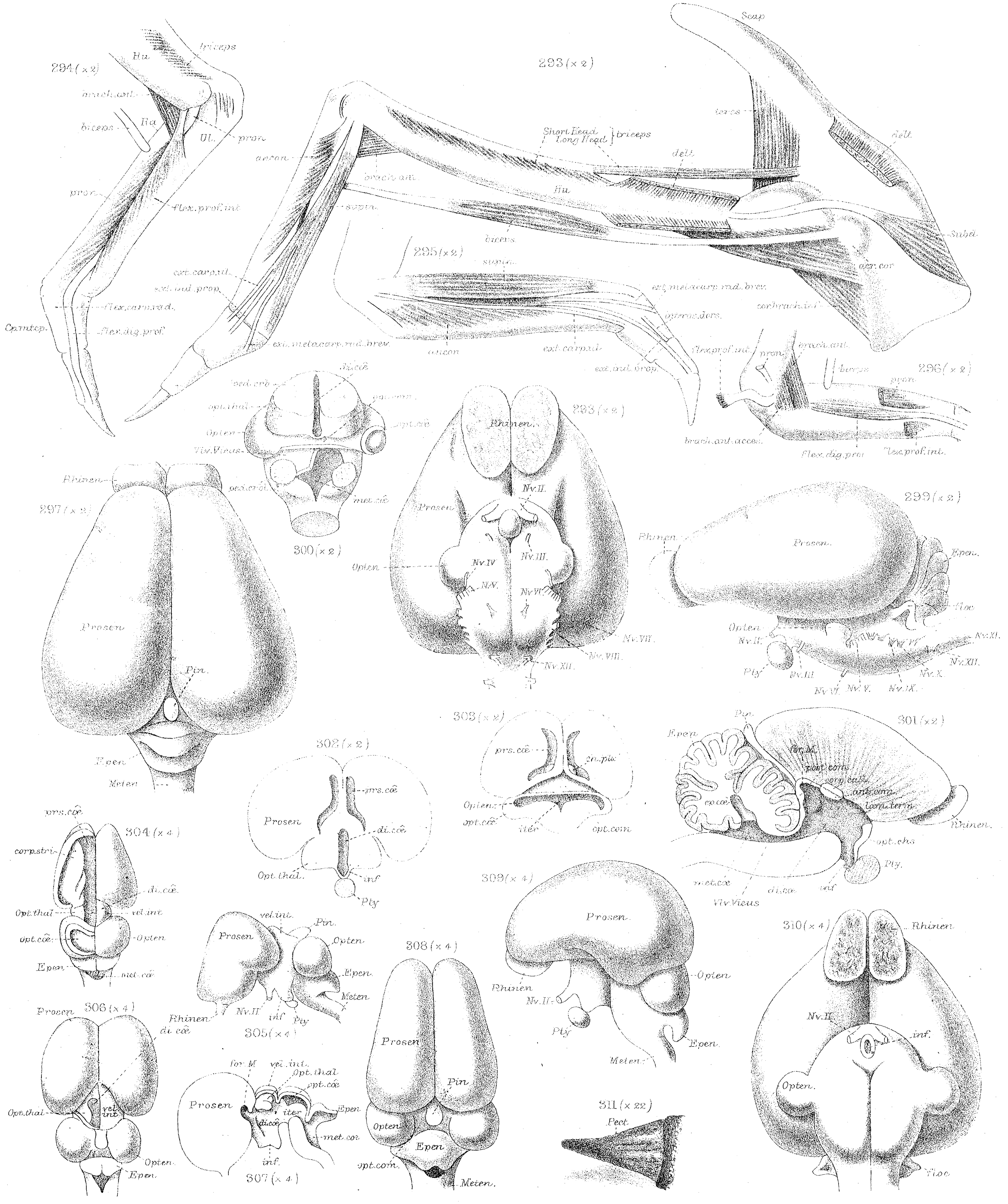

T. J. P. ad nat. delt.
M. P. Parker chr. lith.

West, Newman imp.

APTERYX. Muscles of Wing Brain, and Pecten.

APTERYX. External Characters.

17 (× 22)

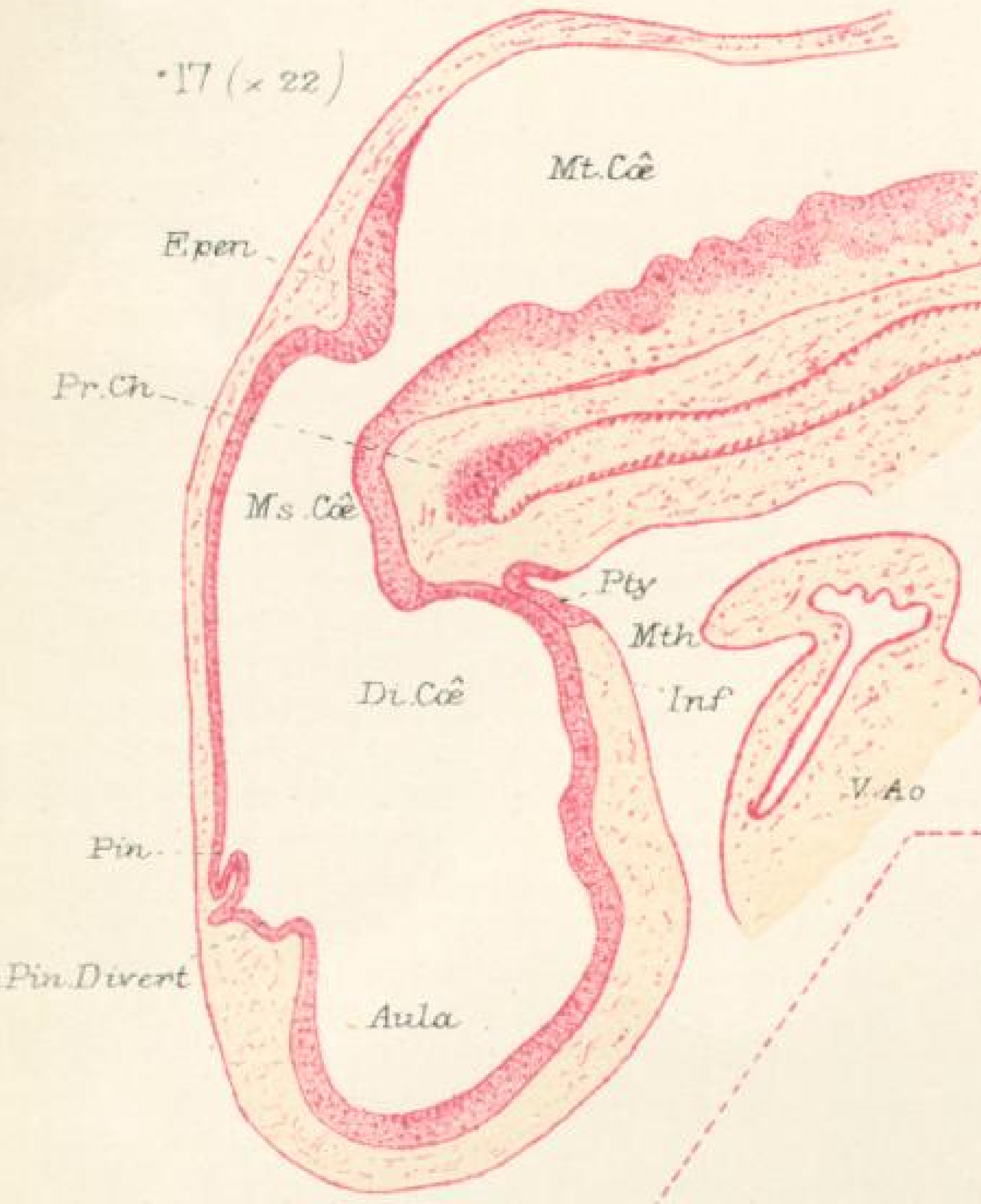

18 (× 150)

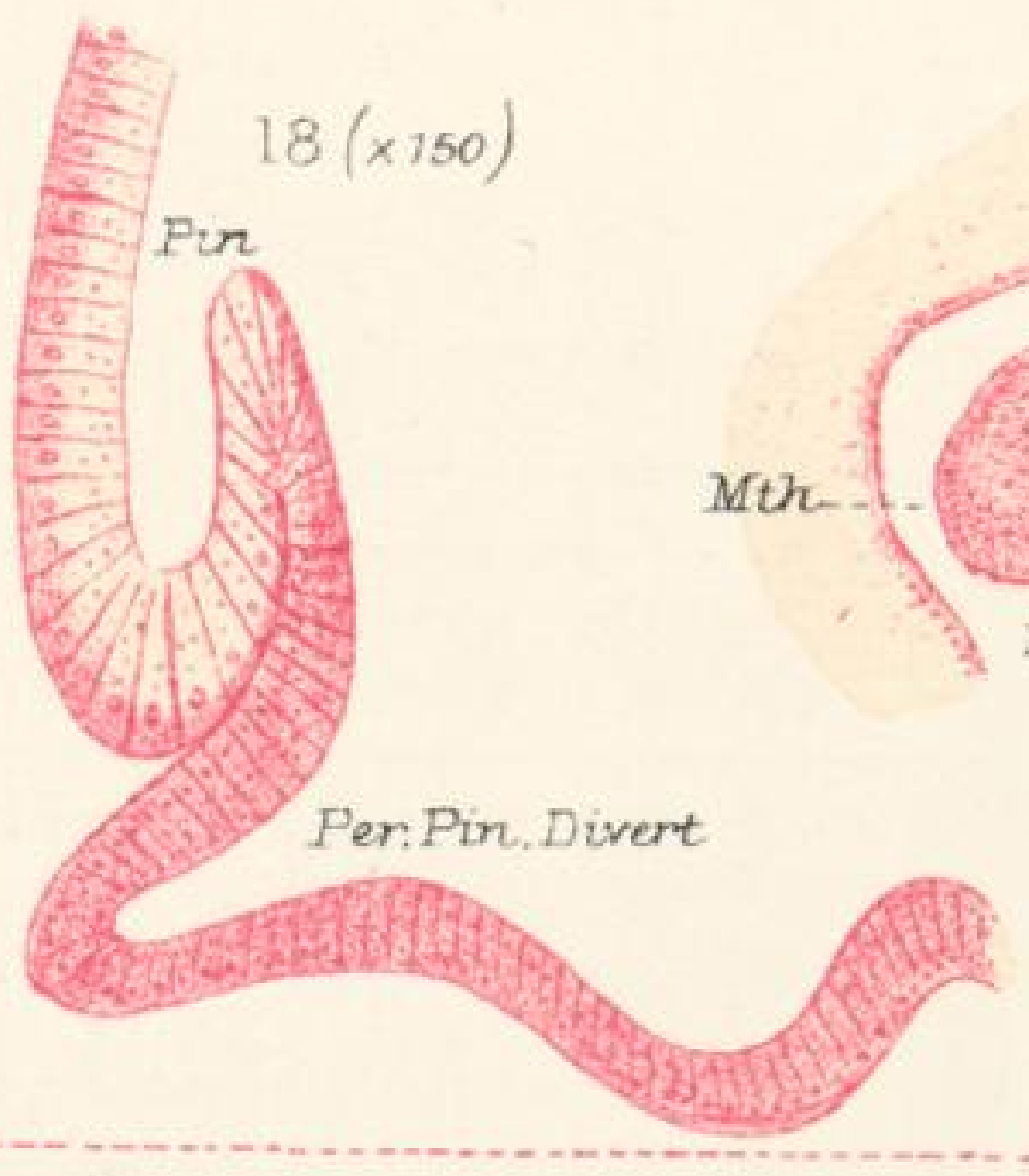

19 (× 22)

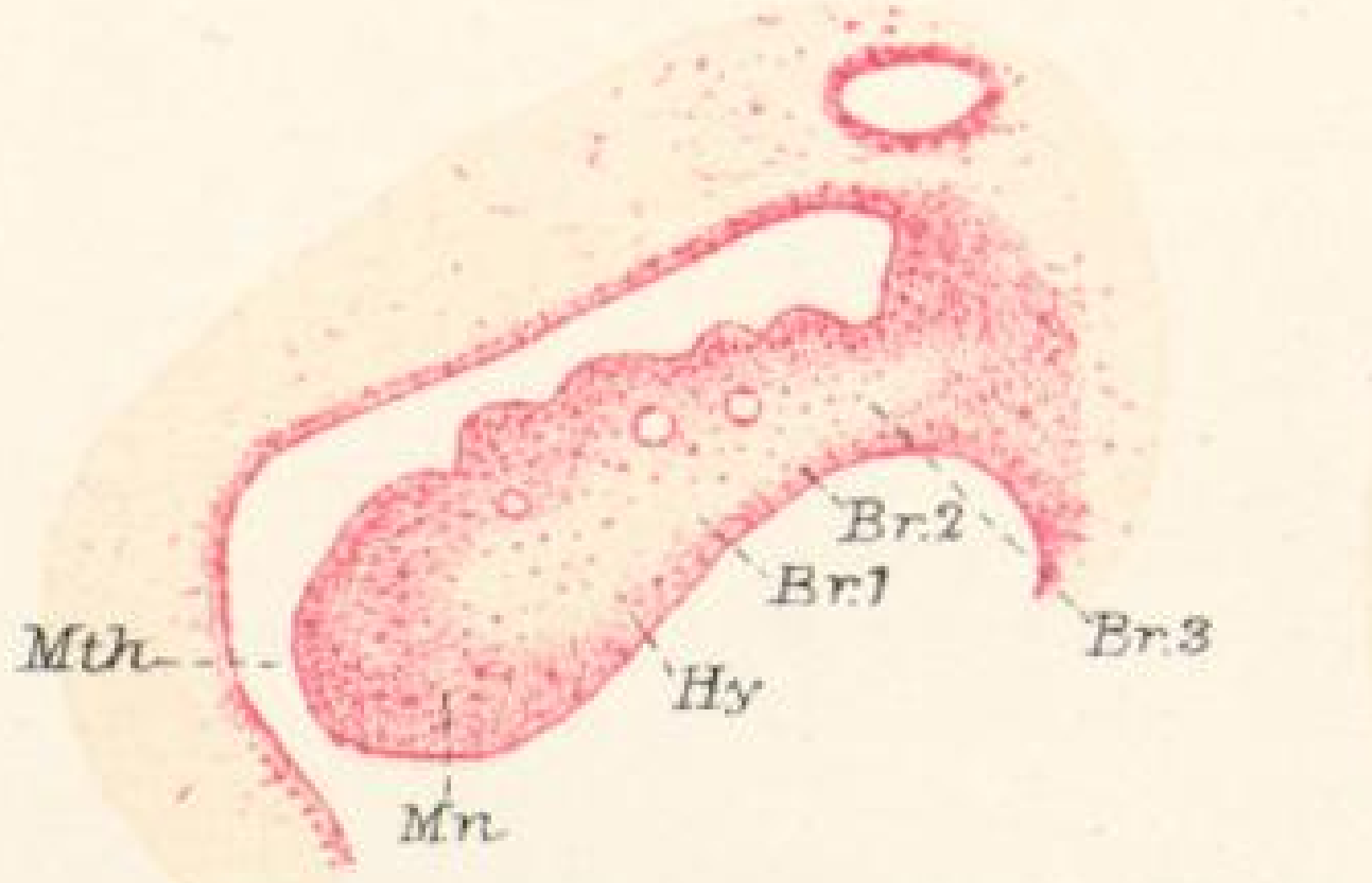

20 (× 22)

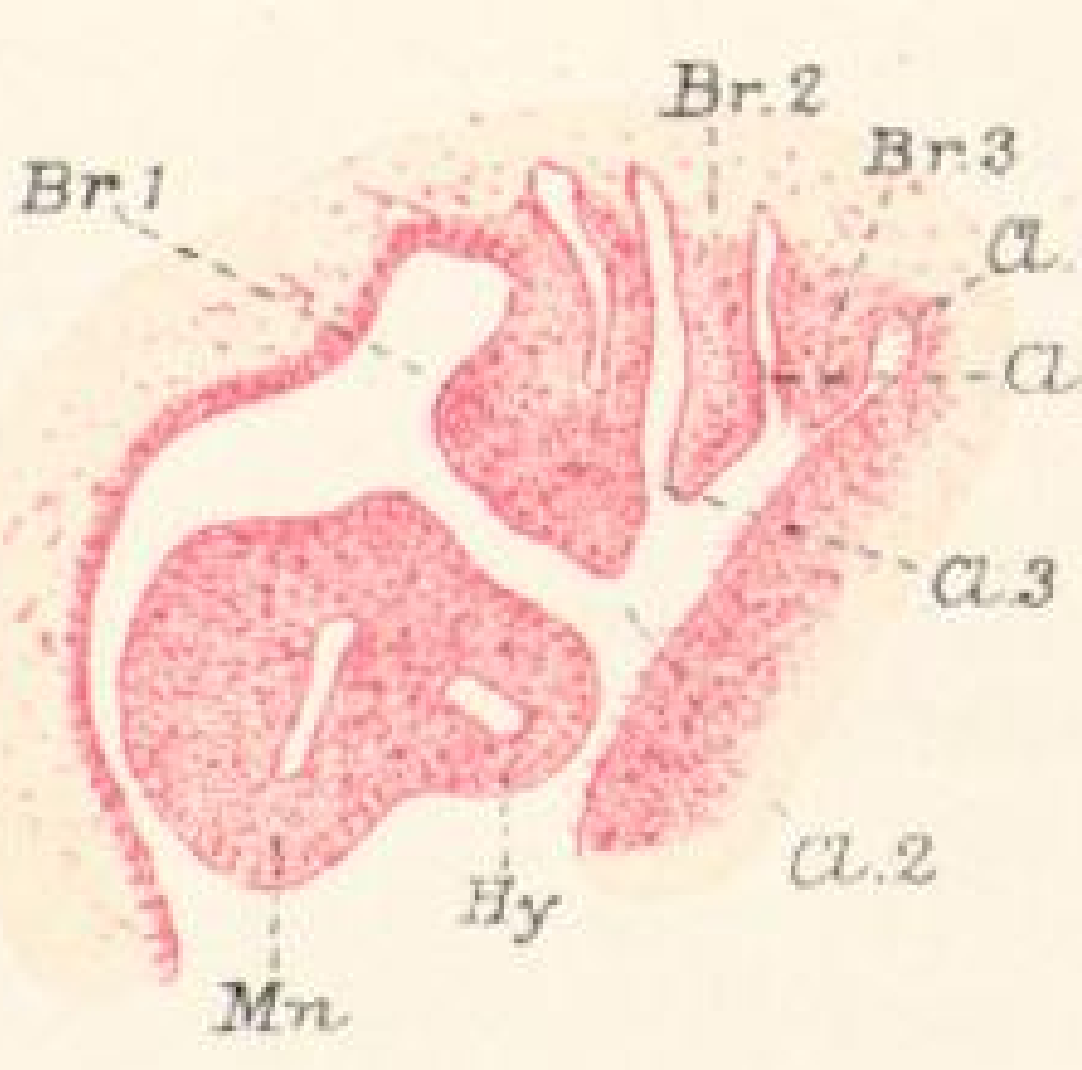

21 (× 22)

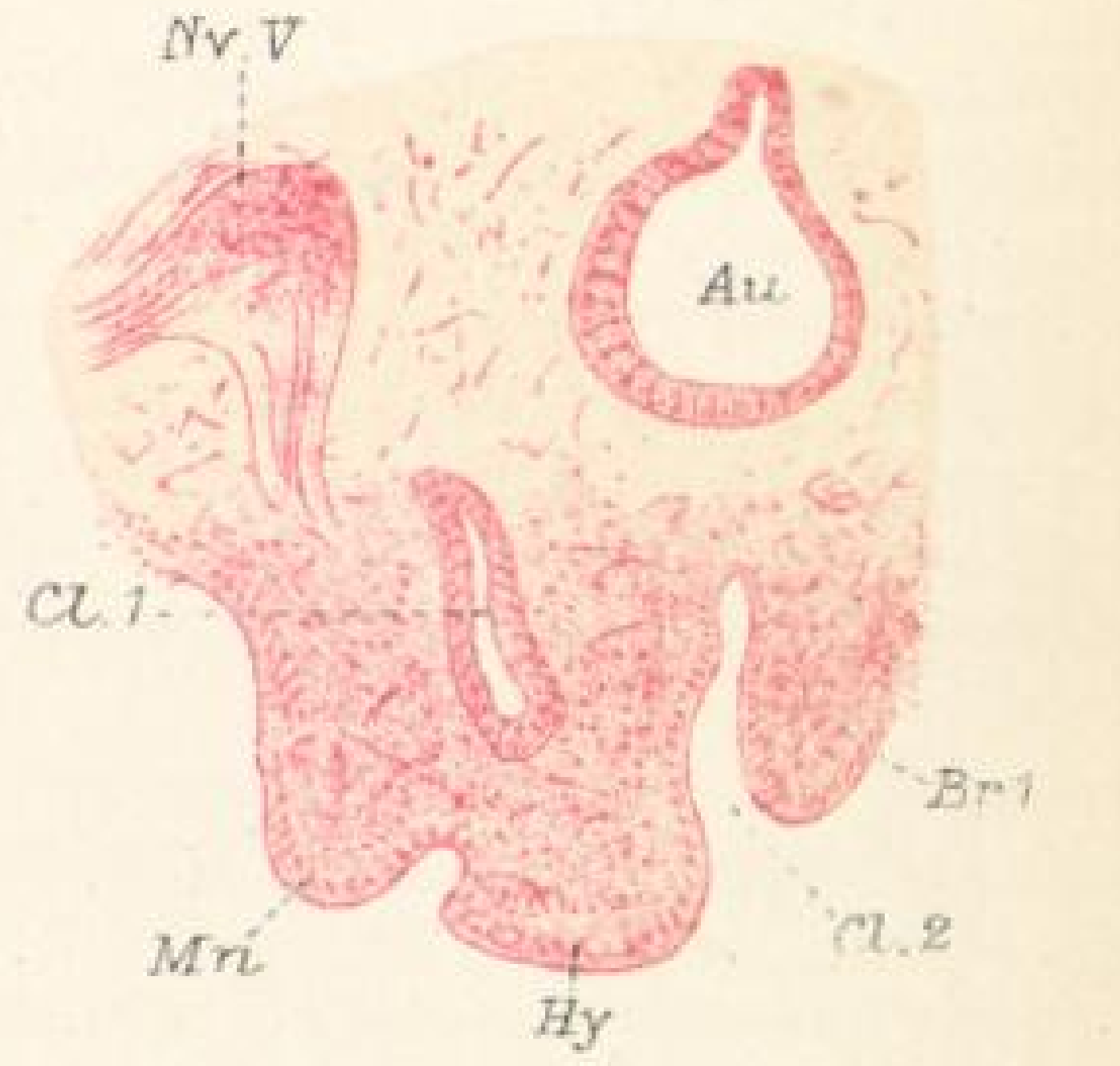

22 (× 22)

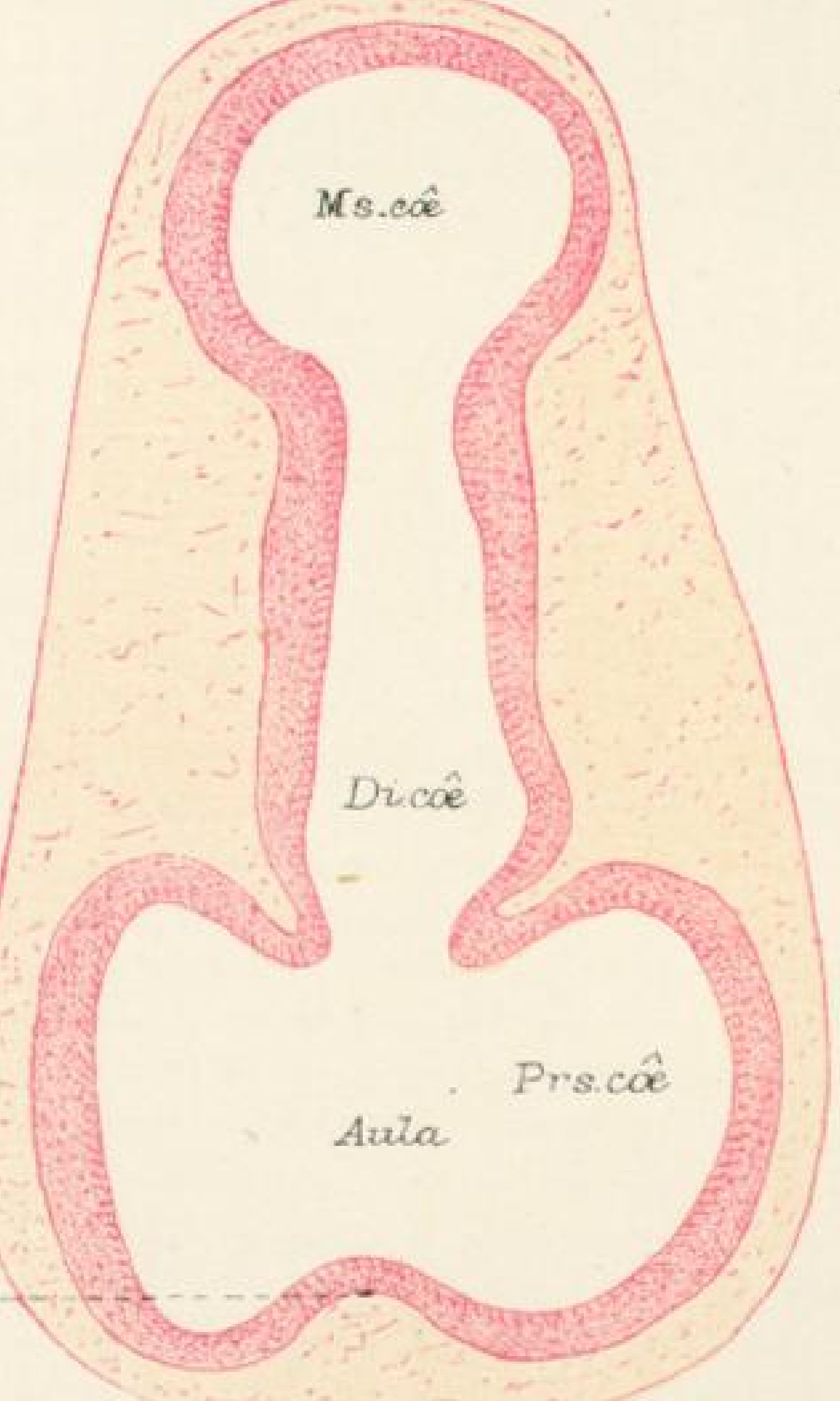

23 (× 22)

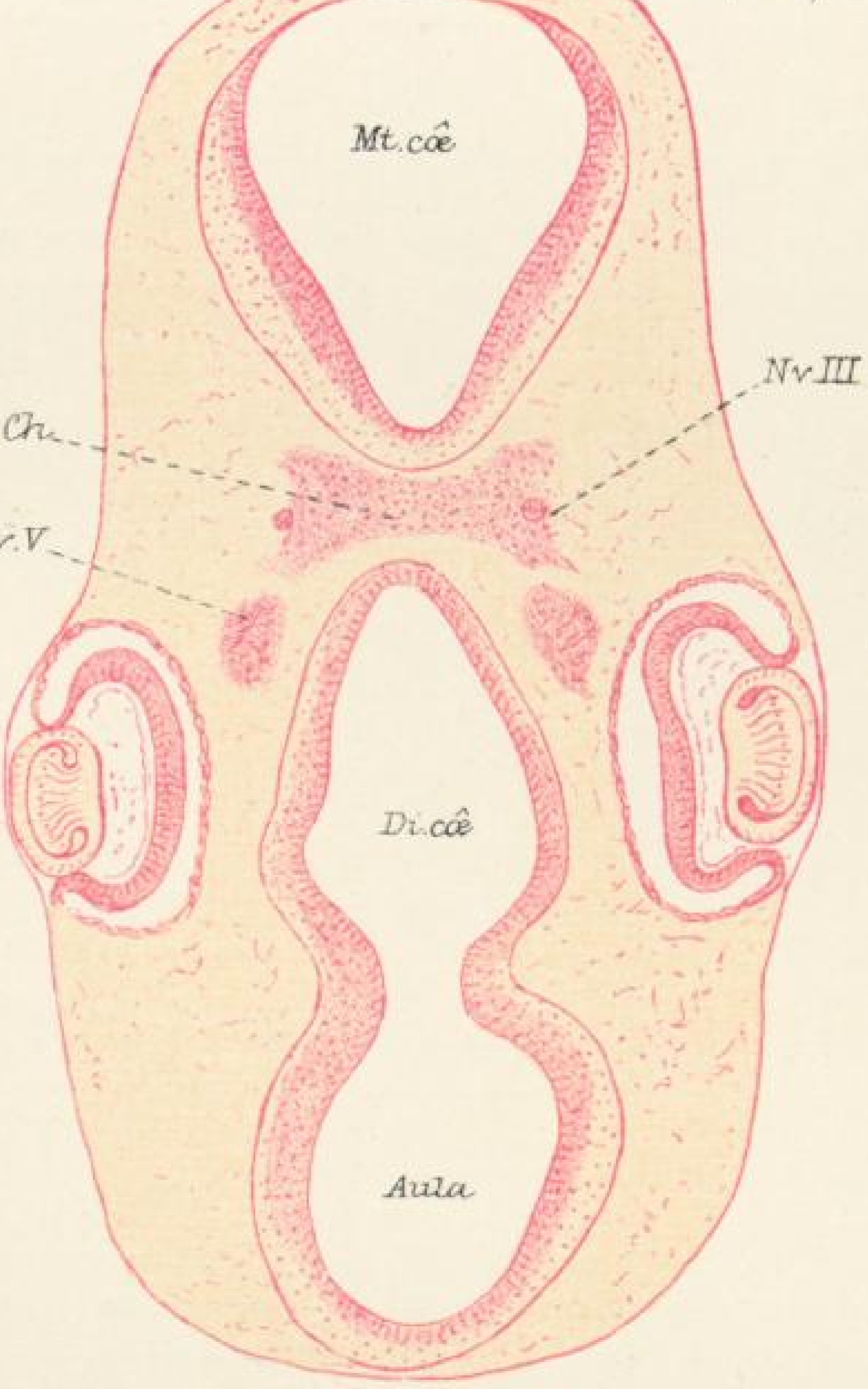

24 (× 22)

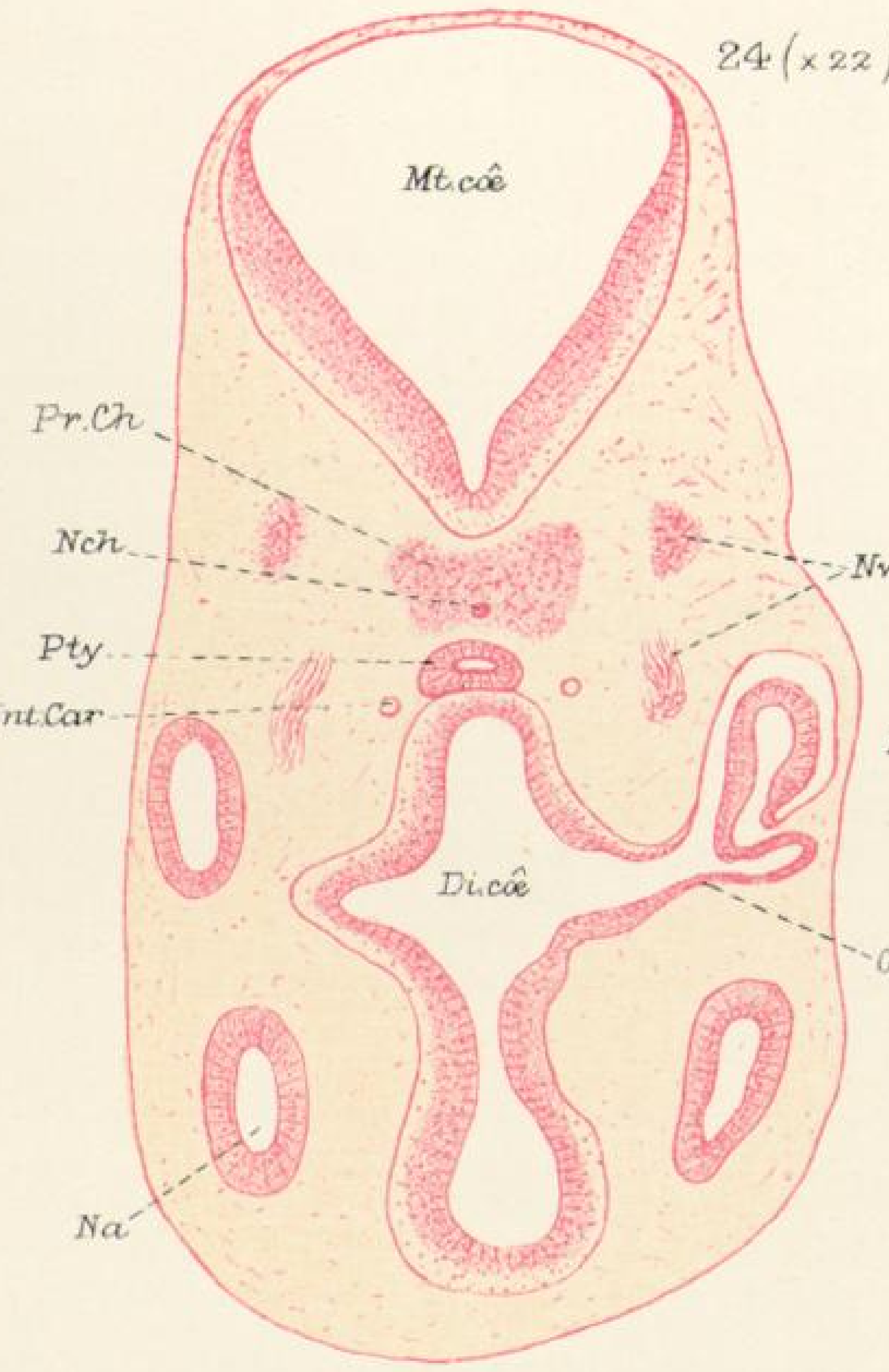

25 (× 22)

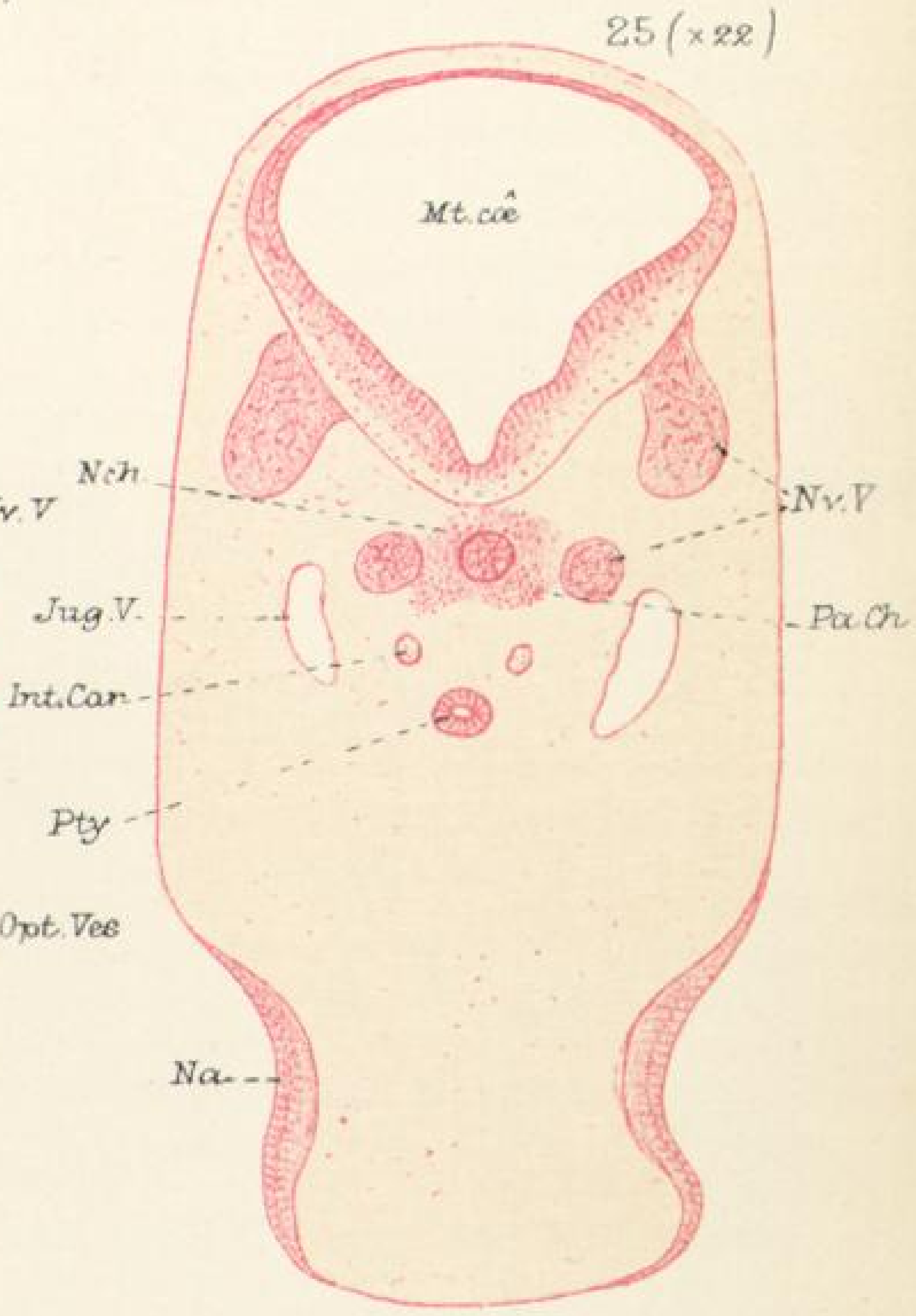

26 (× 22)

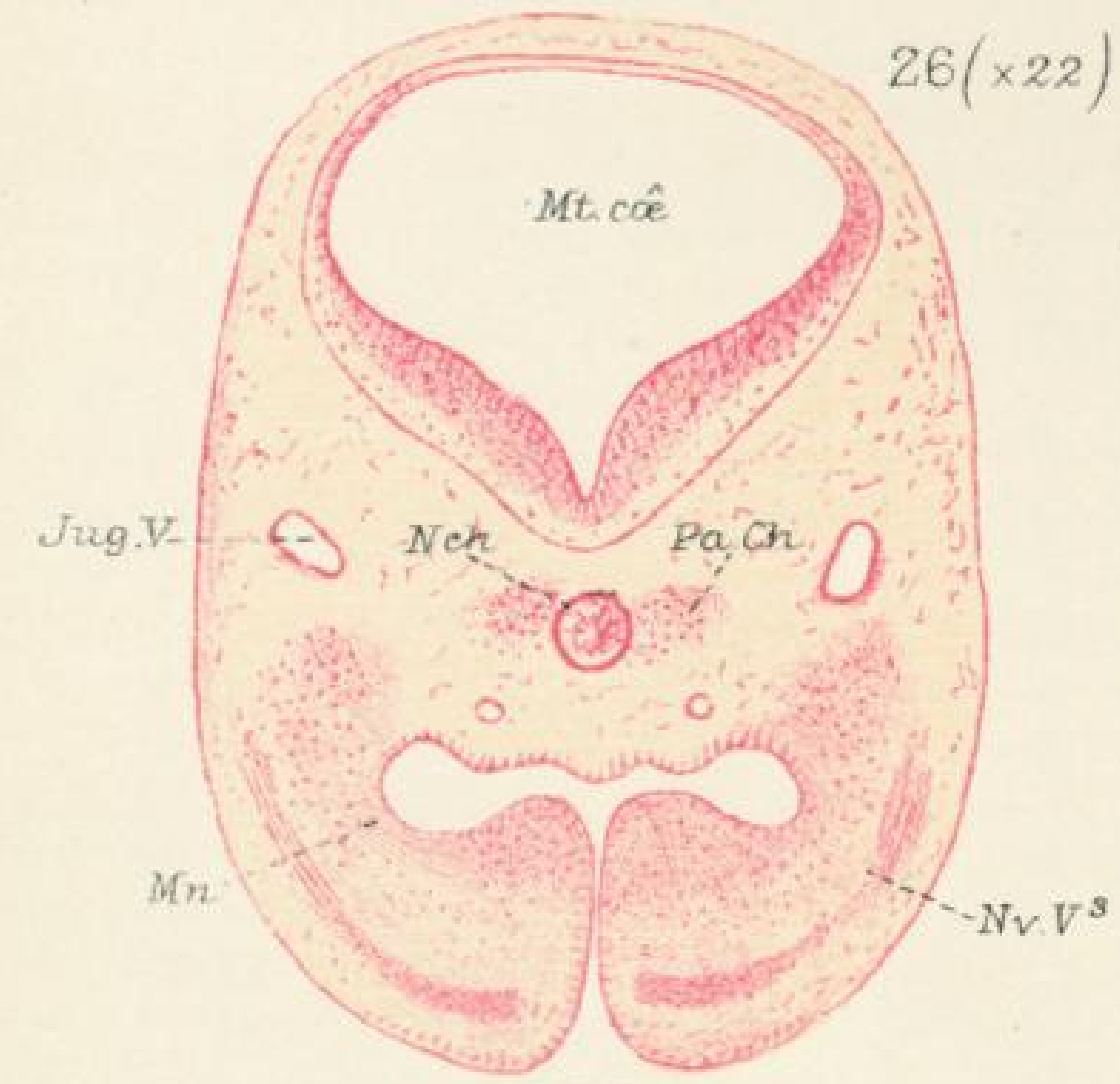

27 (× 22)

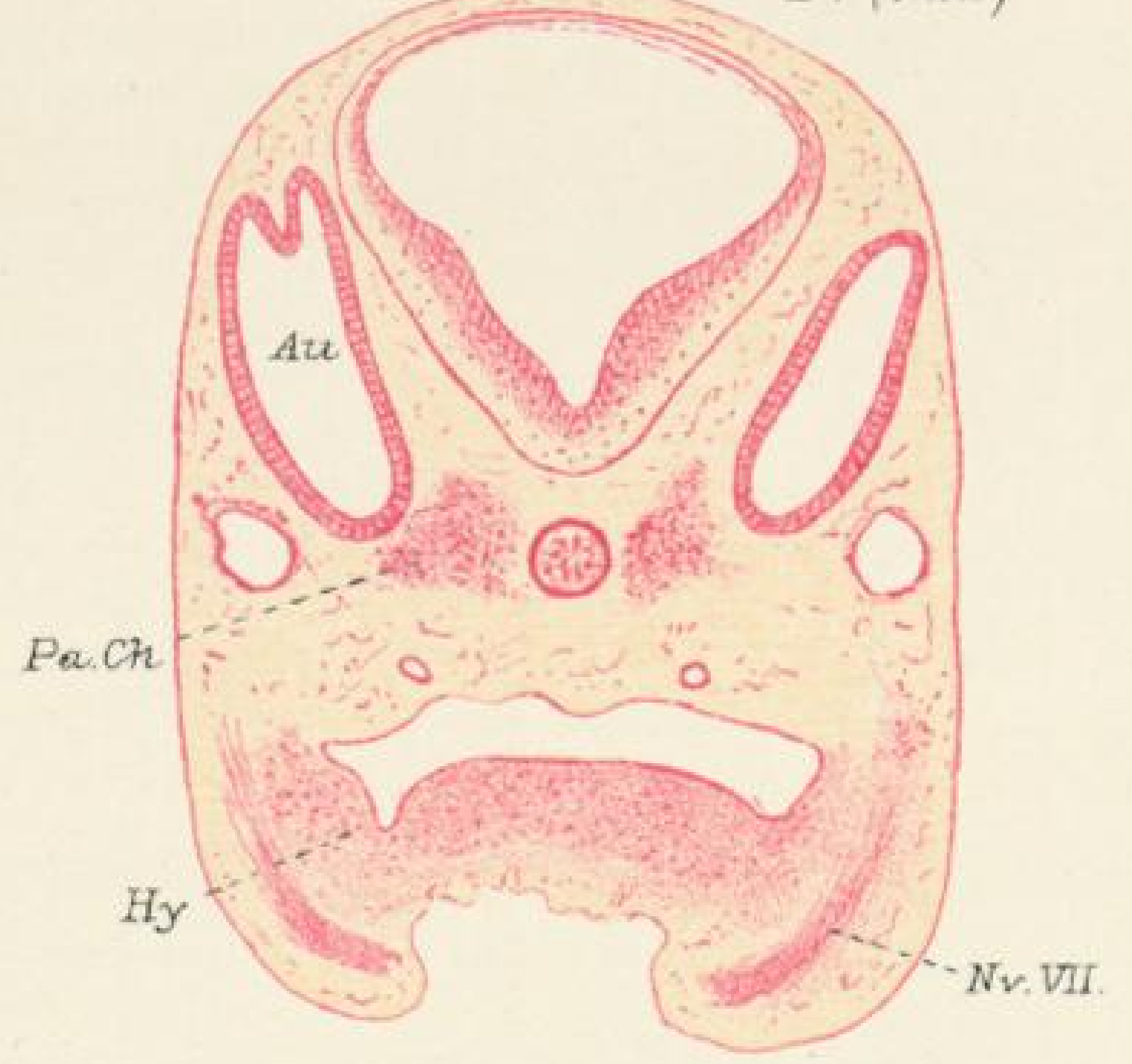

28 (× 22)

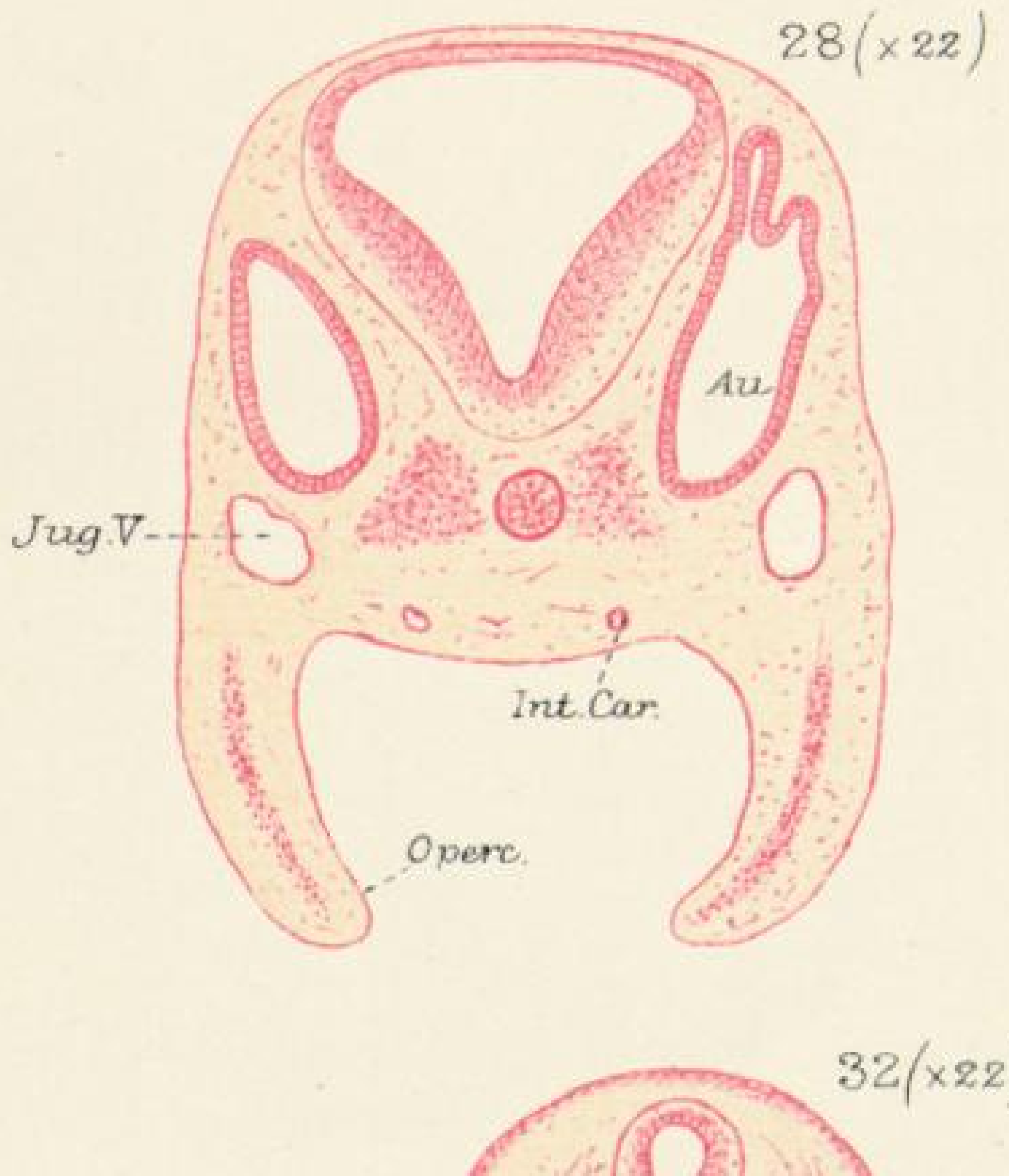

29 (× 22)

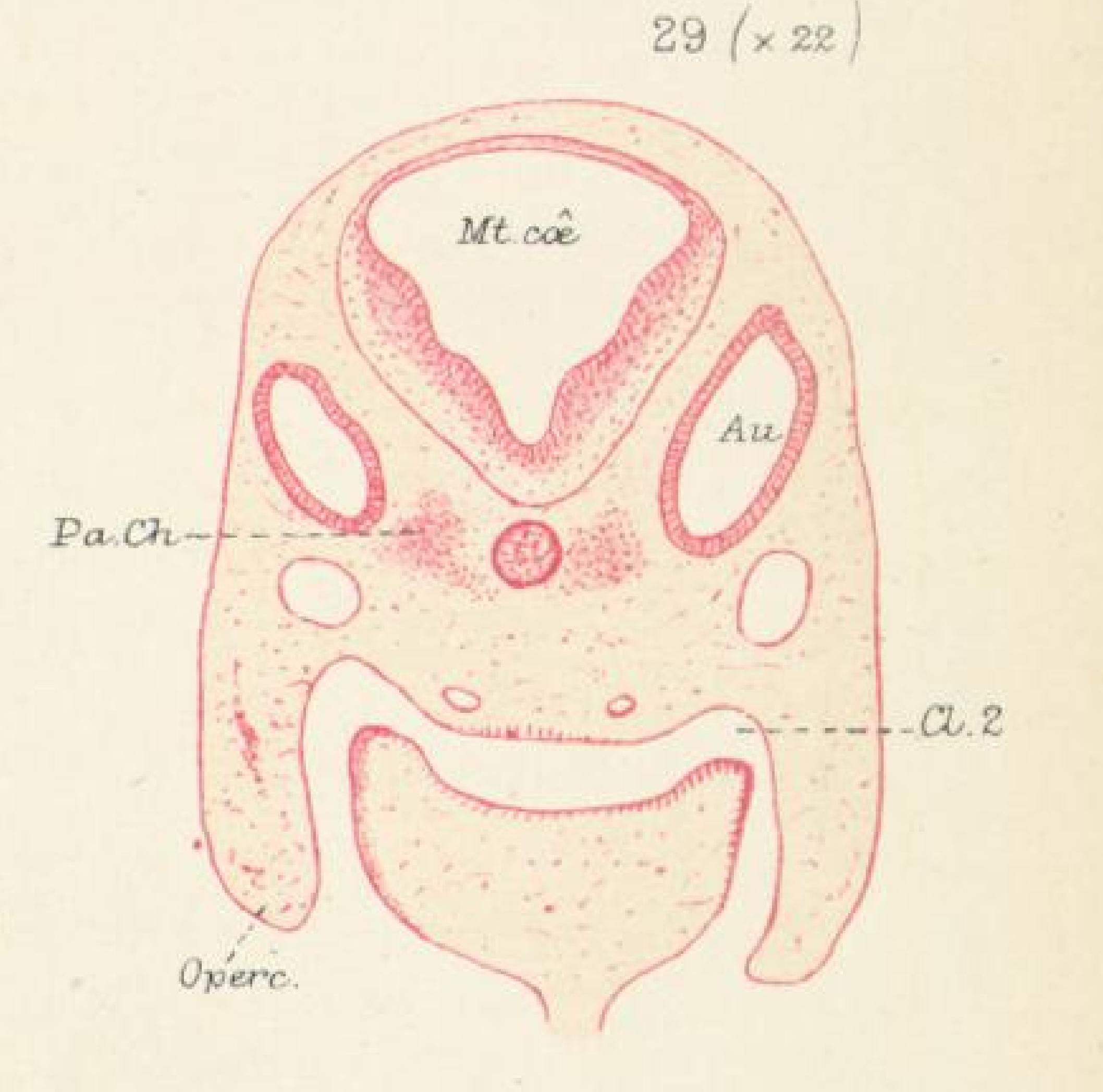

30 (× 22)

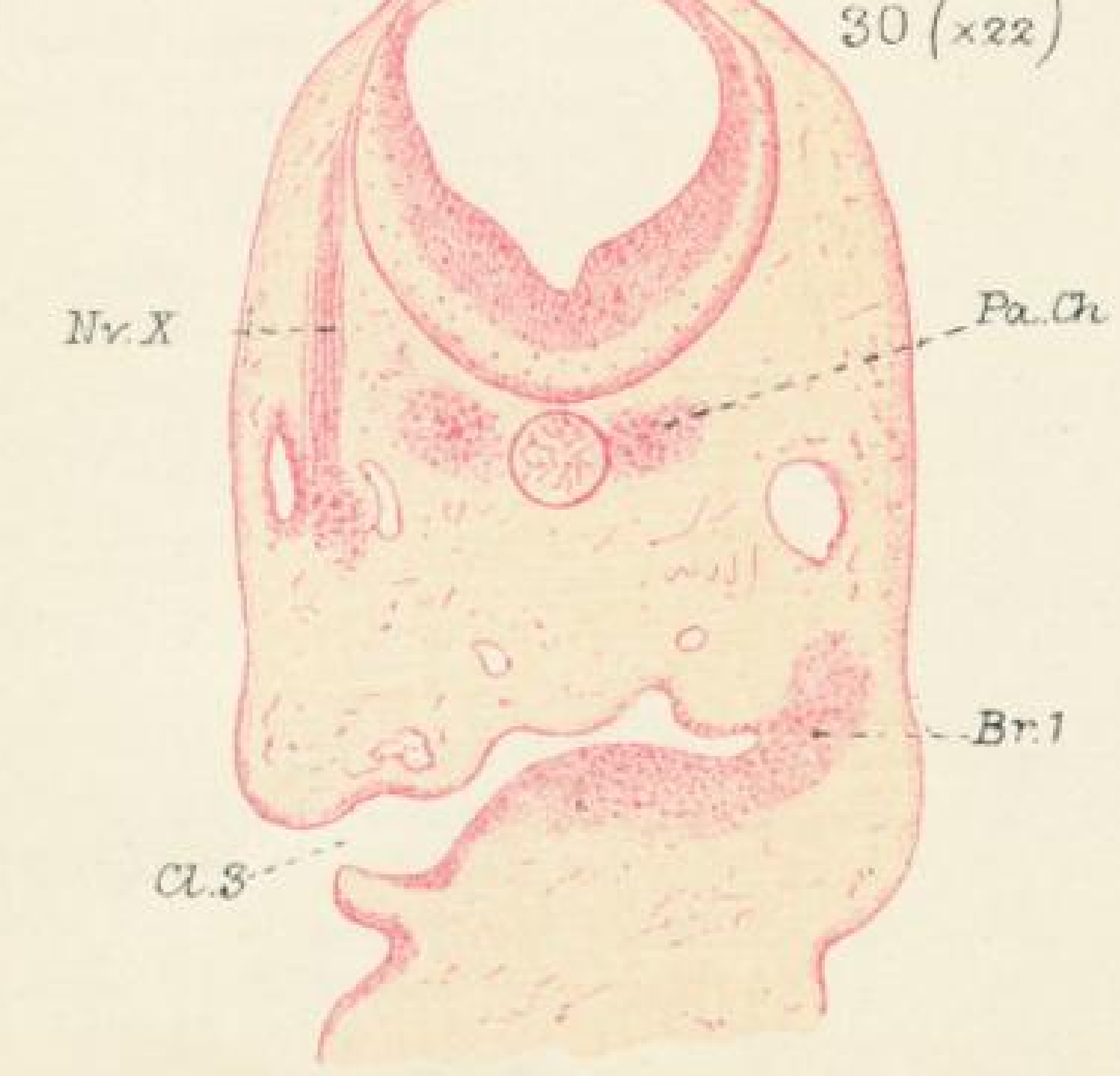

31 (× 22)

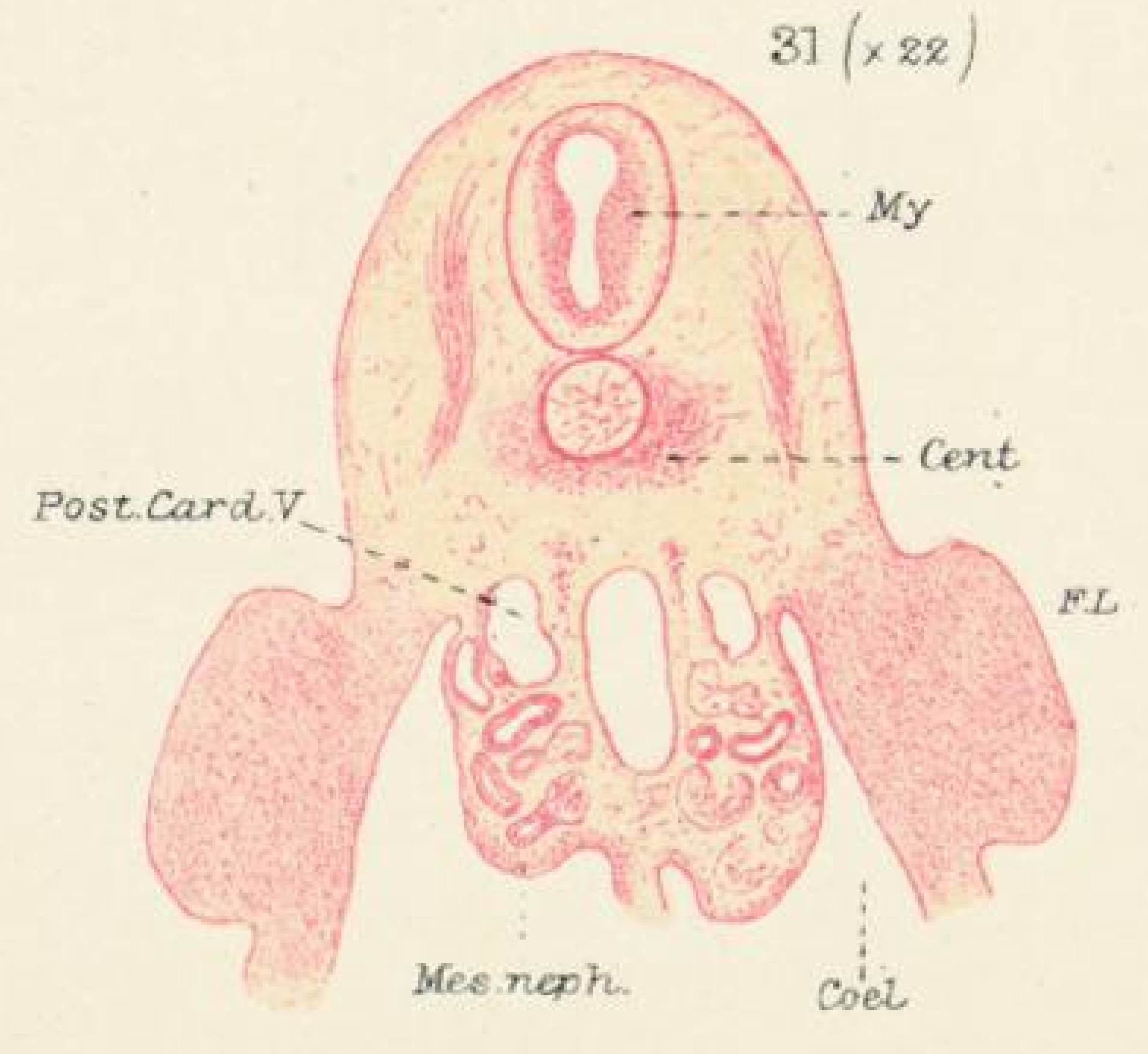

32 (× 22)

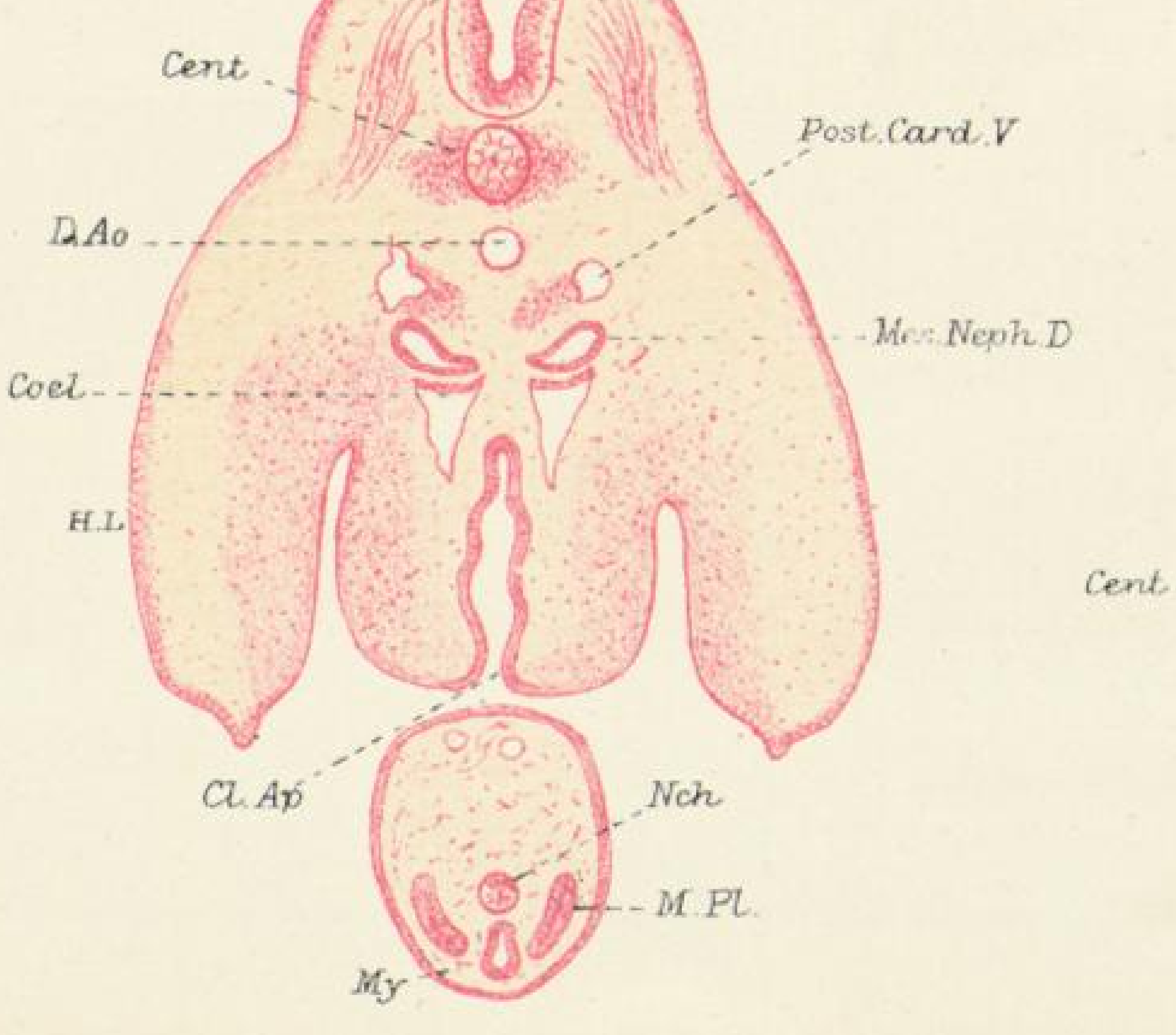

33 (× 22)

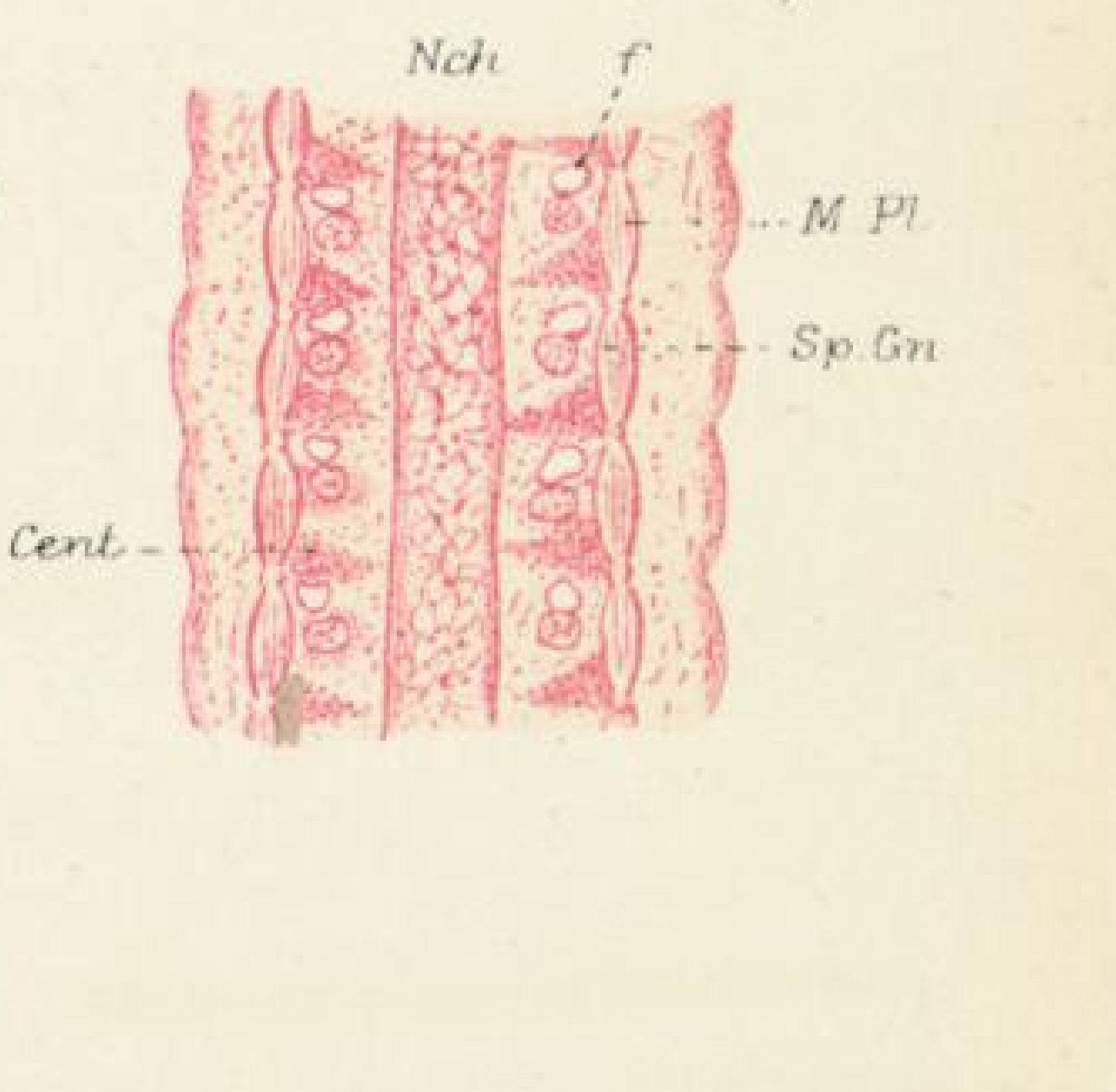

APTERYX. Sections of Stages A and B.

34 (× 22)

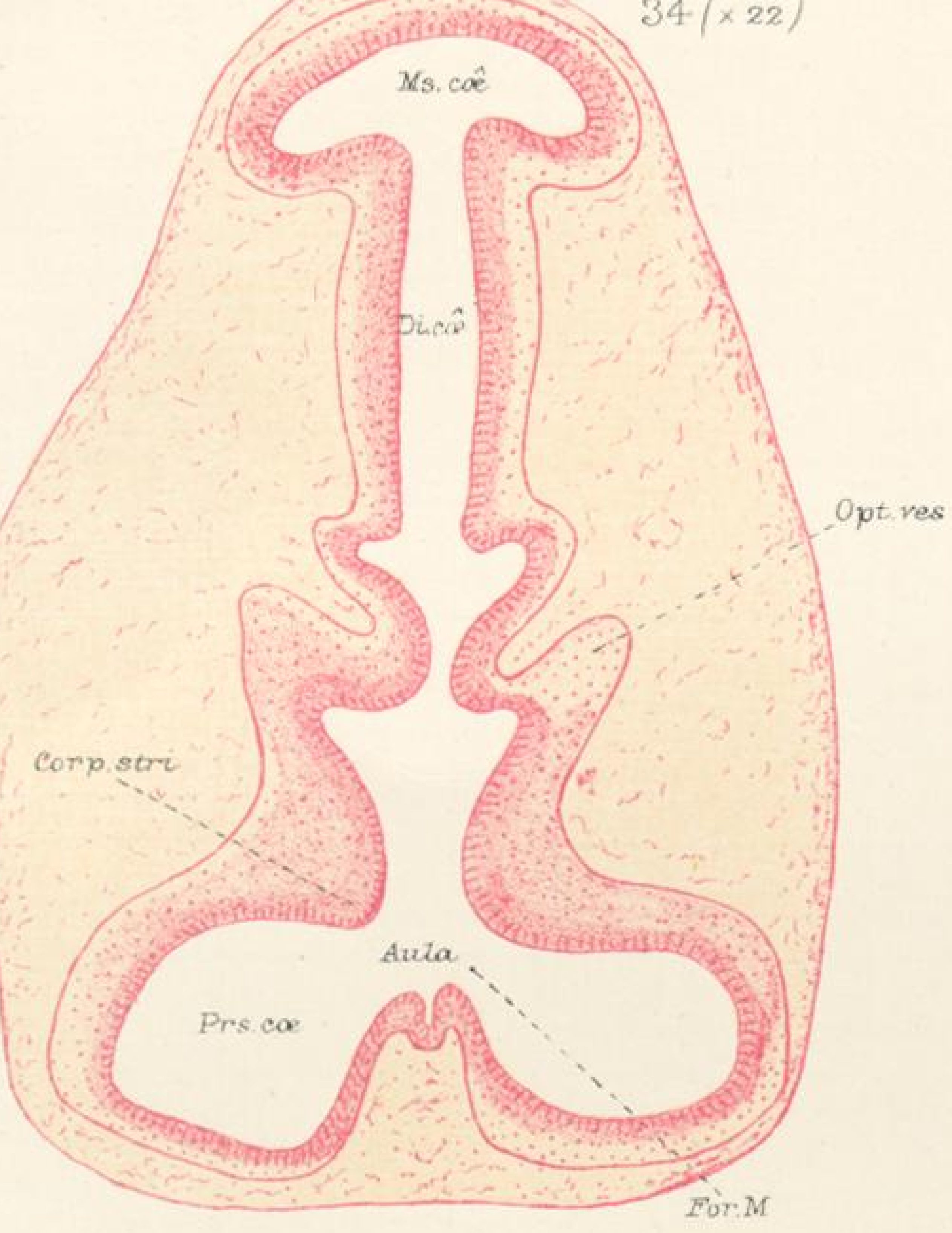

35 (× 22)

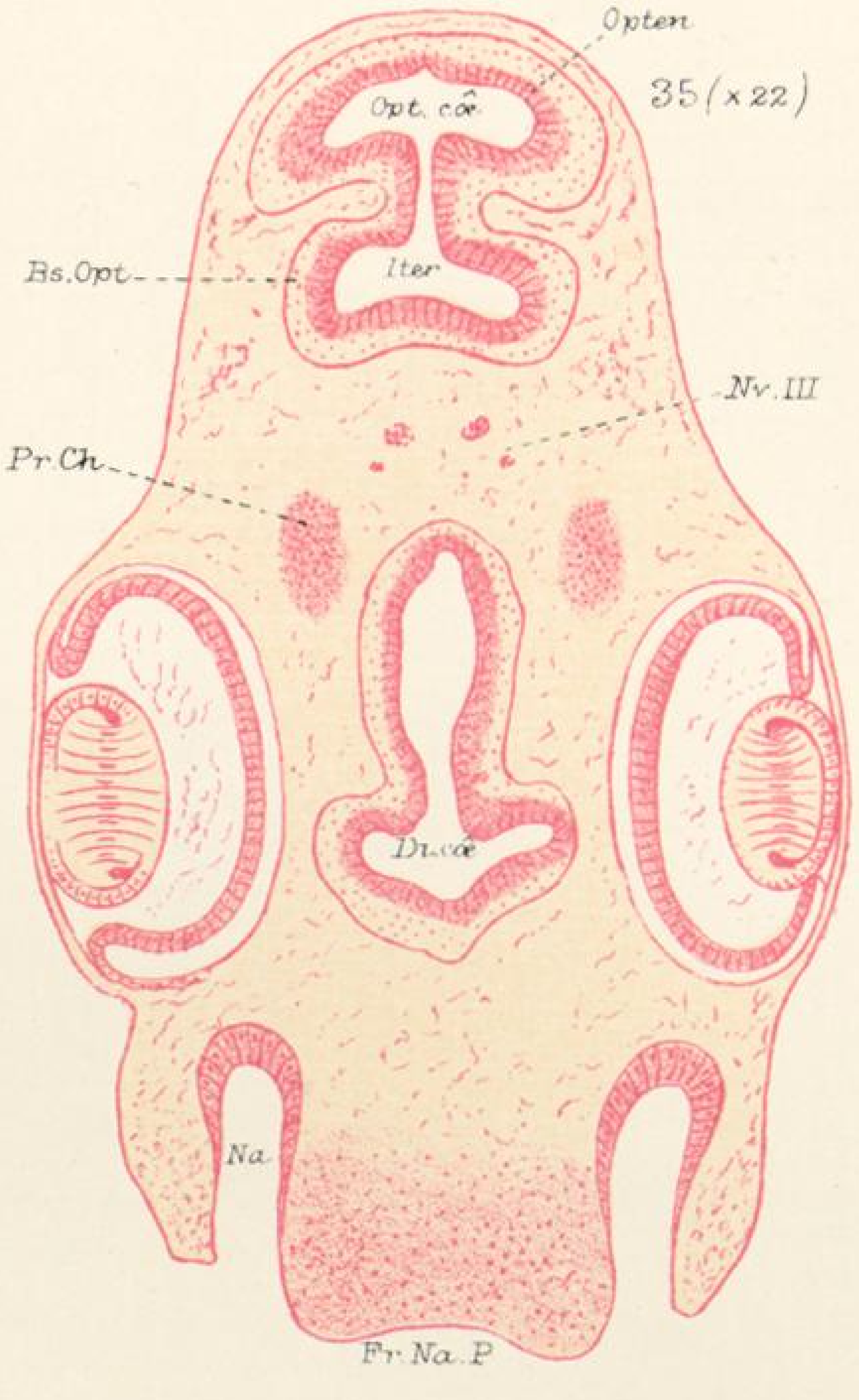

36 (× 22)

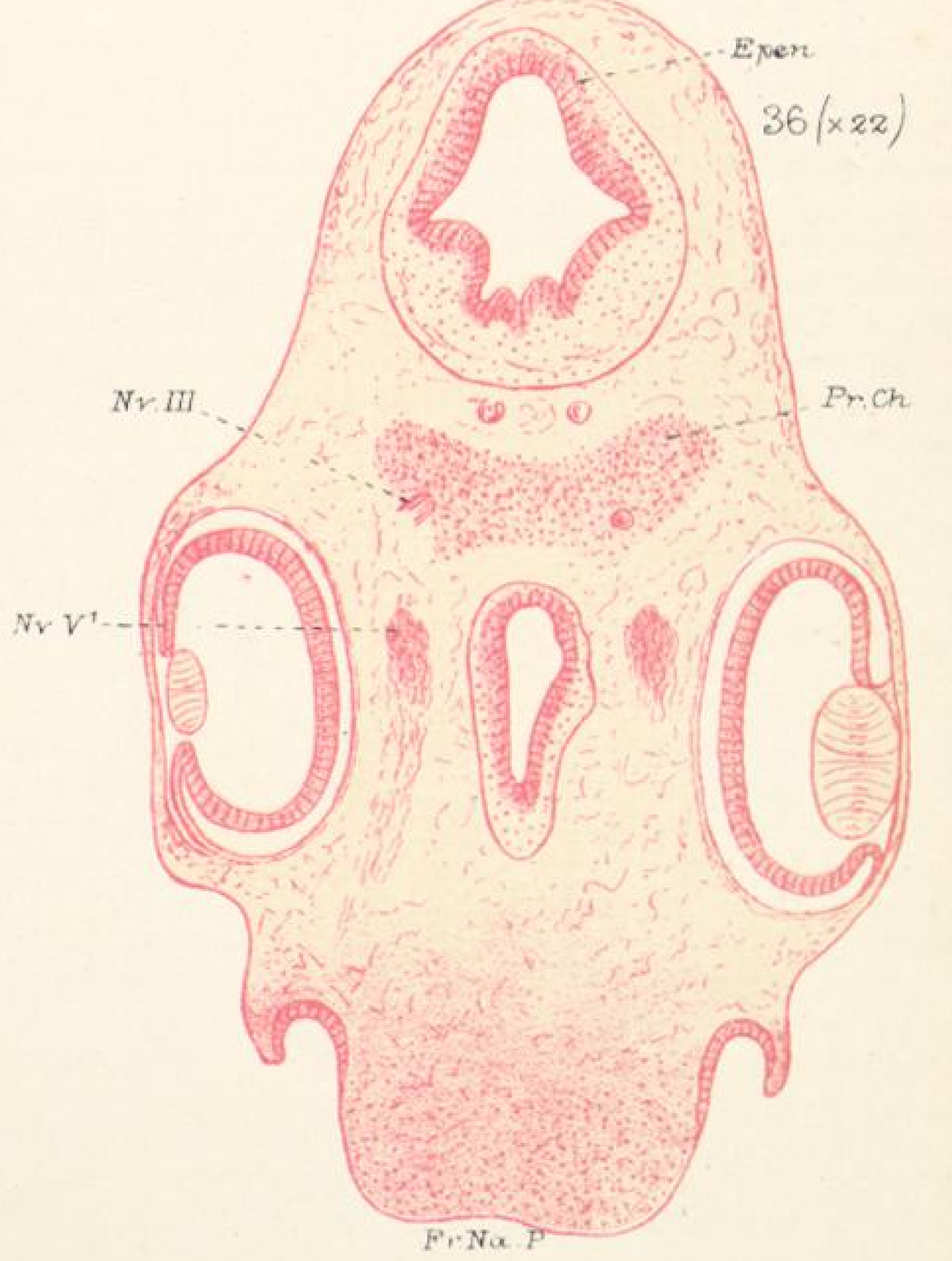

37 (× 22)

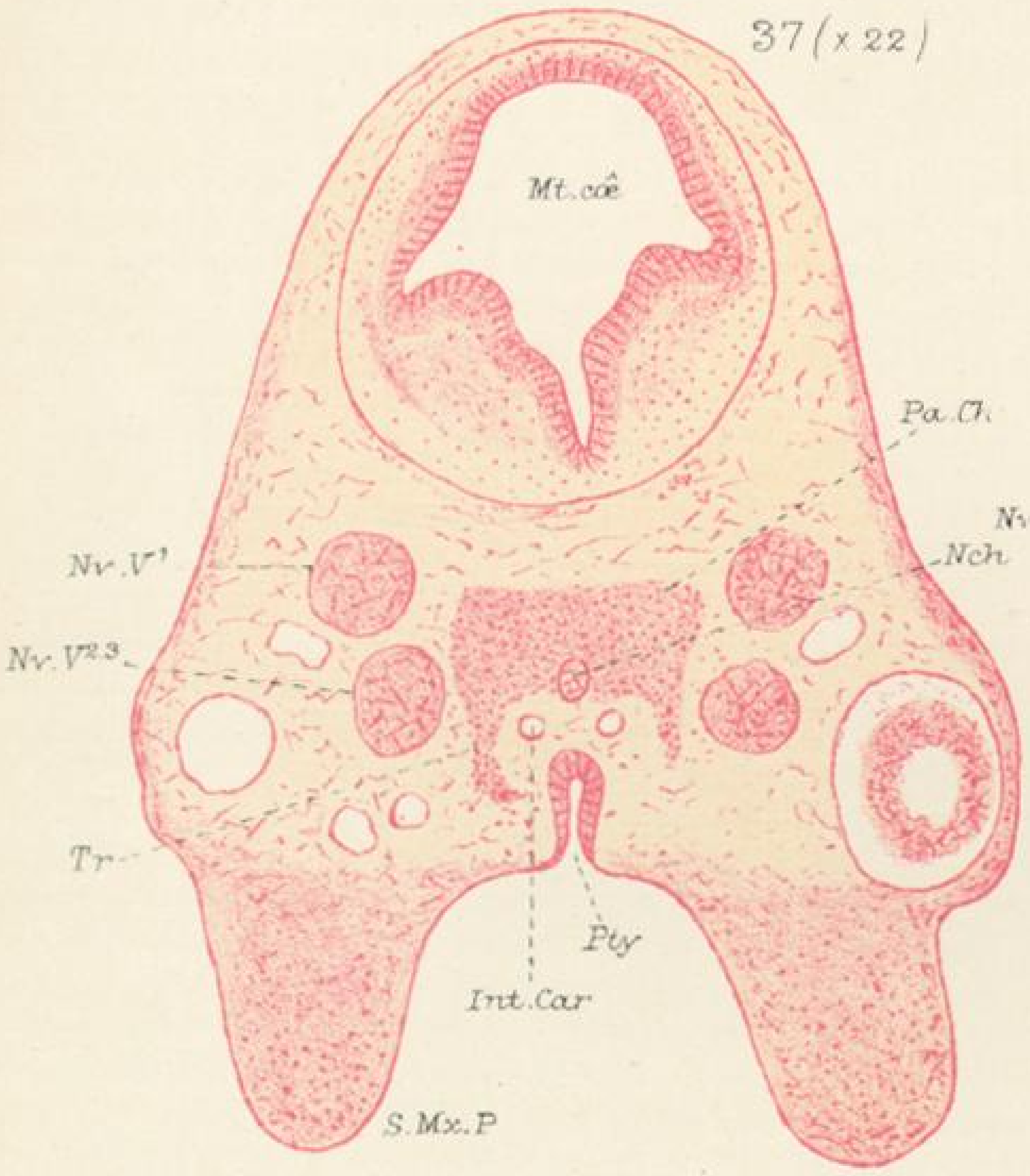

38 (× 22)

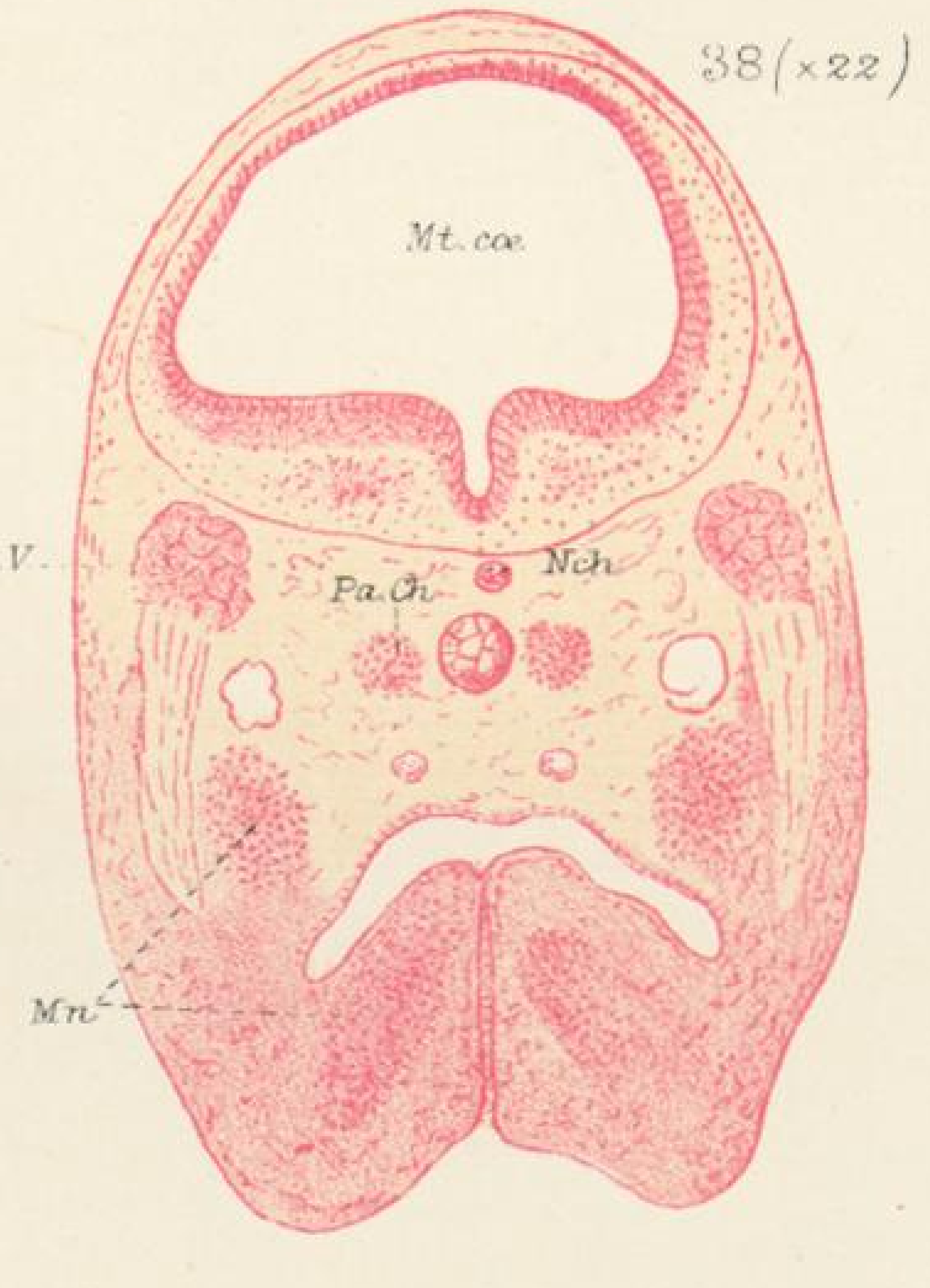

39 (× 22)

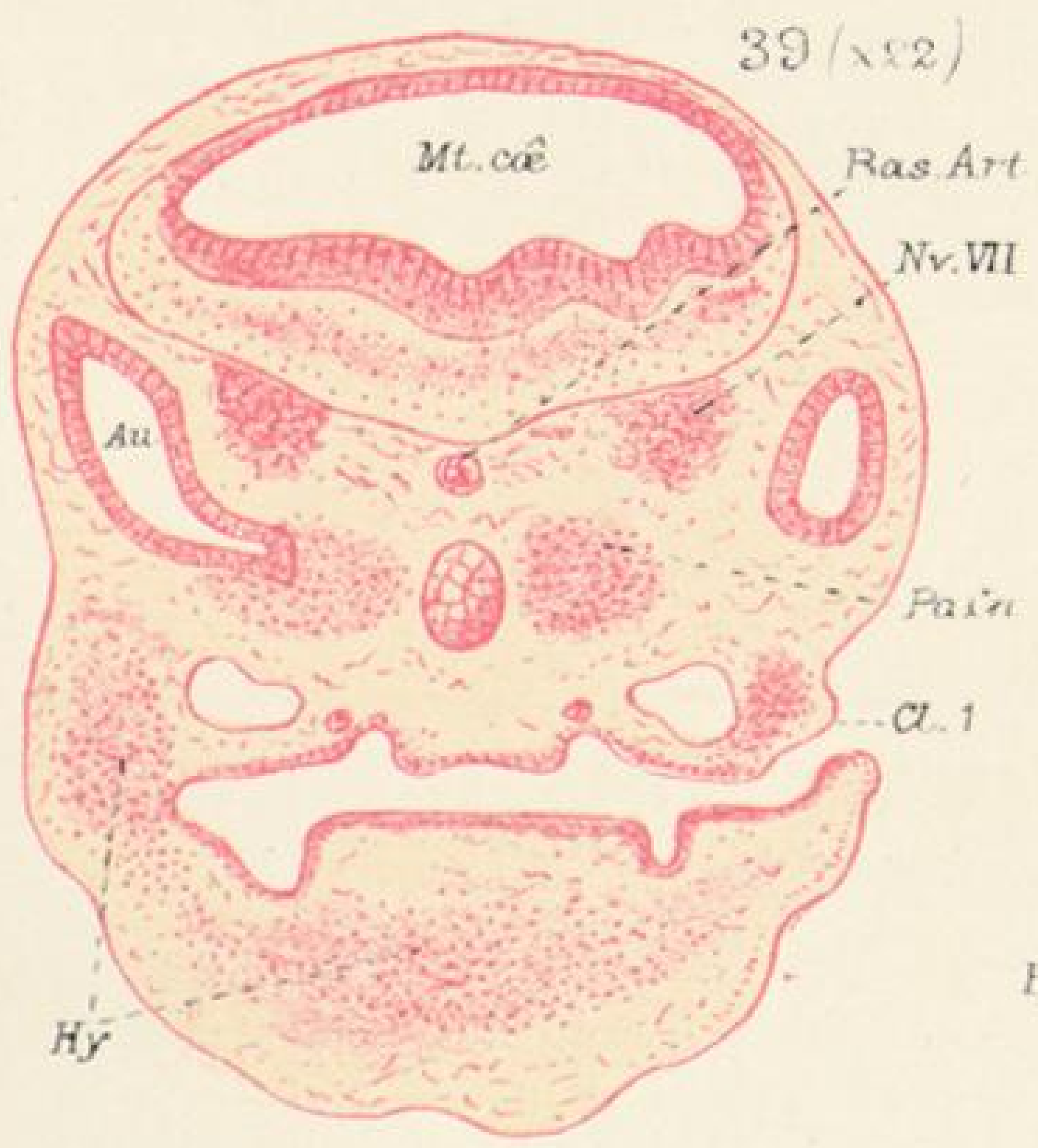

40 (× 22)

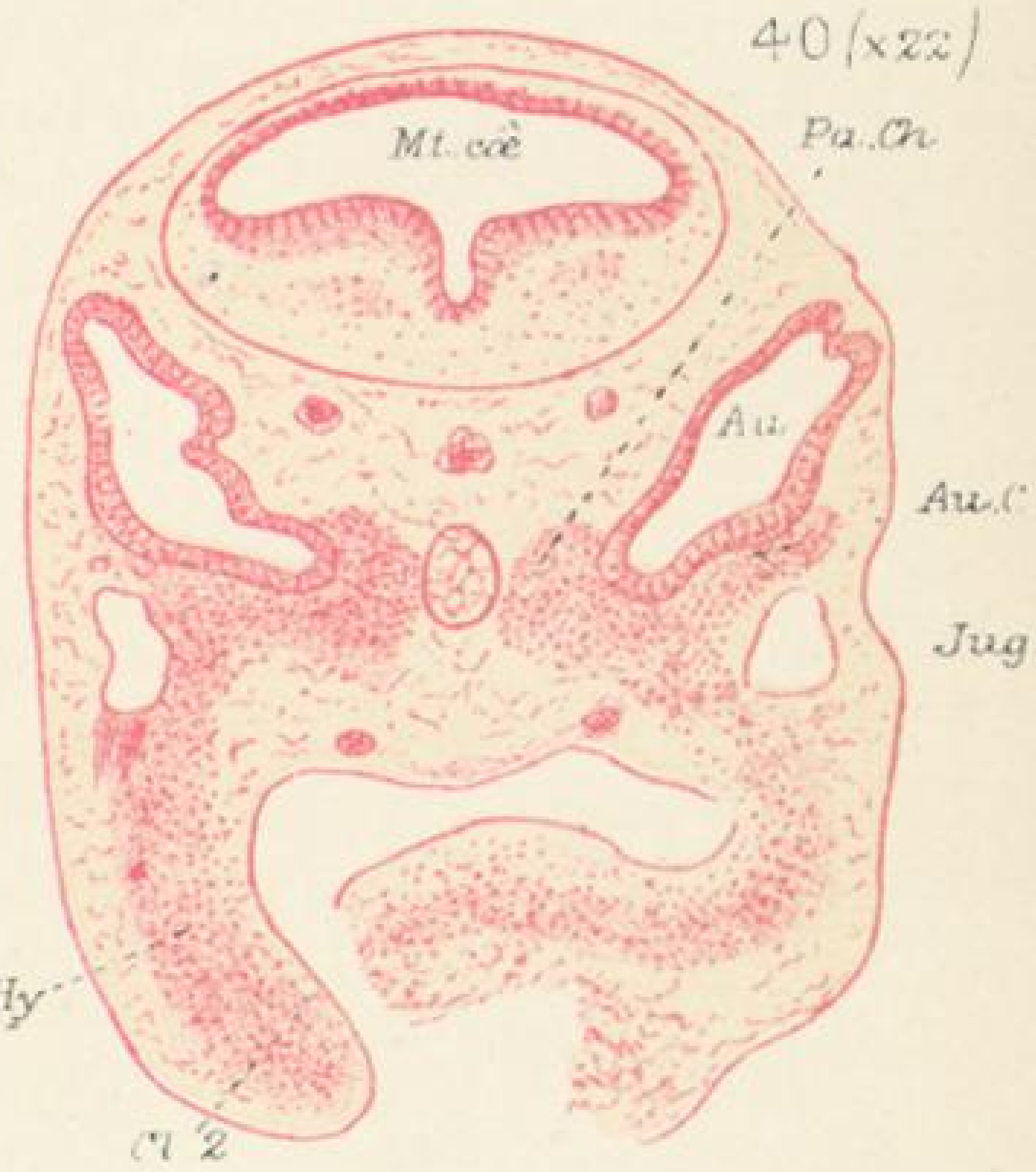

41 (× 22)

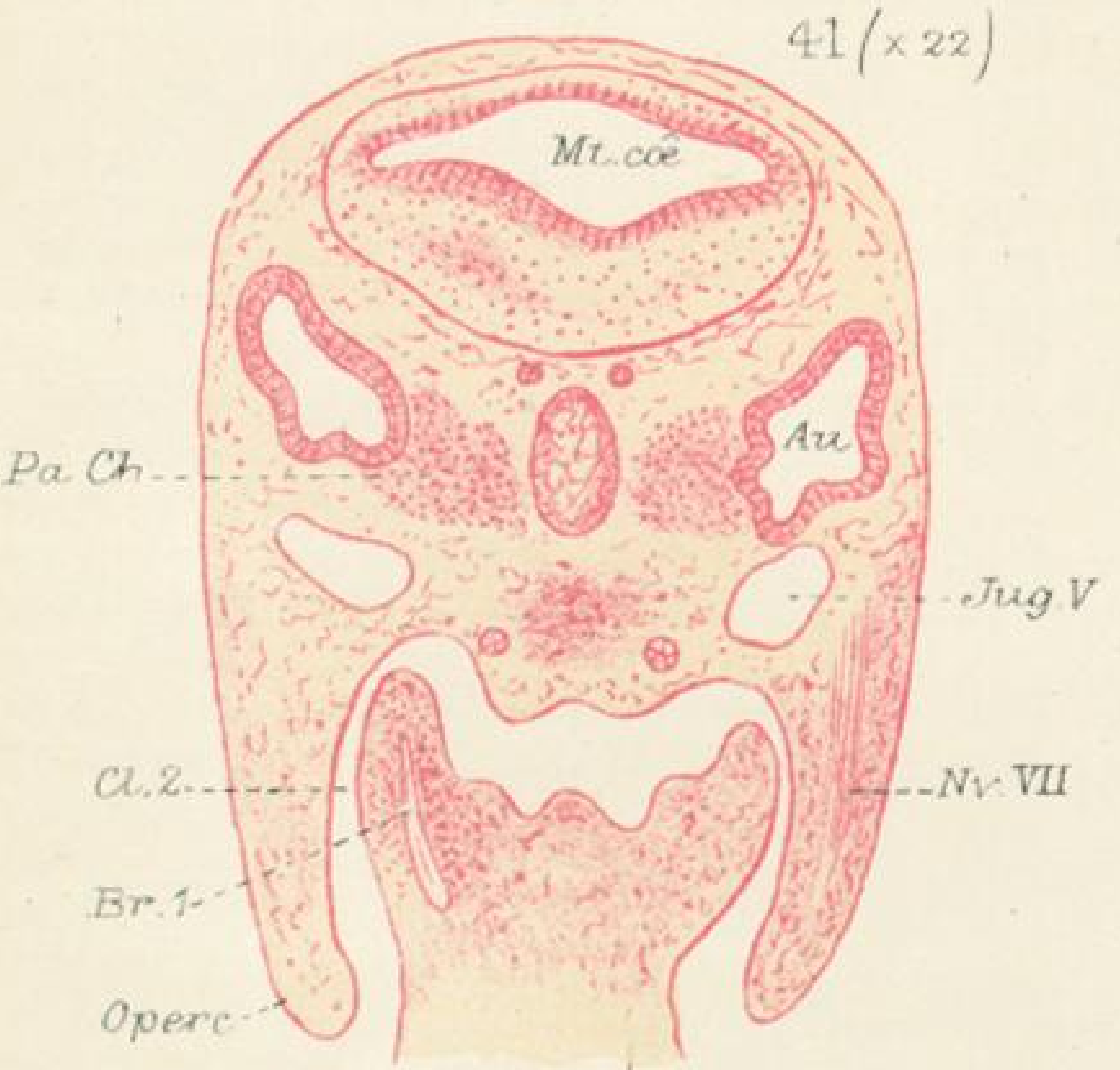

42 (× 22)

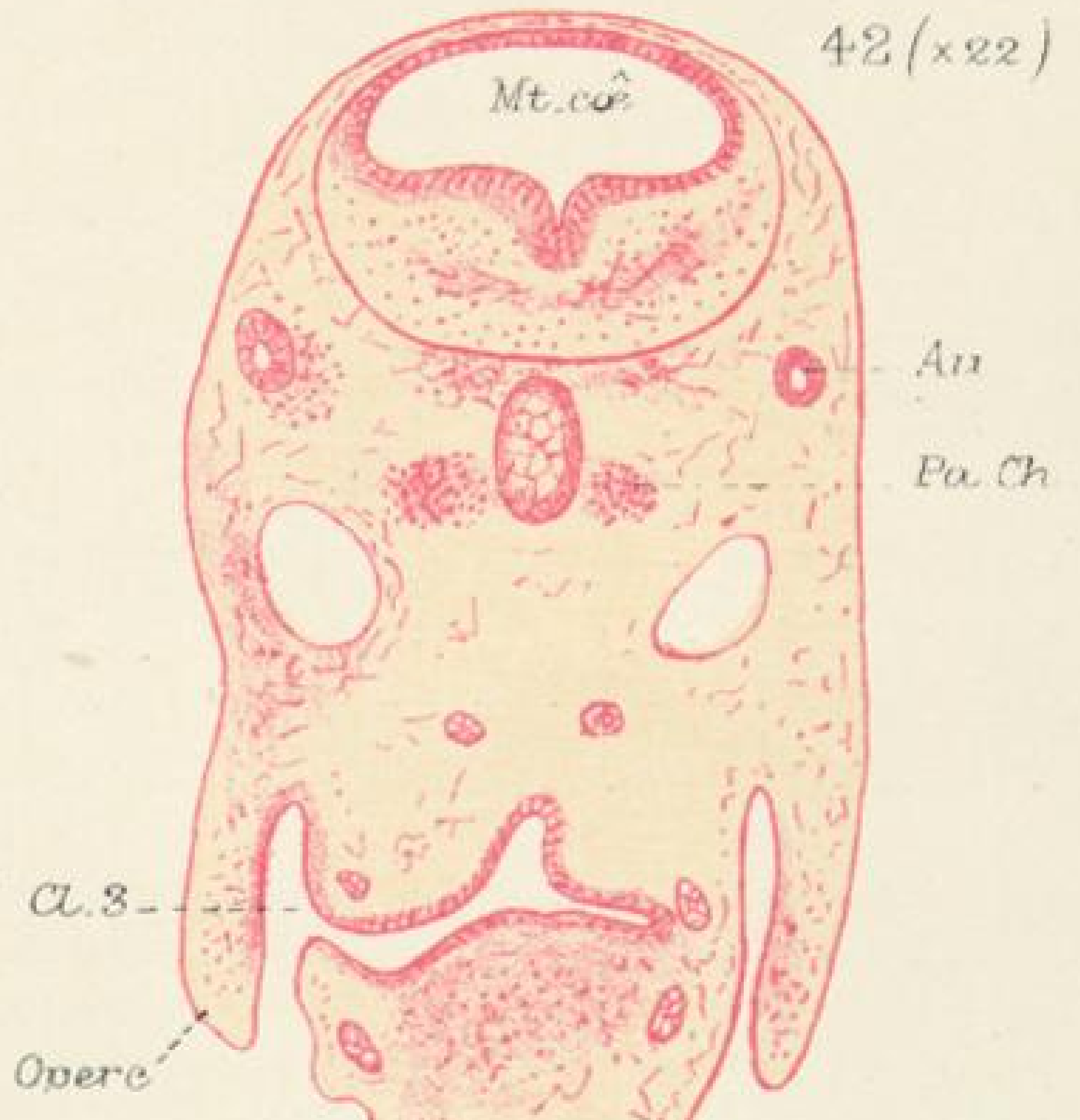

43 (× 22)

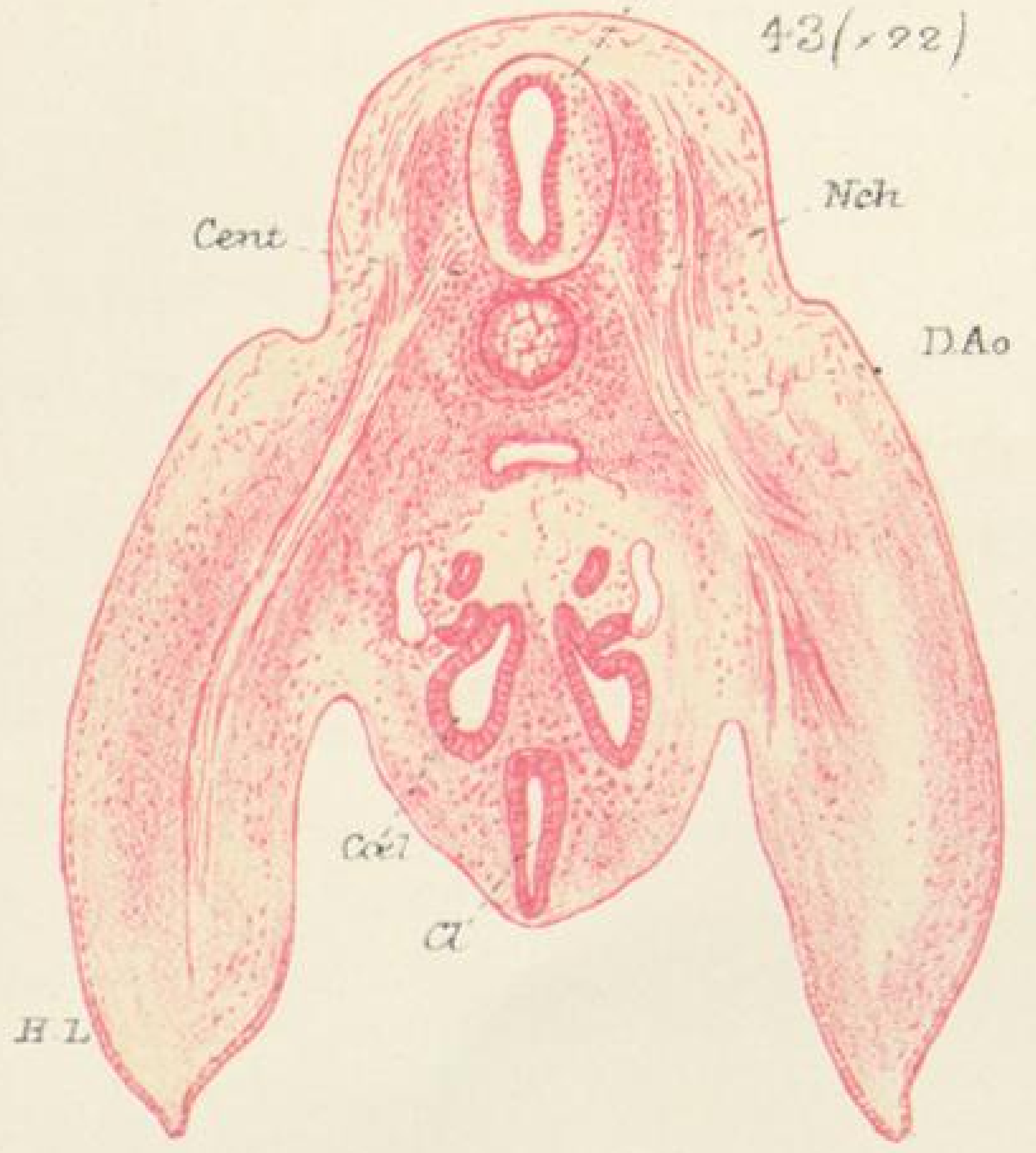

44 (× 22)

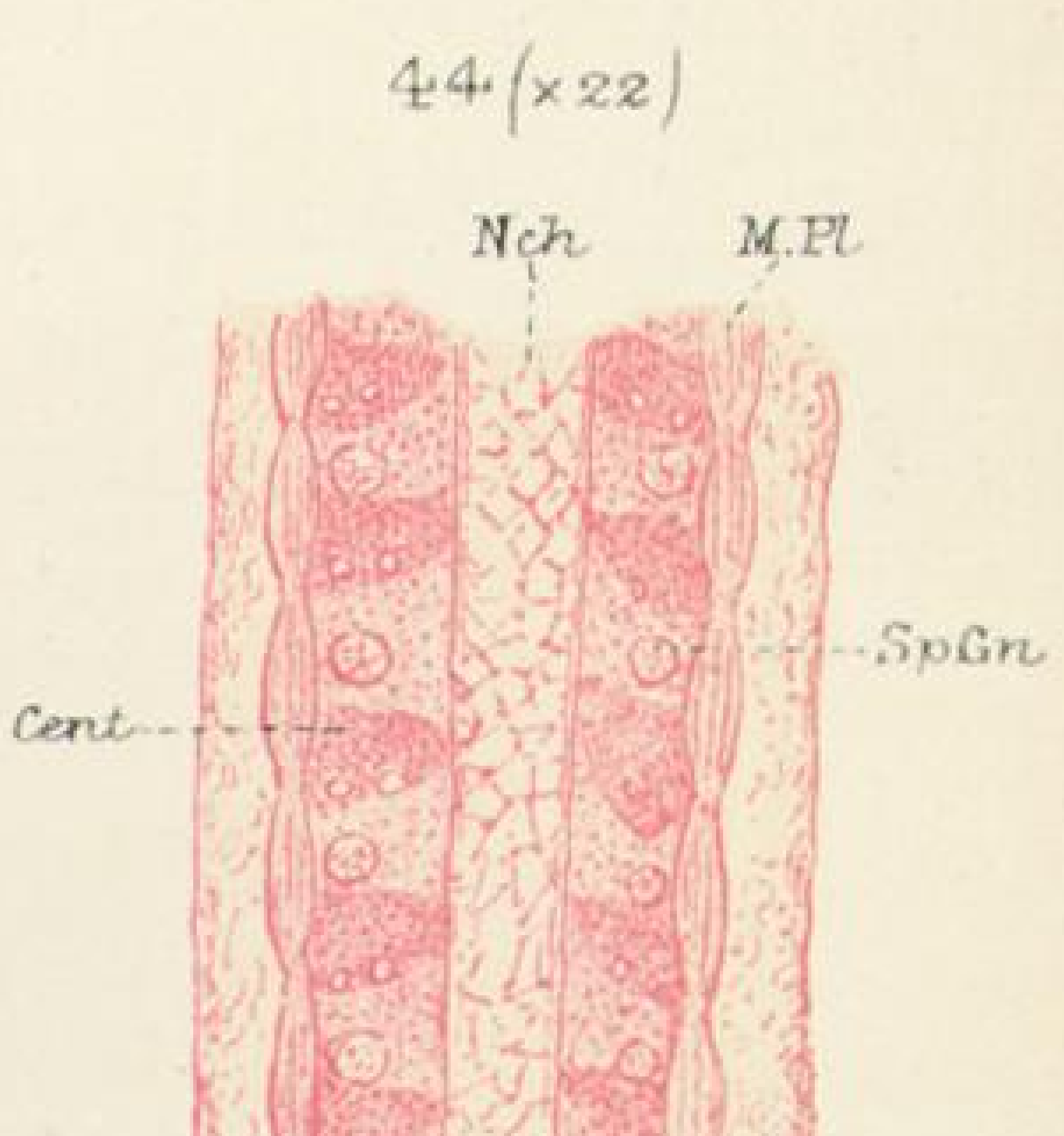

APTERYX Sections of Stage C.

APTERYX. Skull of ripe embryo (Stage K.)

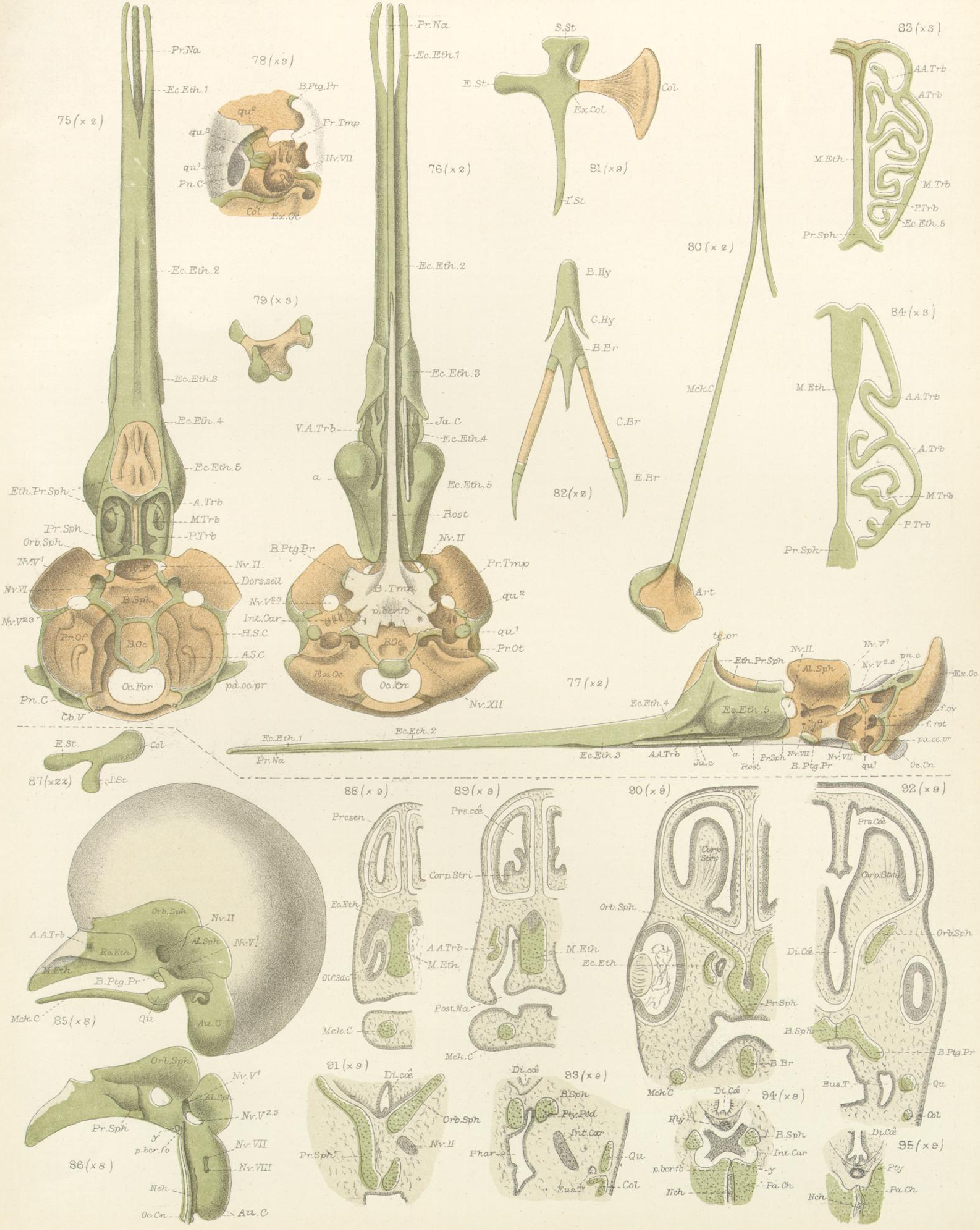

APTERYX. Skull: Stages K and D.

96 (x 6)

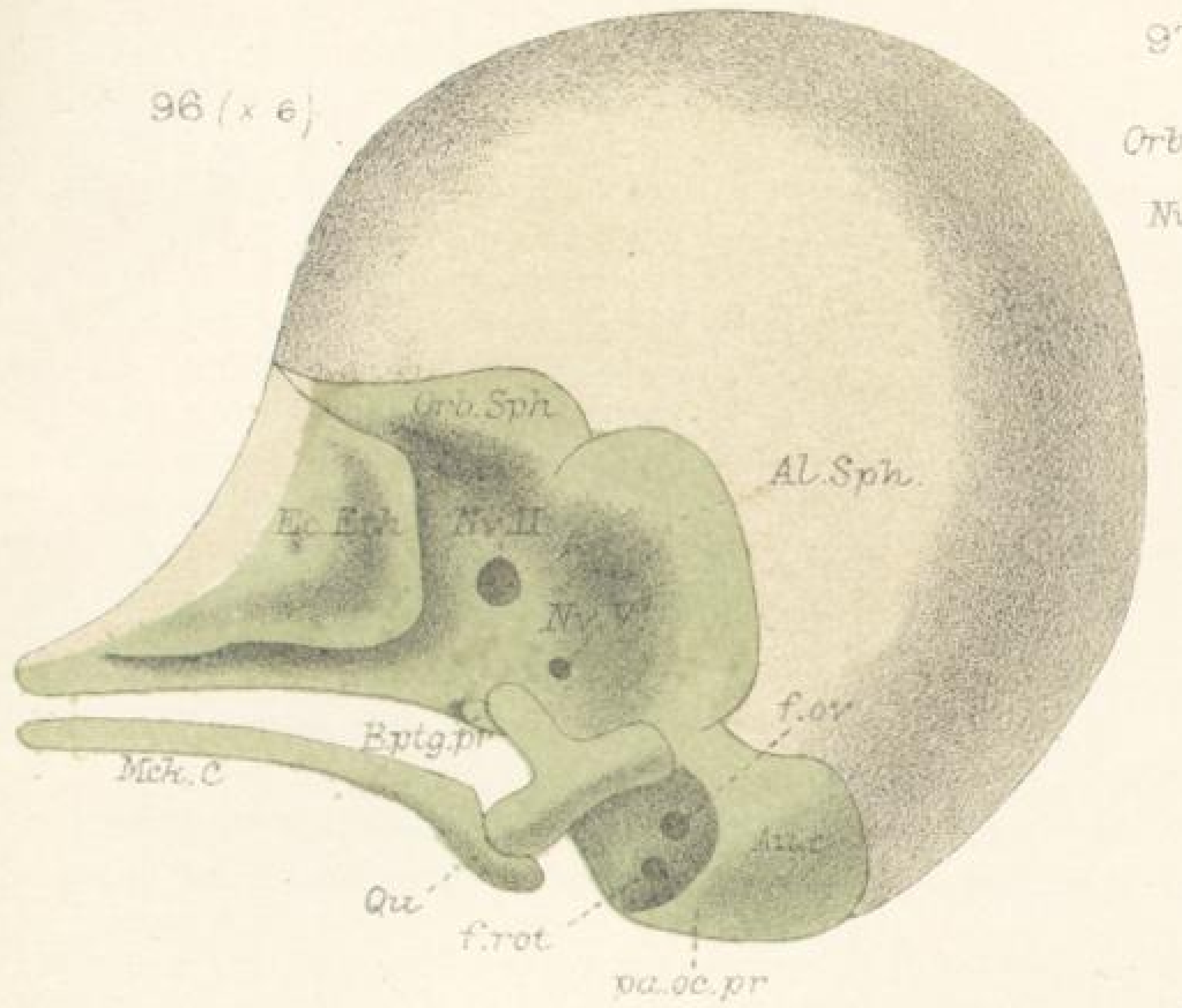

97 (x 6)

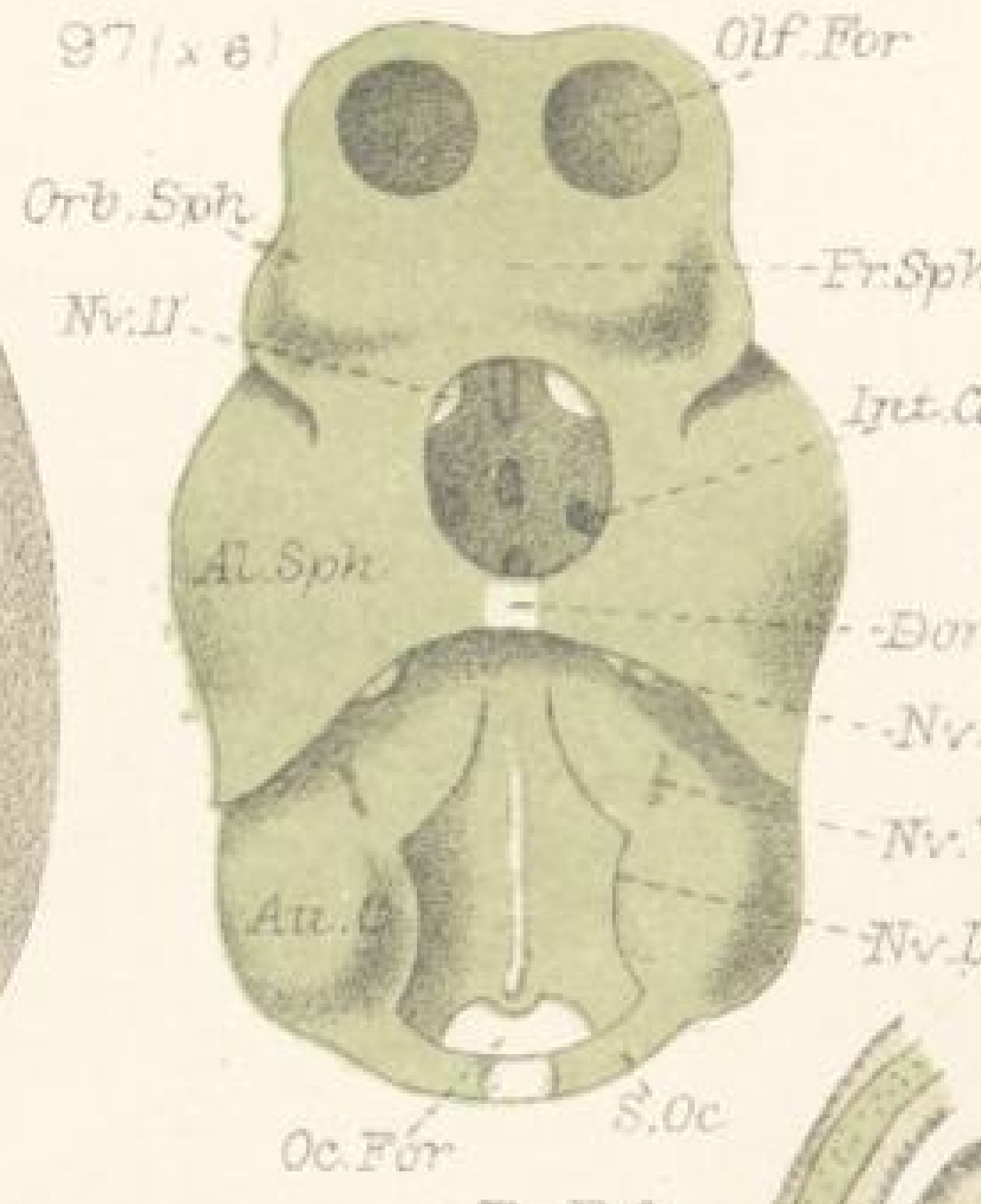

98 (x 6)

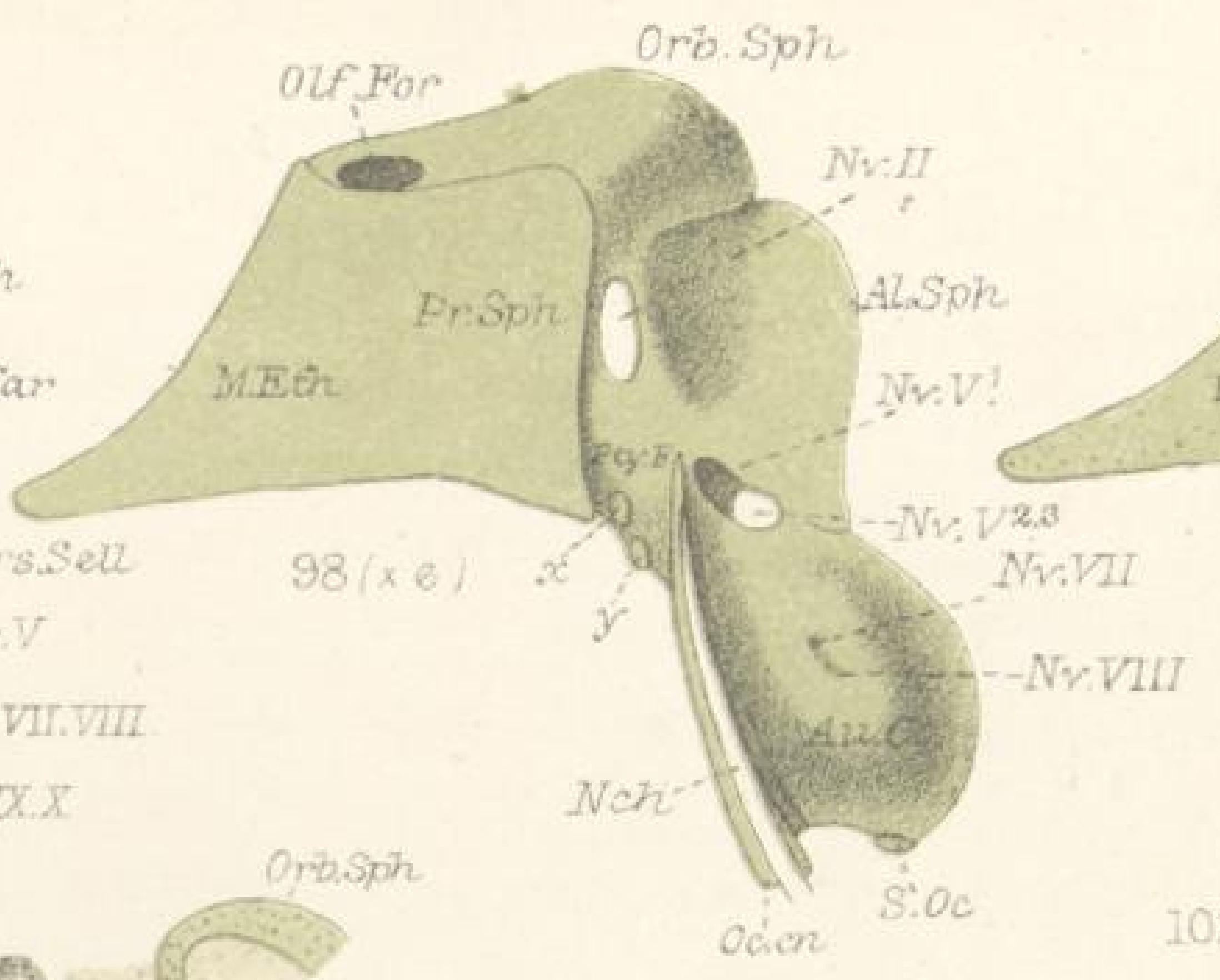

101 (x 9)

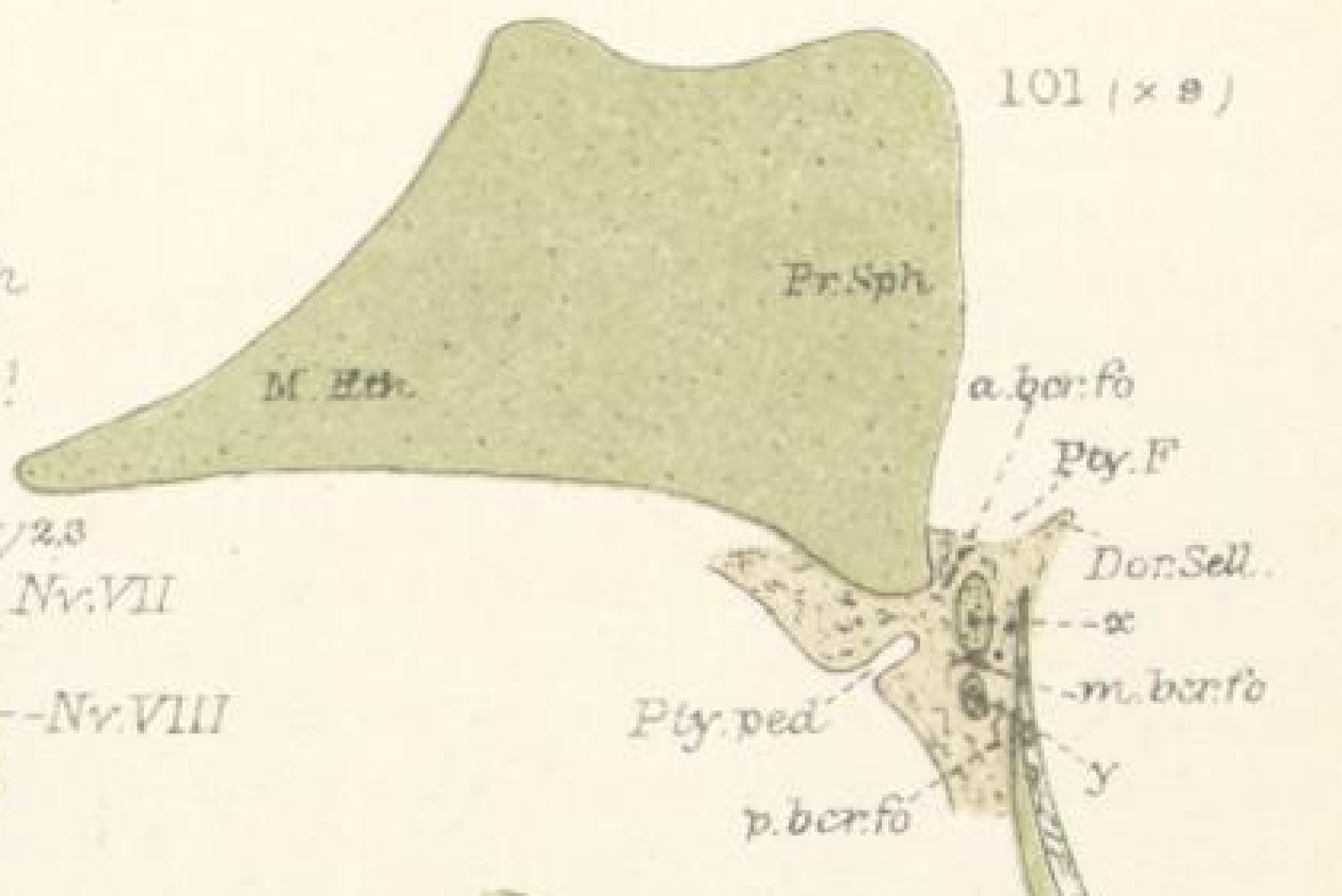

102 (x 9)

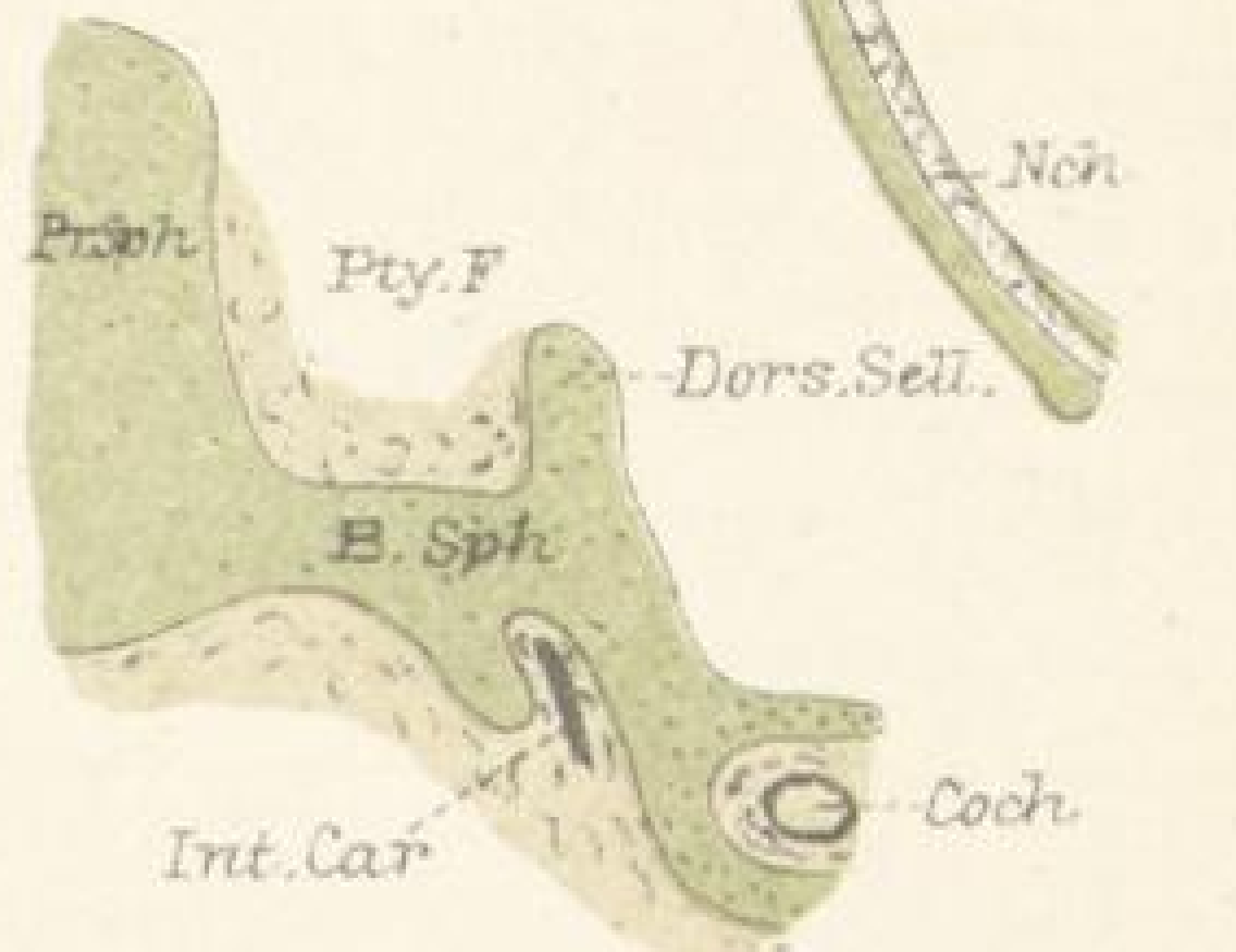

100 (x 9)

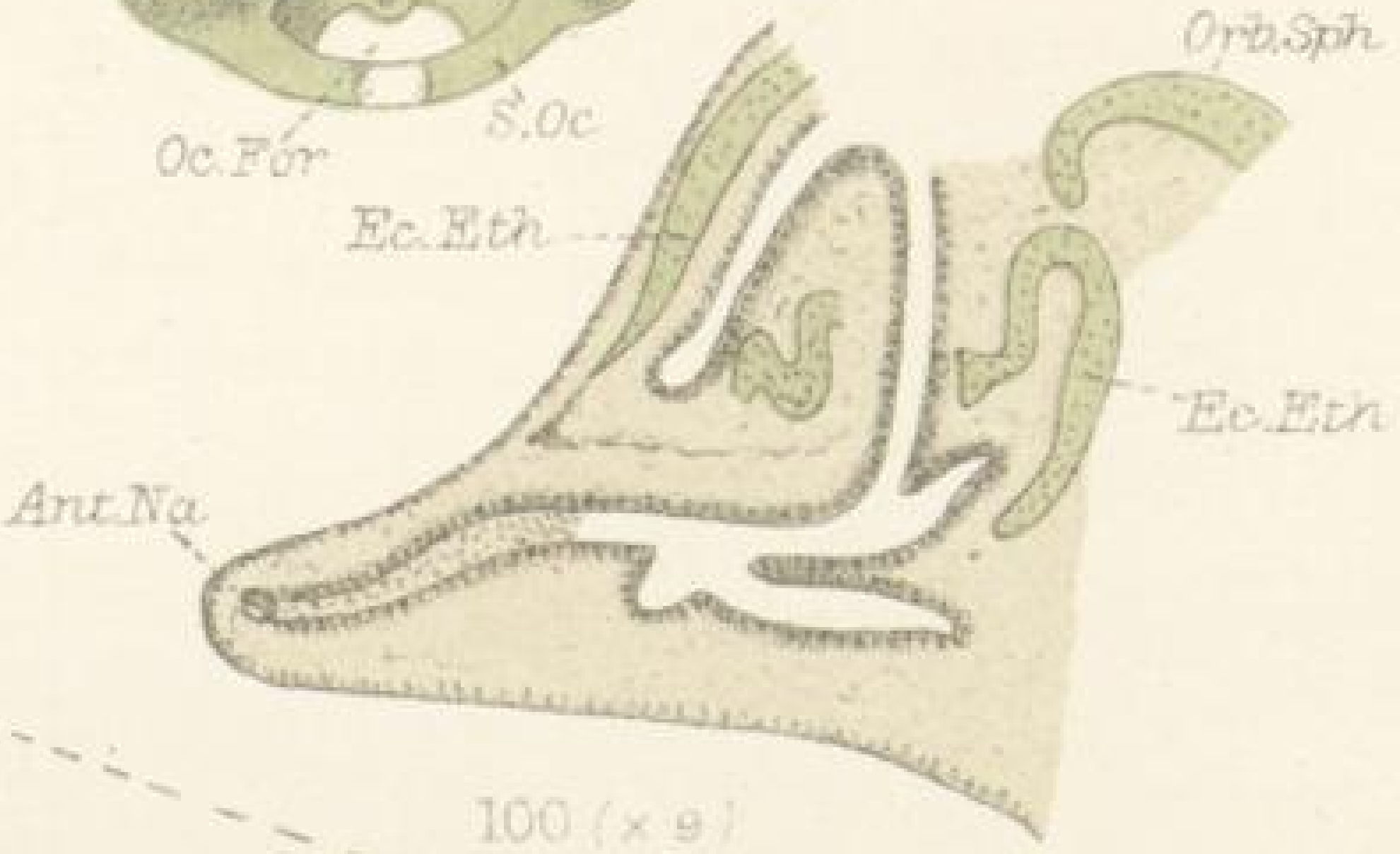

103

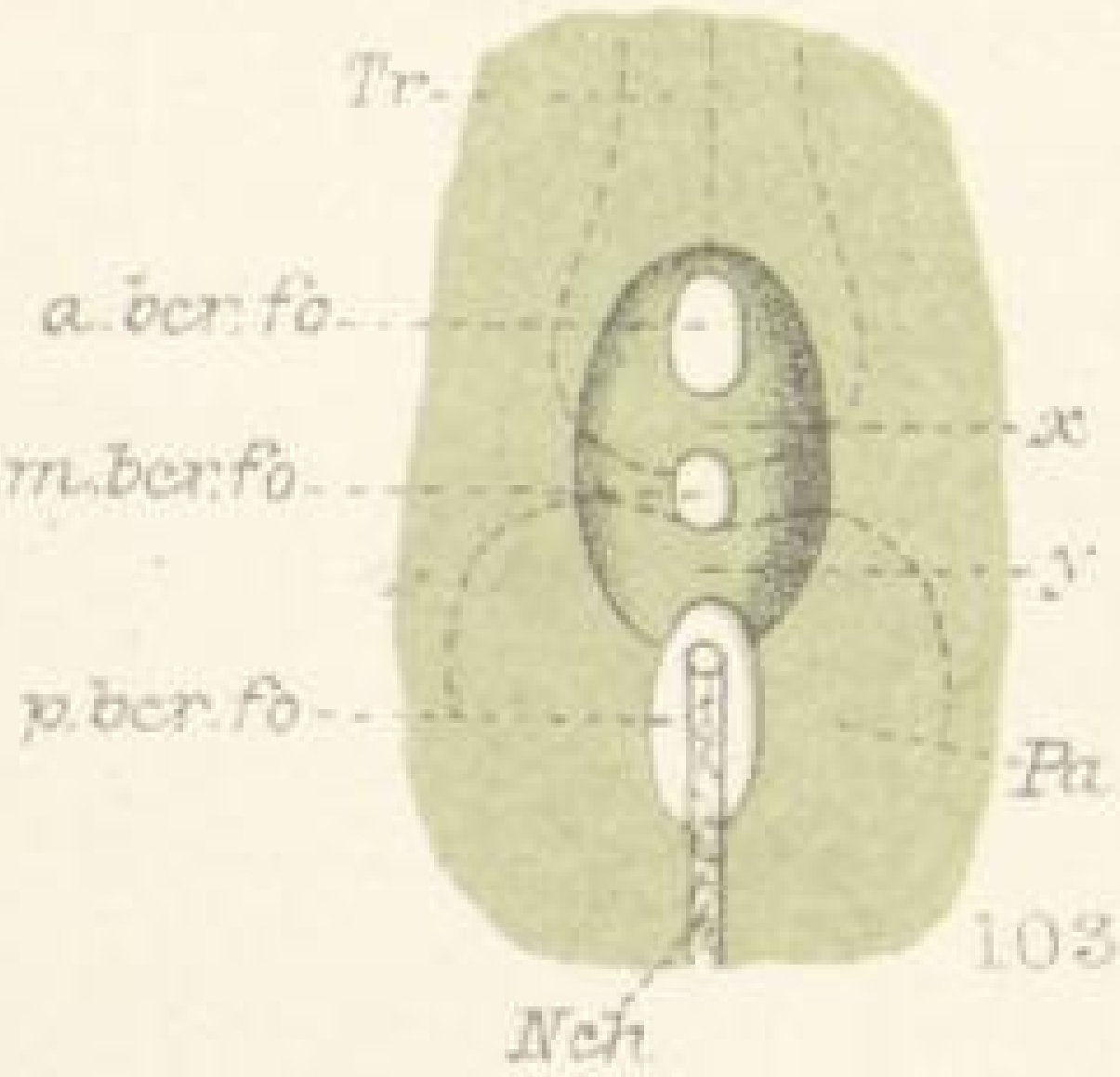

99 (x 22)

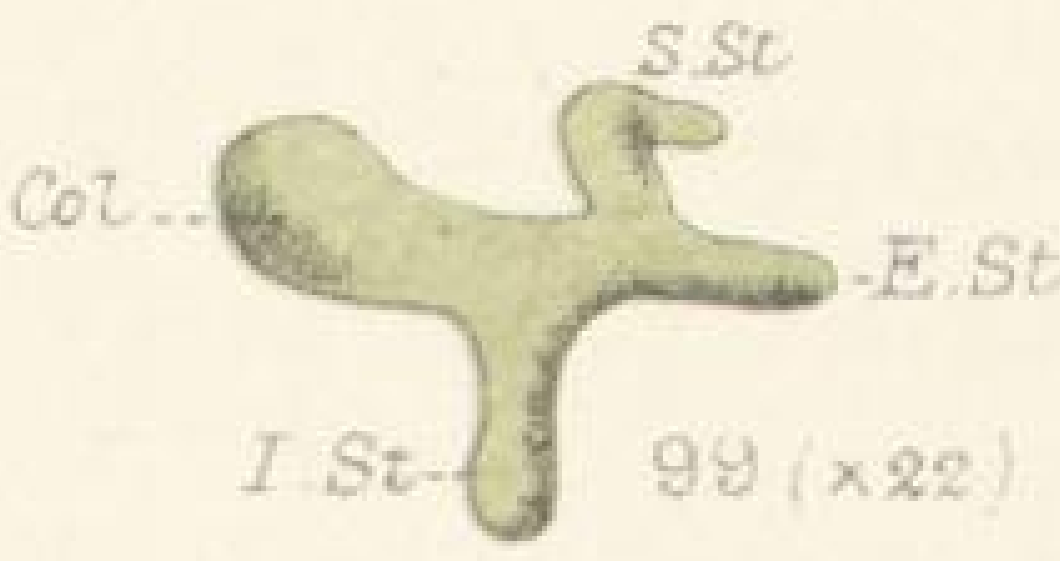

104 (x 4)

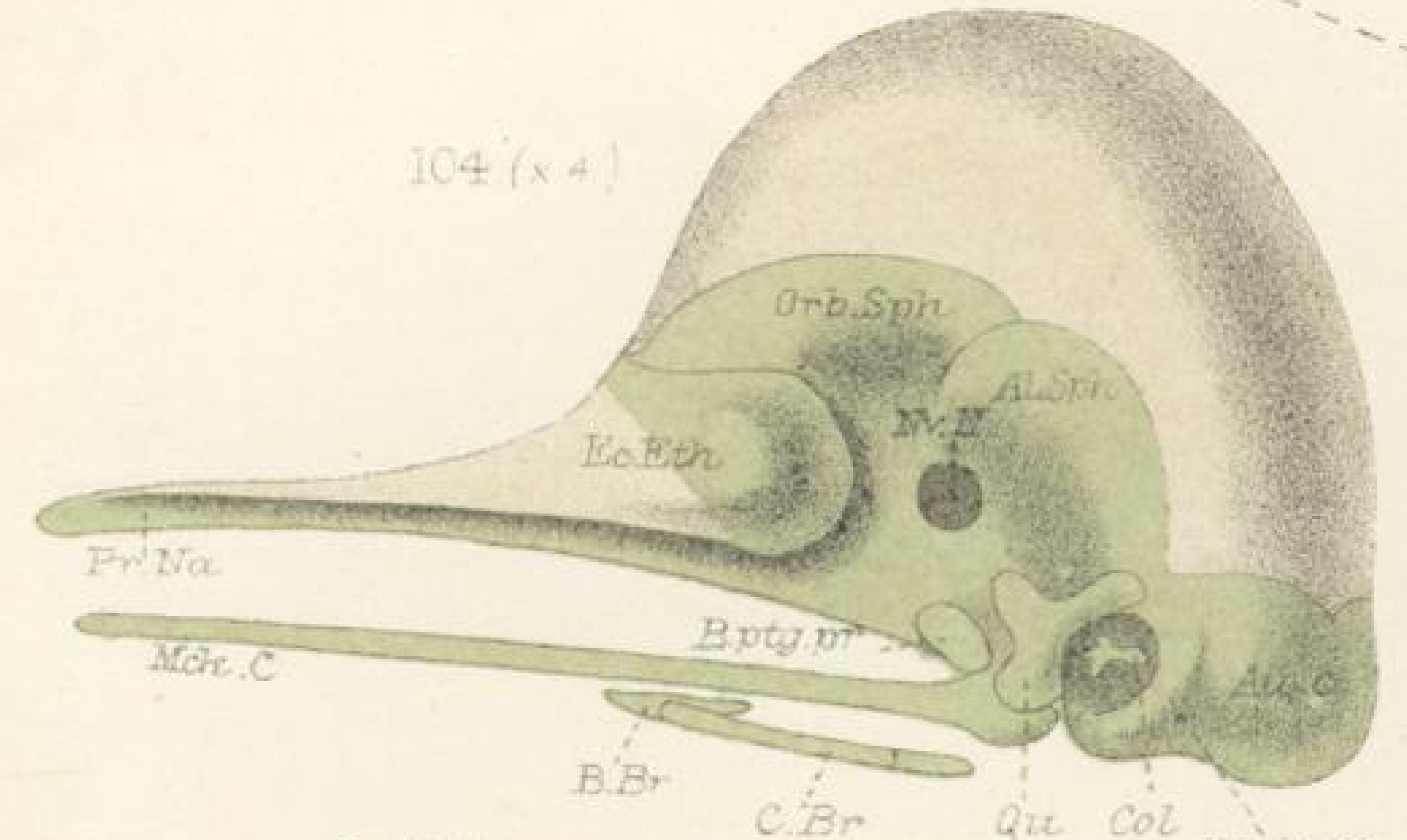

107 (x 4)

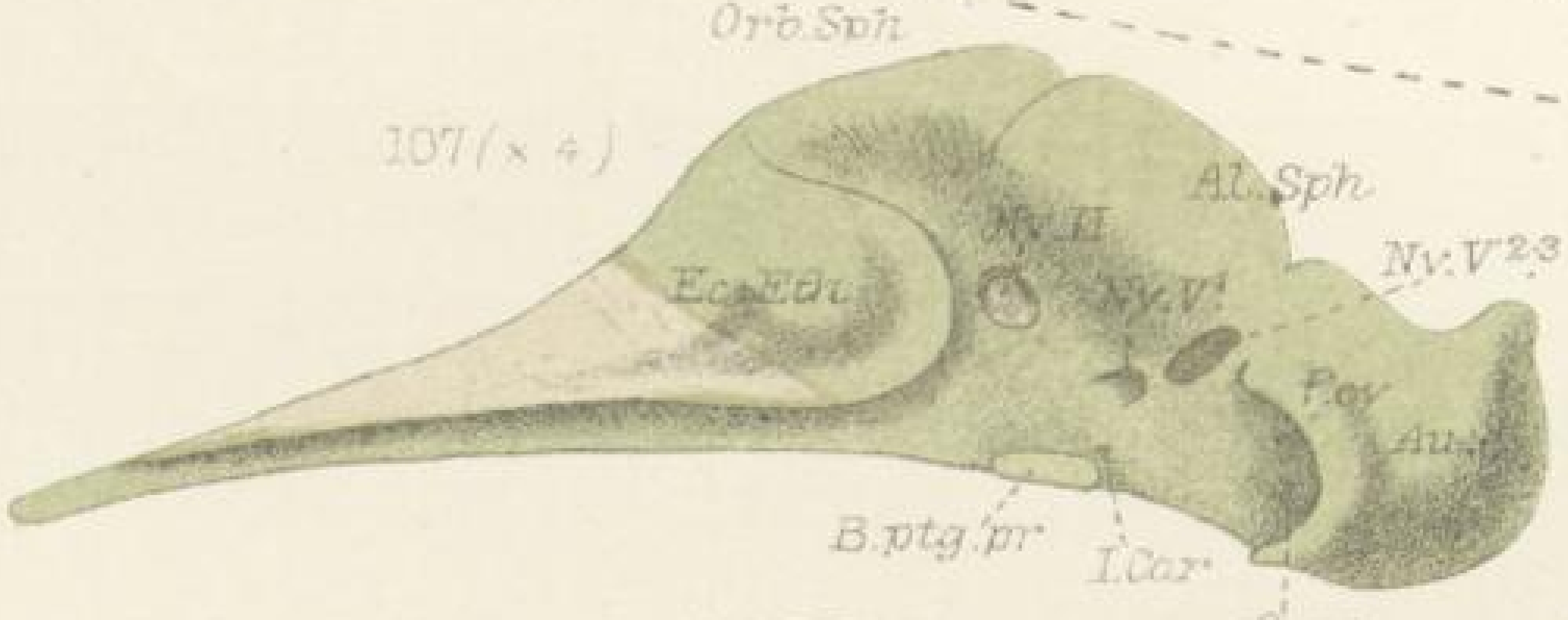

108 (x 4)

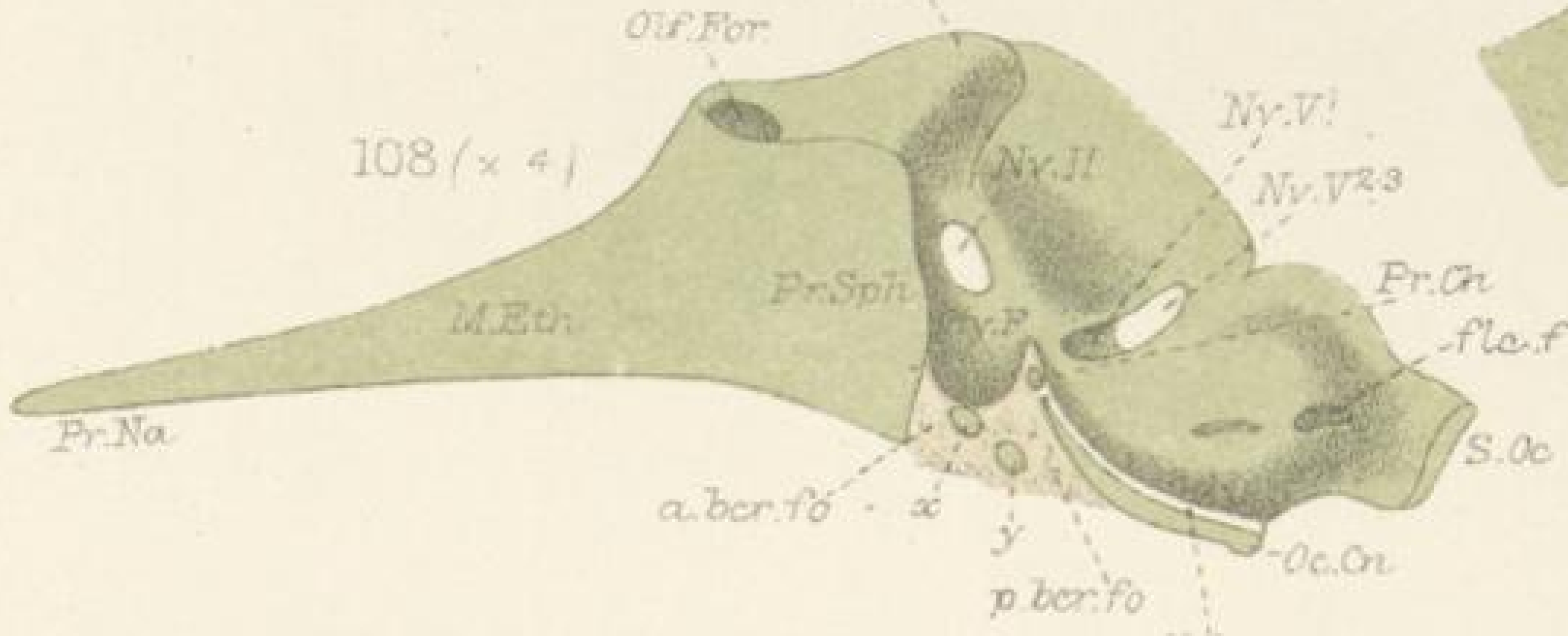

111 (x 9)

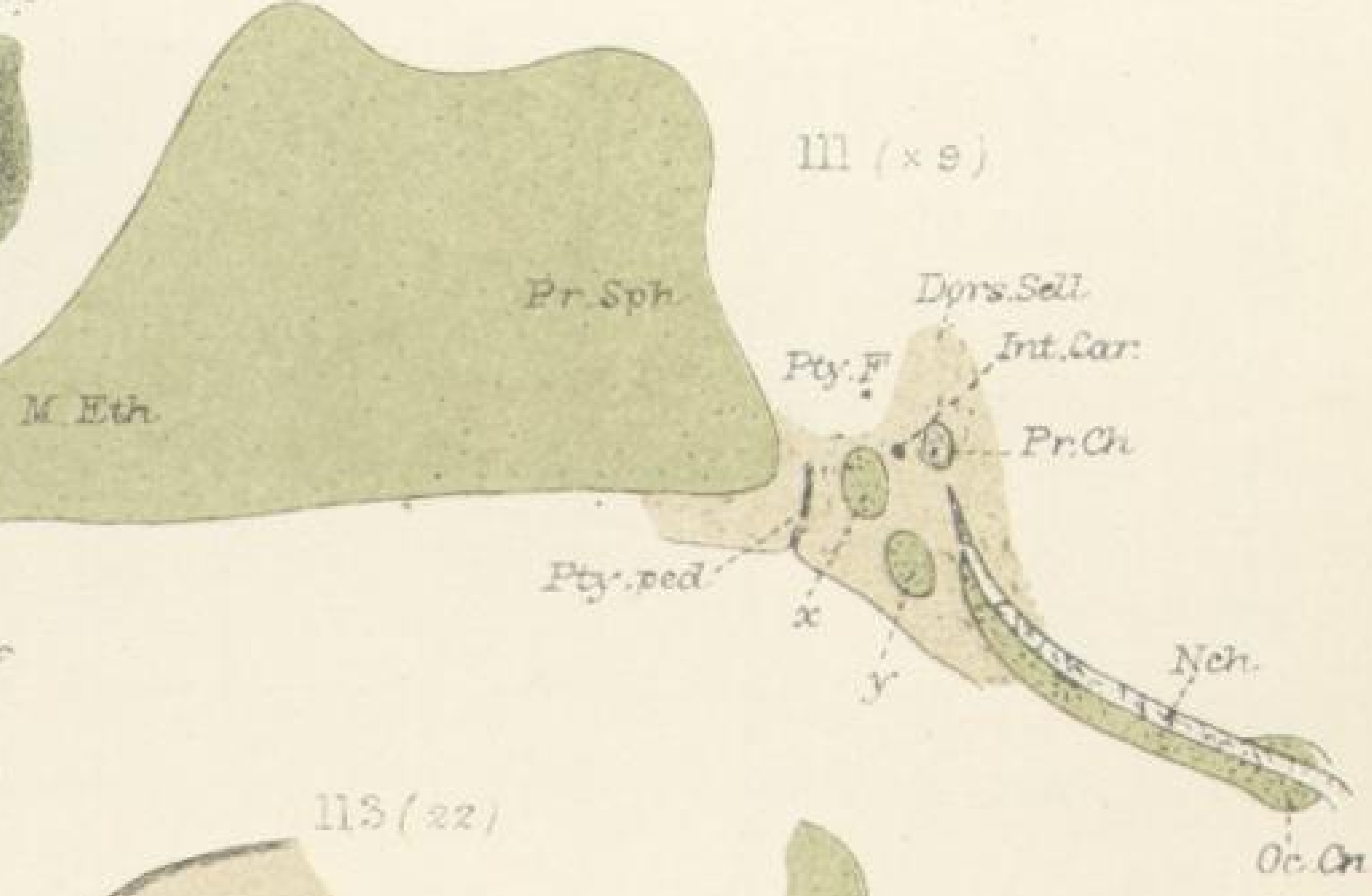

105 (x 4)

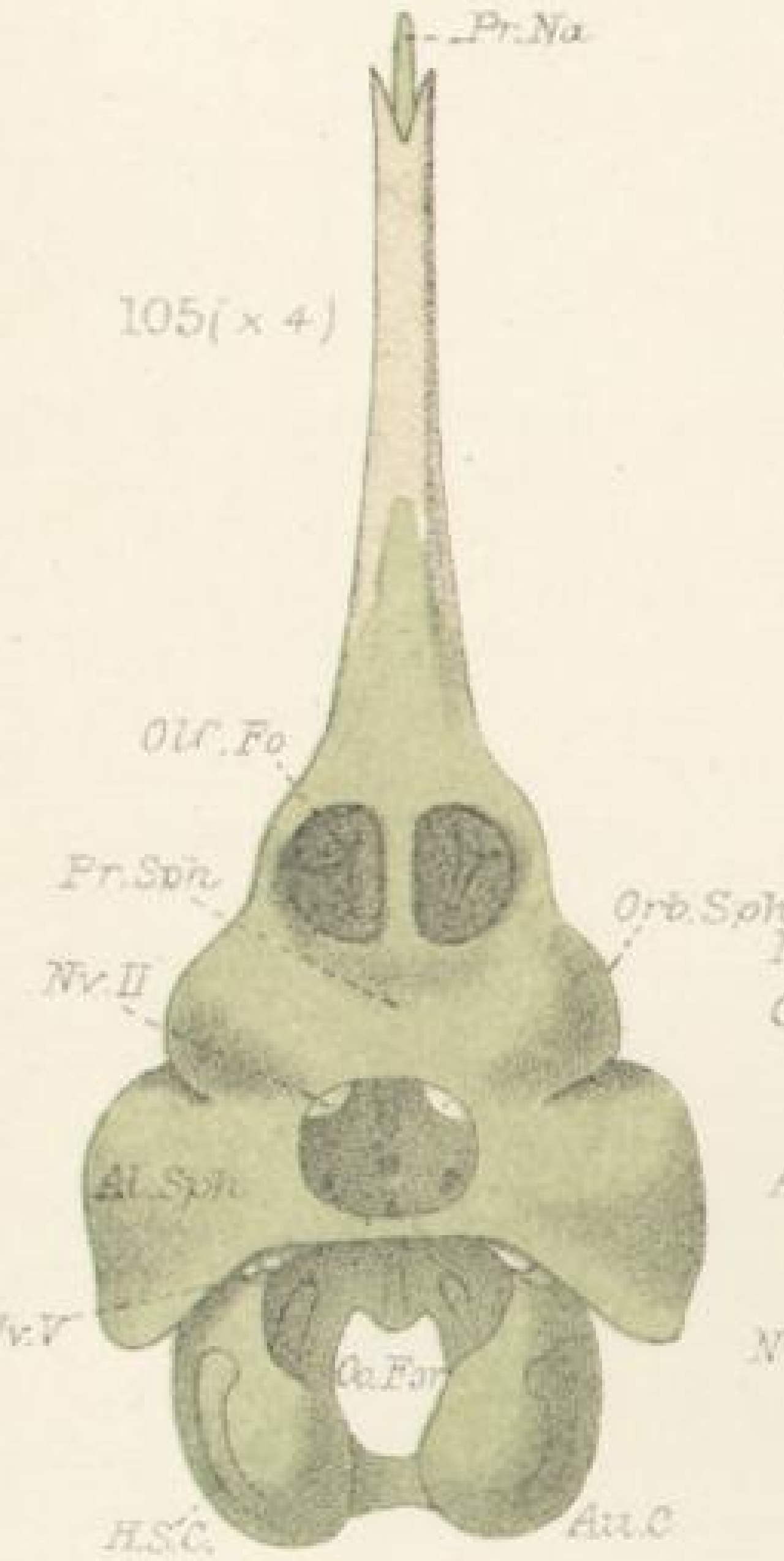

106 (x 4)

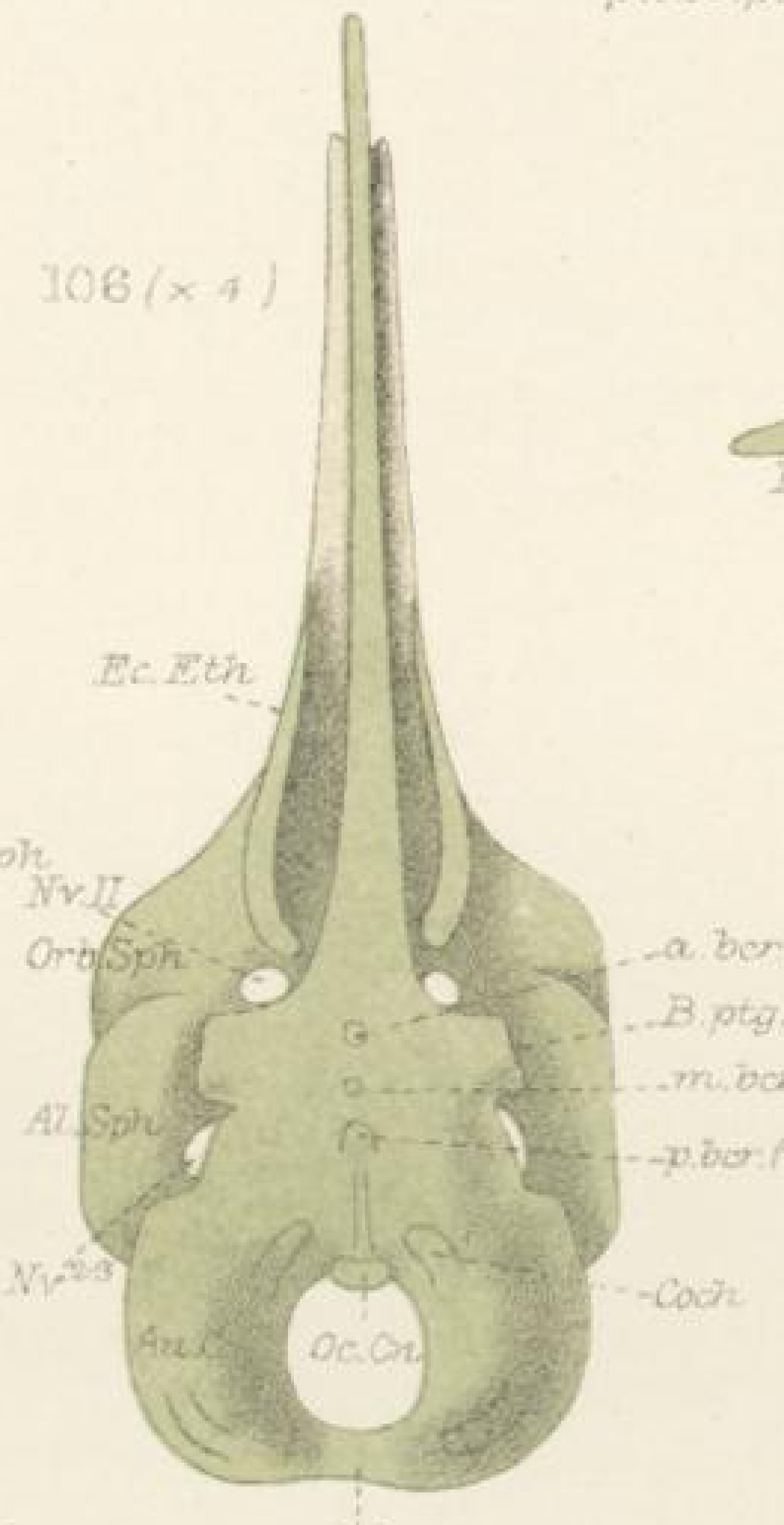

109 (x 9)

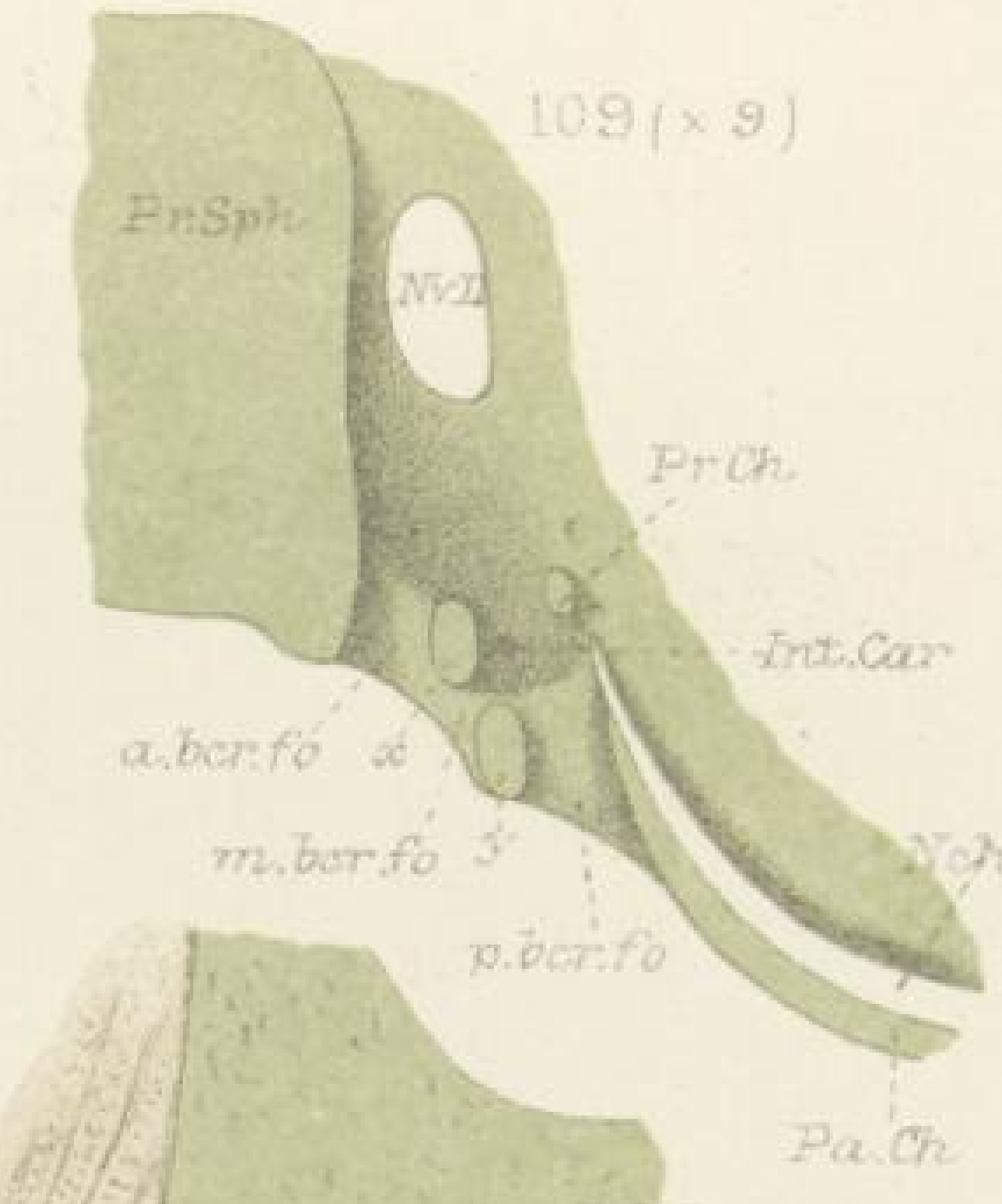

113 (22)

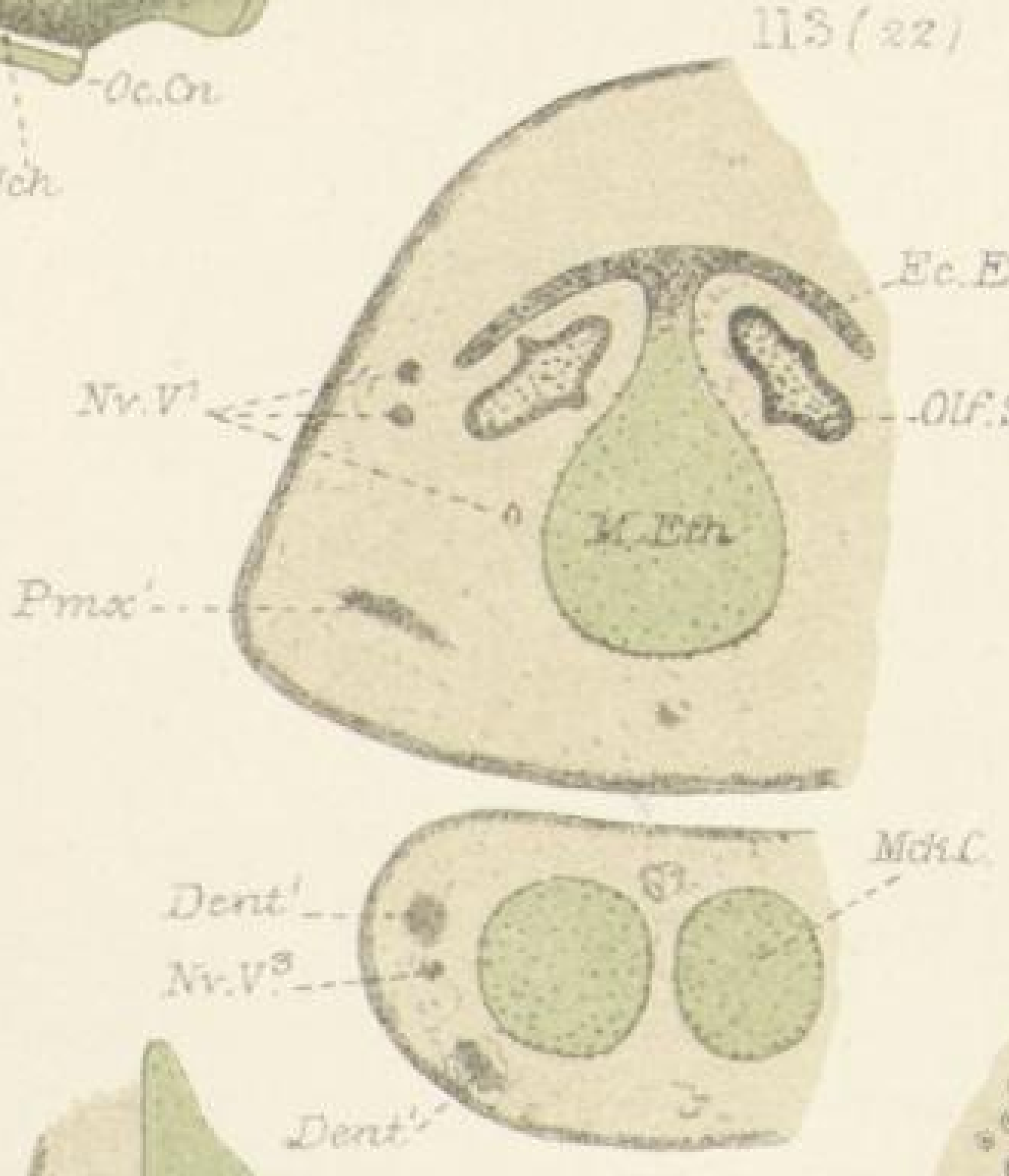

112 (x 9)

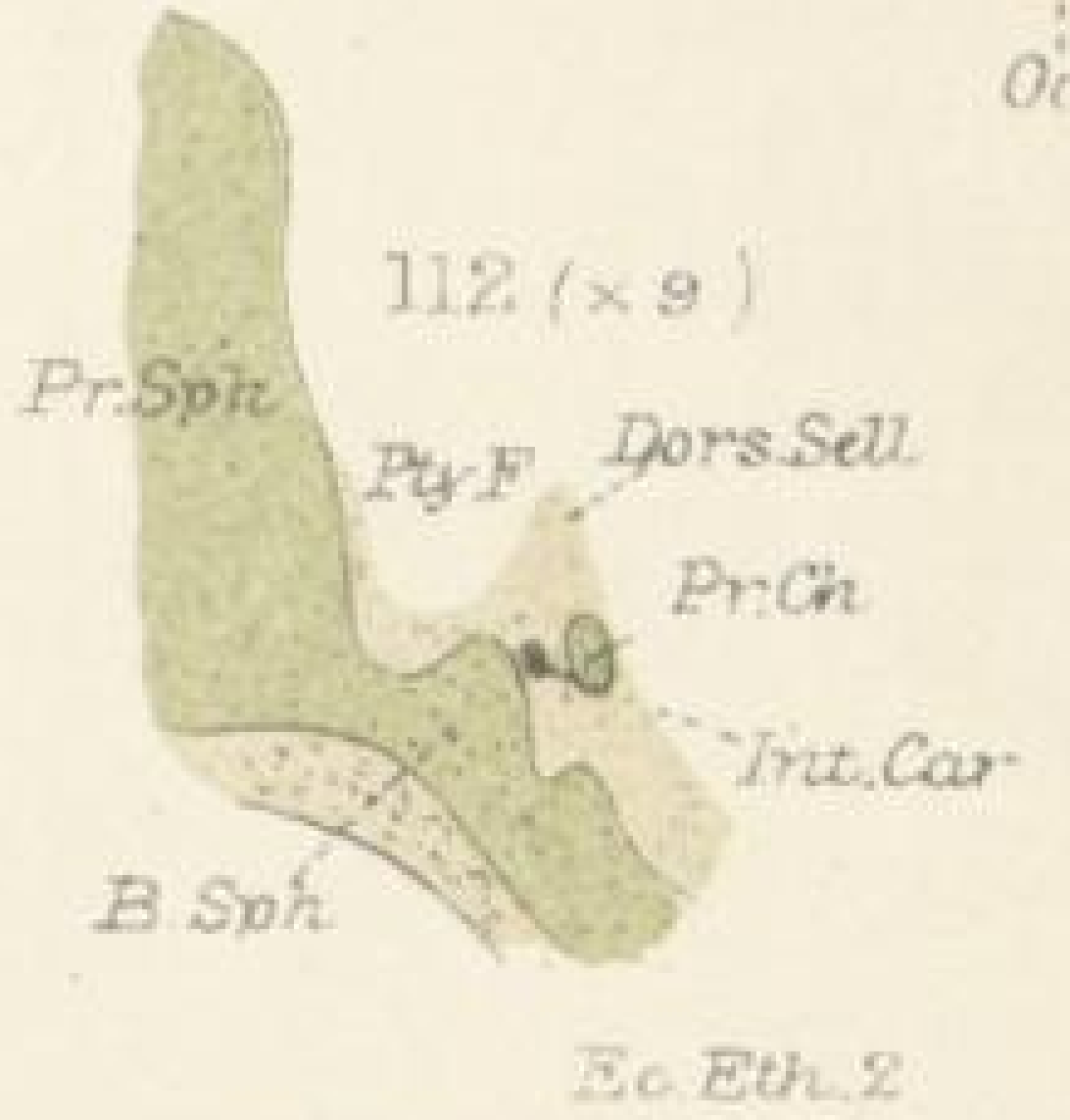

114 (x 150)

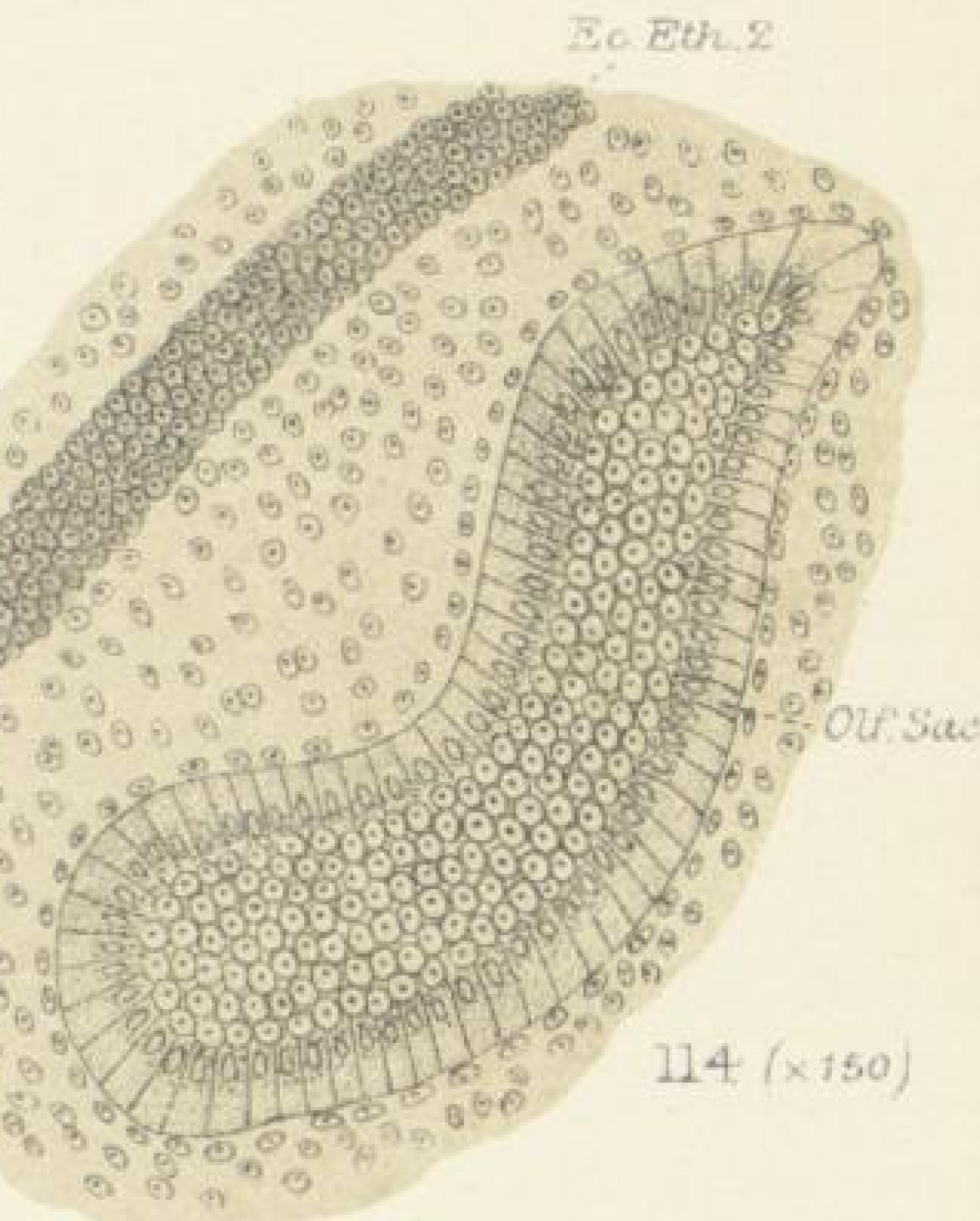

115 (x 9)

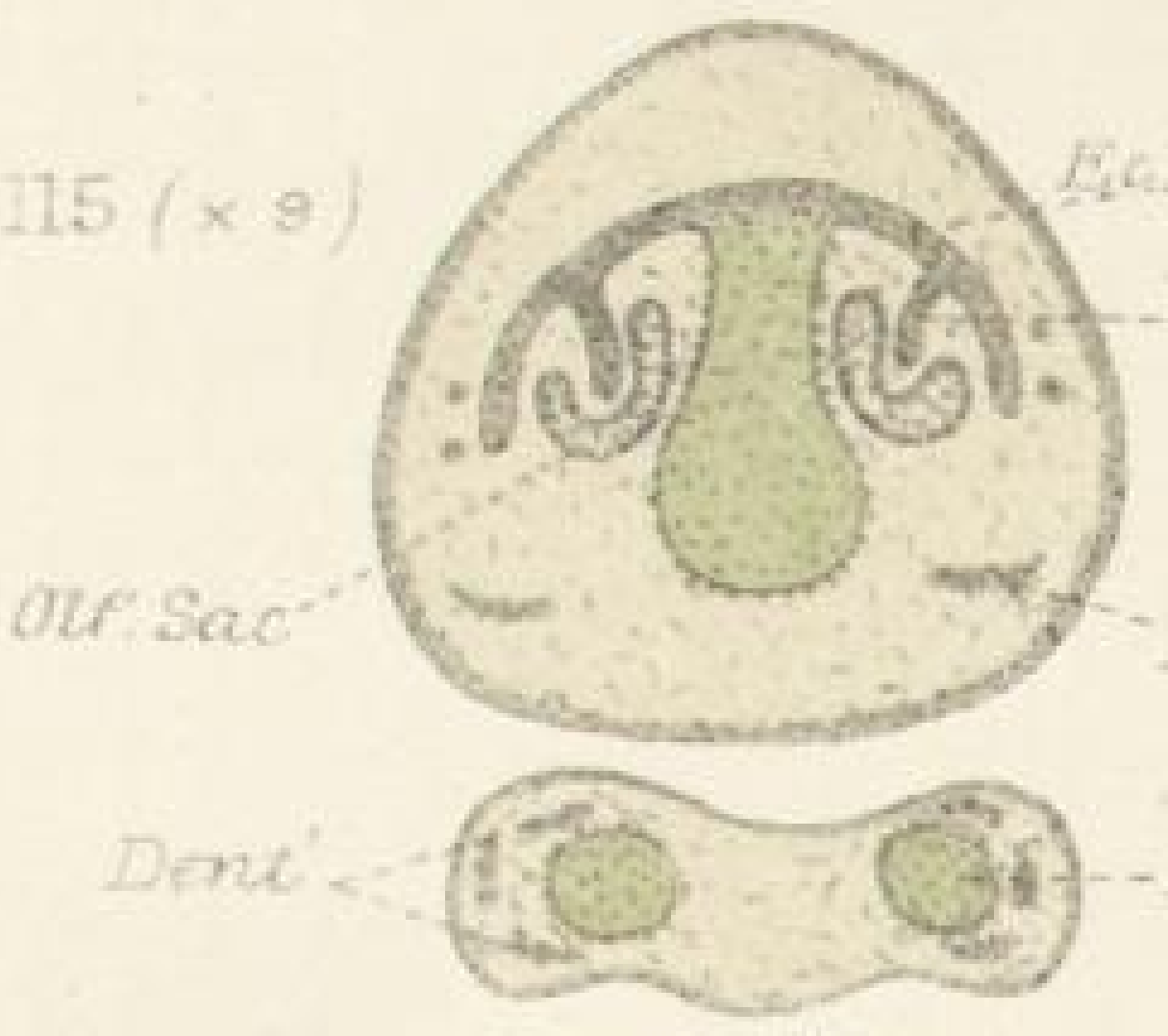

117 (x 22)

118 (x 9)

116 (x 9)

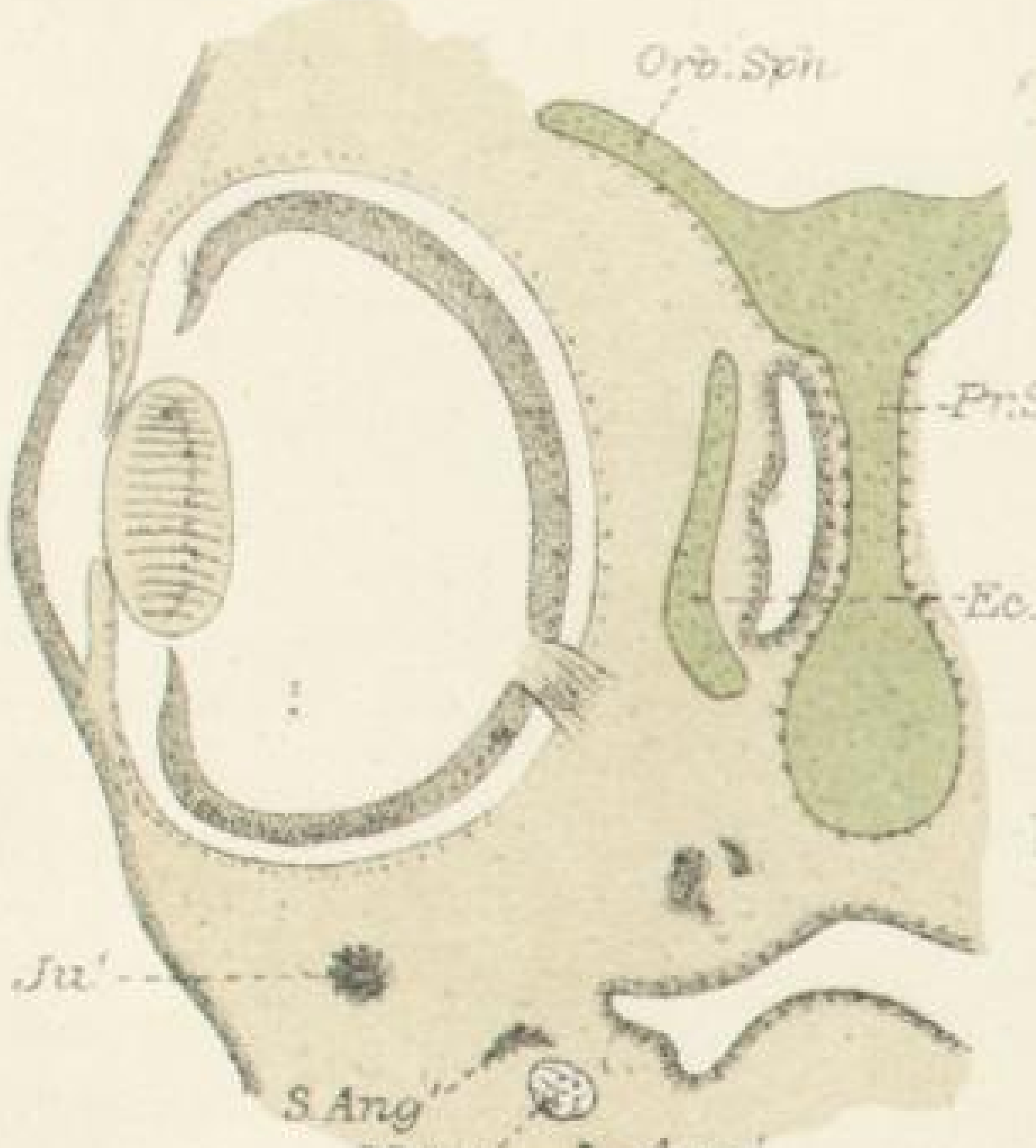

119 (x 22)

110 (x 9)

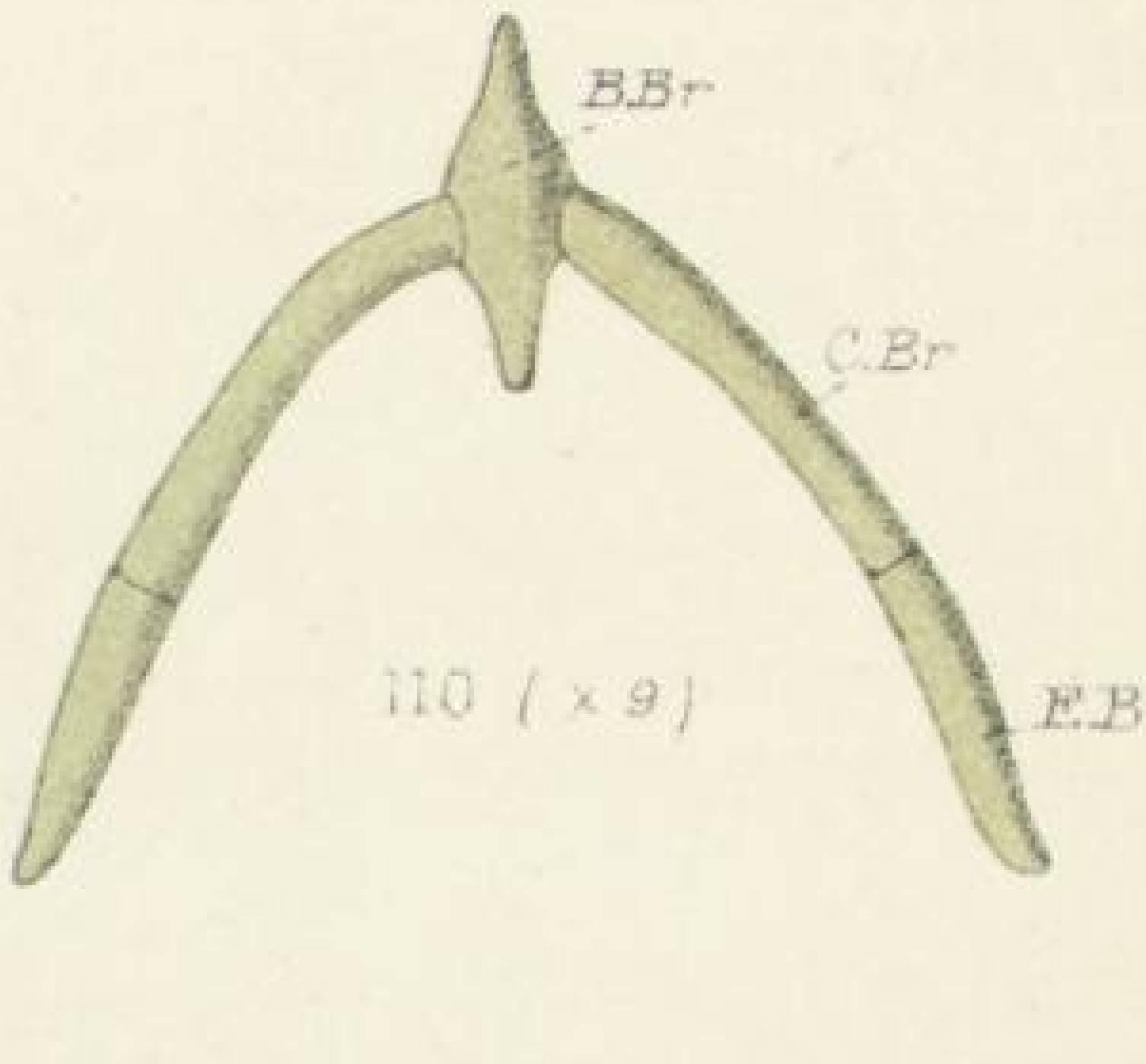

APTERYX. Skull: Stages E and F.

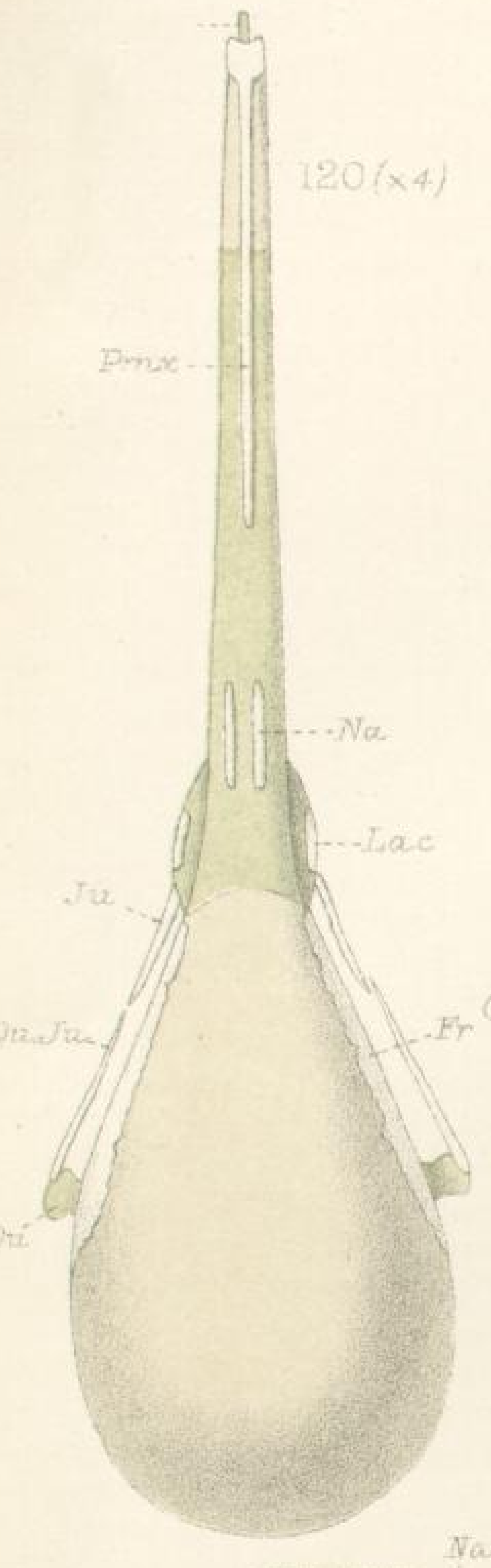
120 (×4)

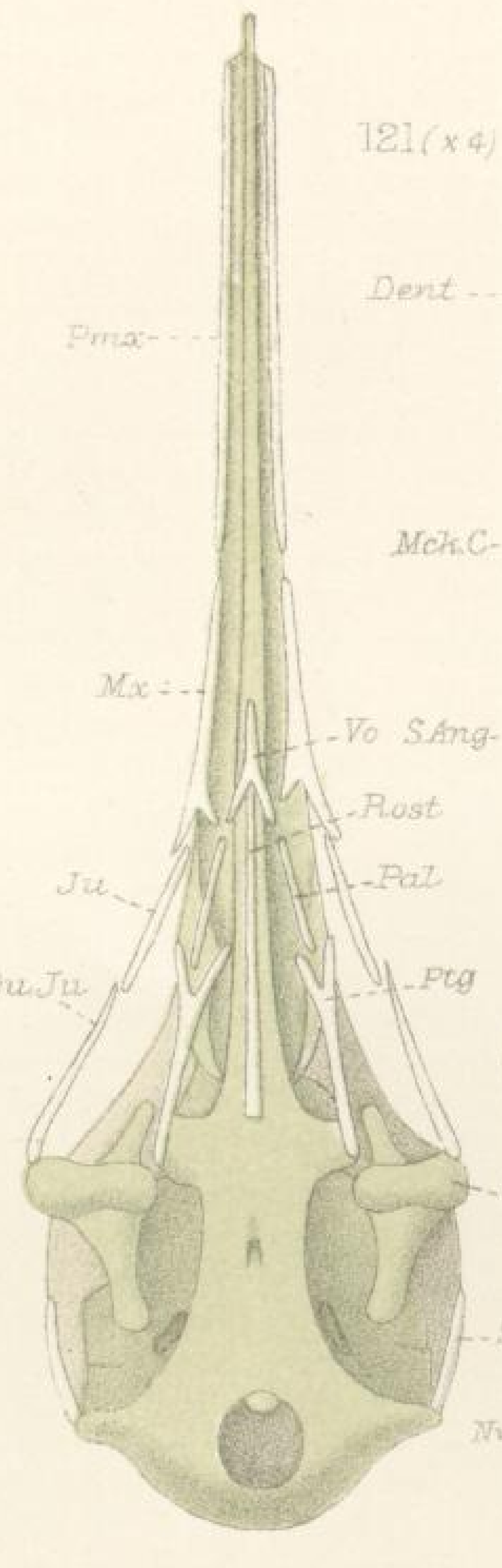
121 (×4)

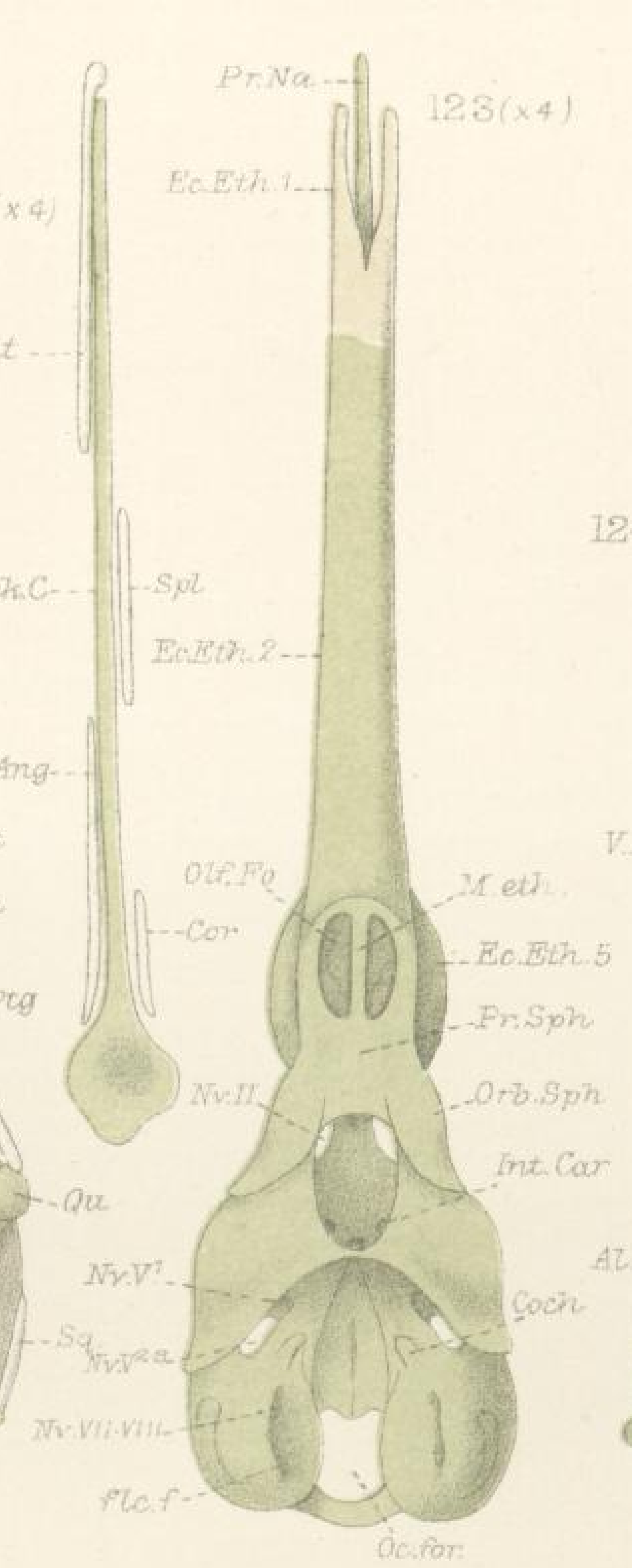
123 (×4)

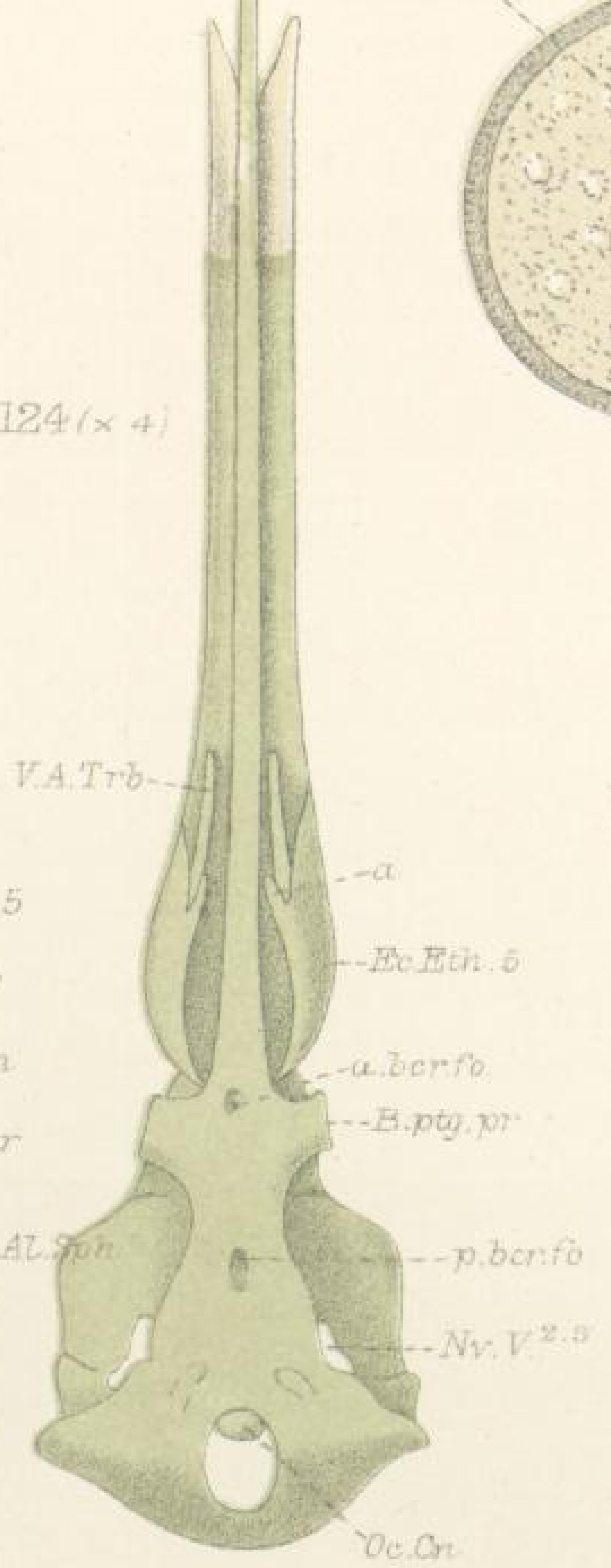
124 (×4)

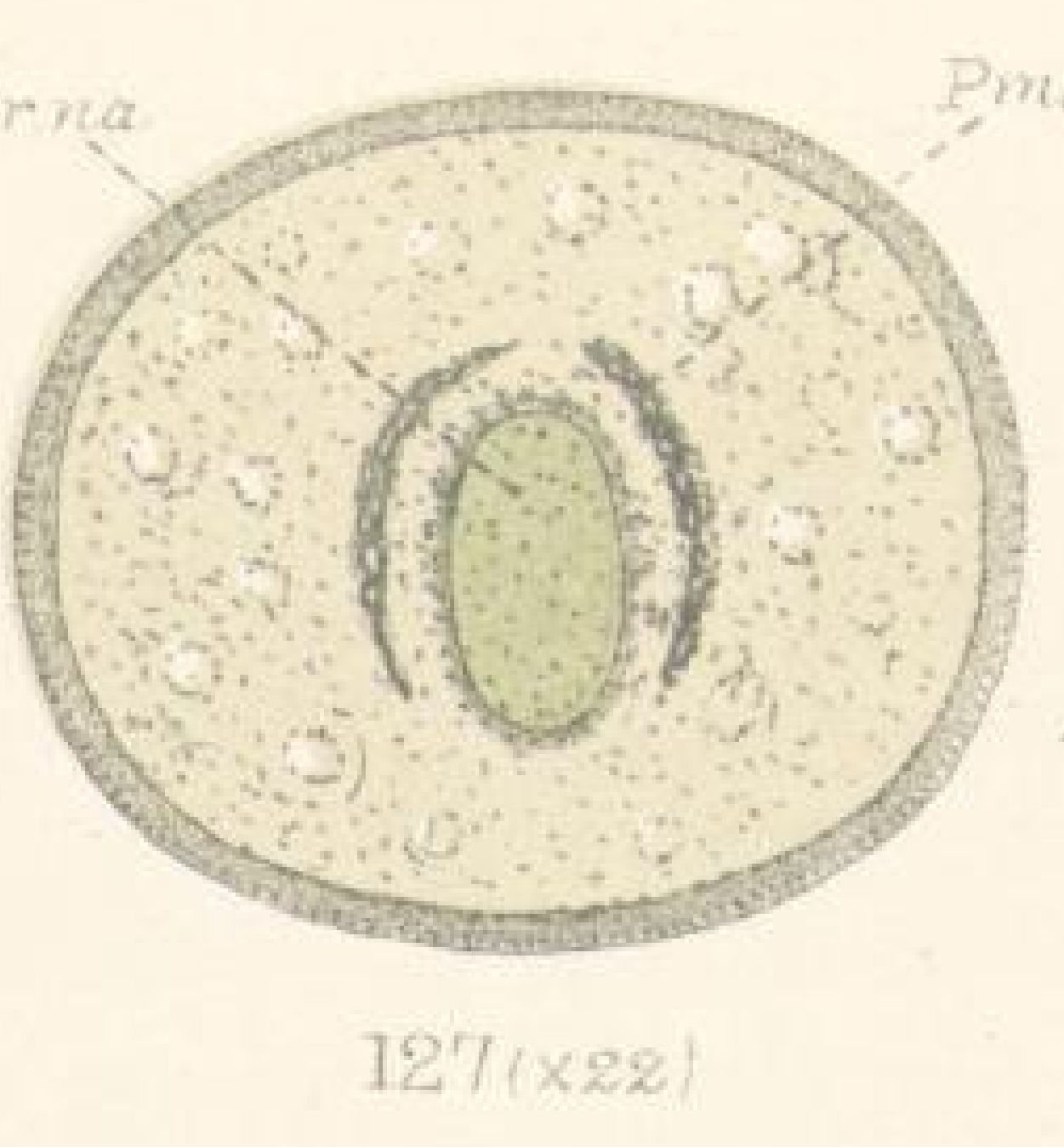
127 (×22)

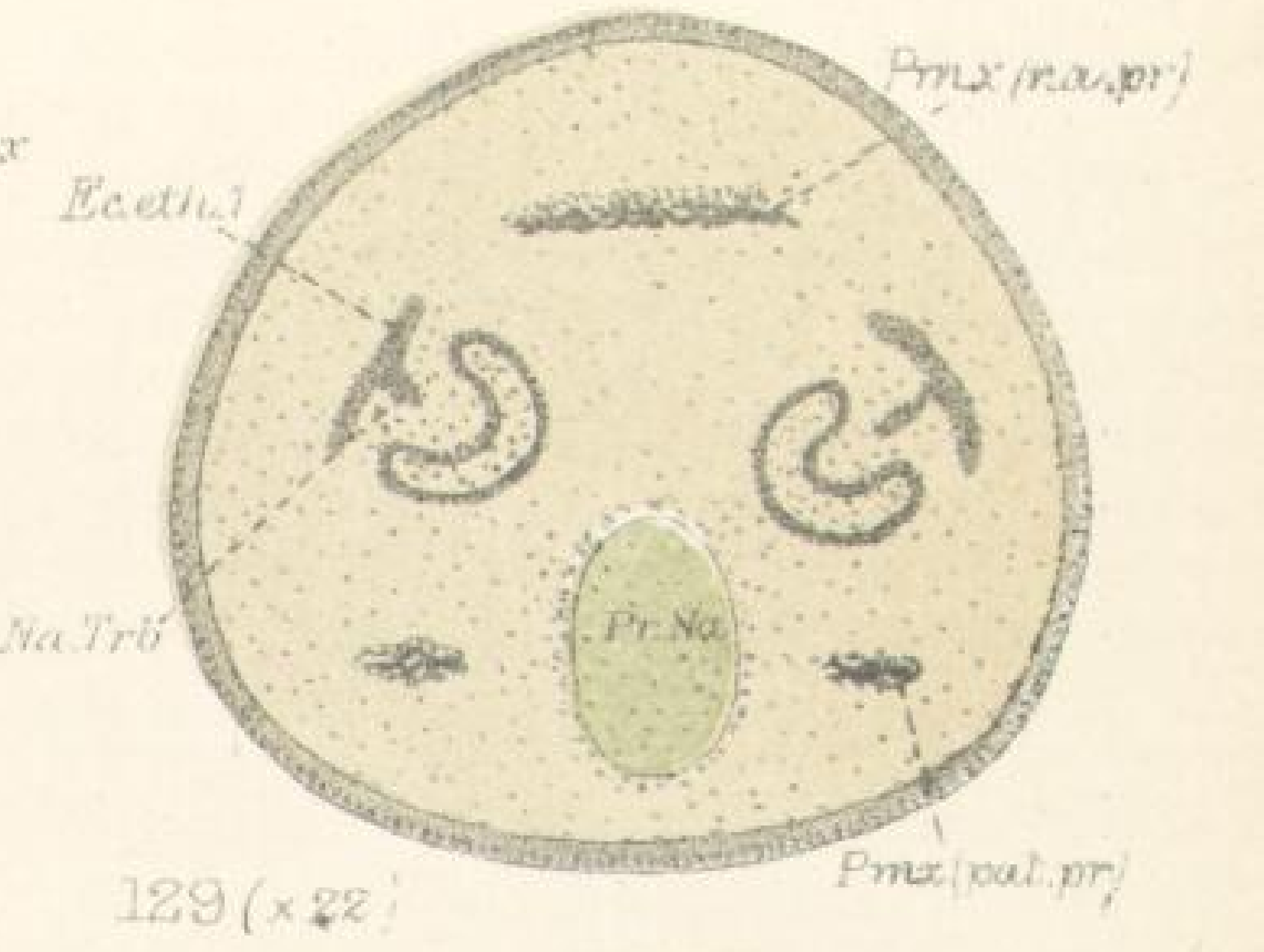
129 (×22)


128 (×50)

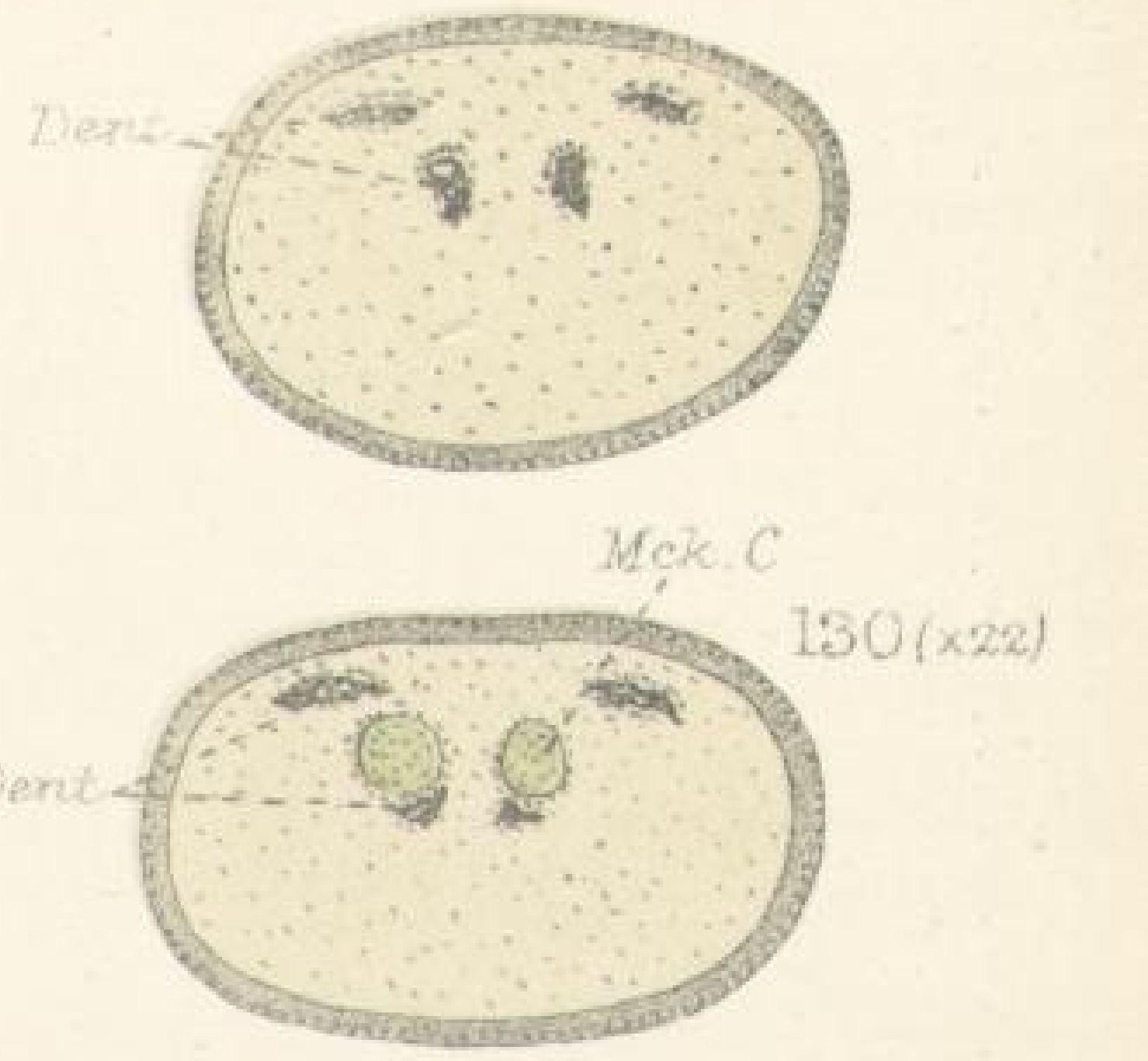
130 (×22)

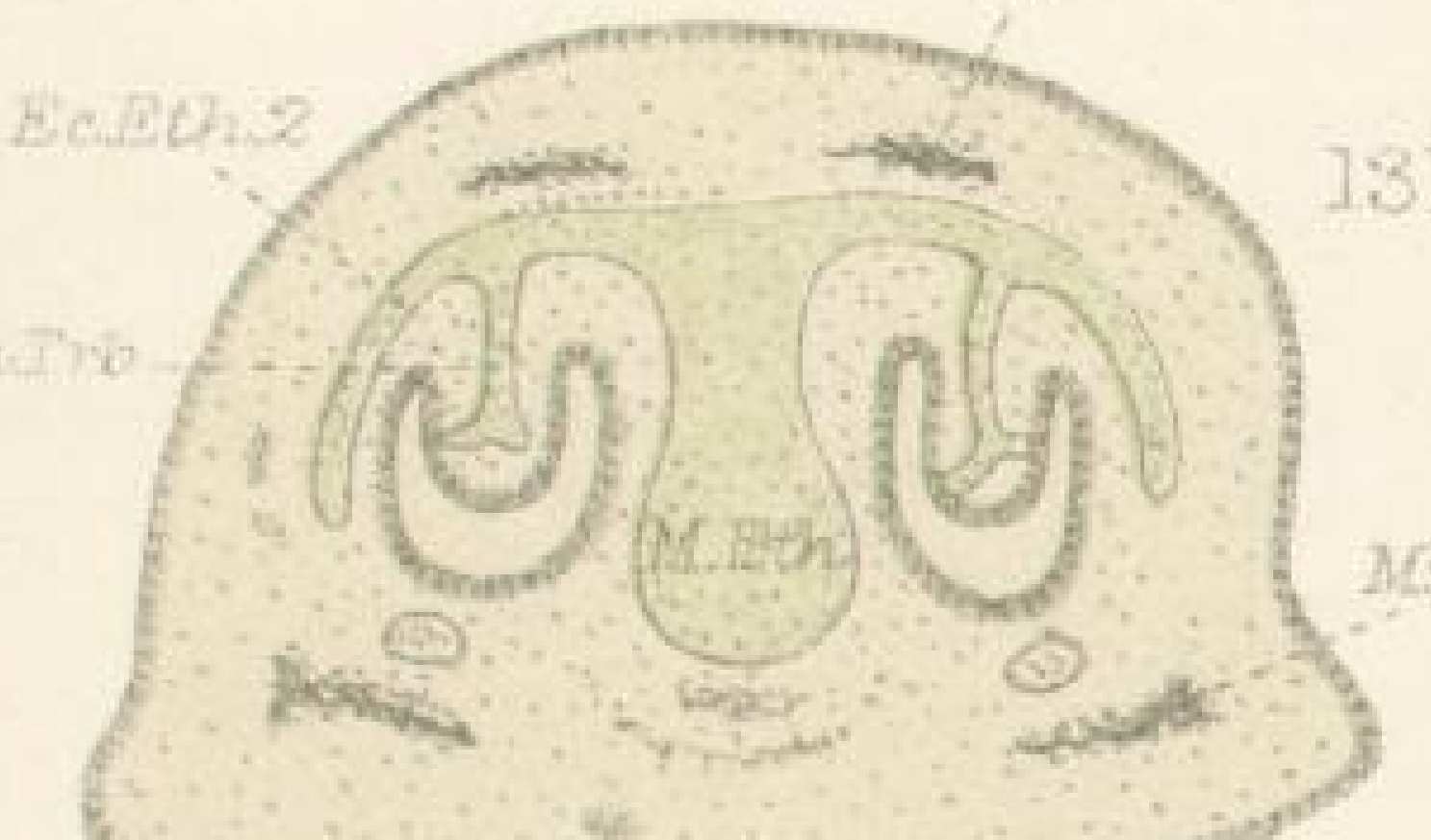
131 (×9)


122 (×4)


136 (×9)


132 (×9)


125 (×4)

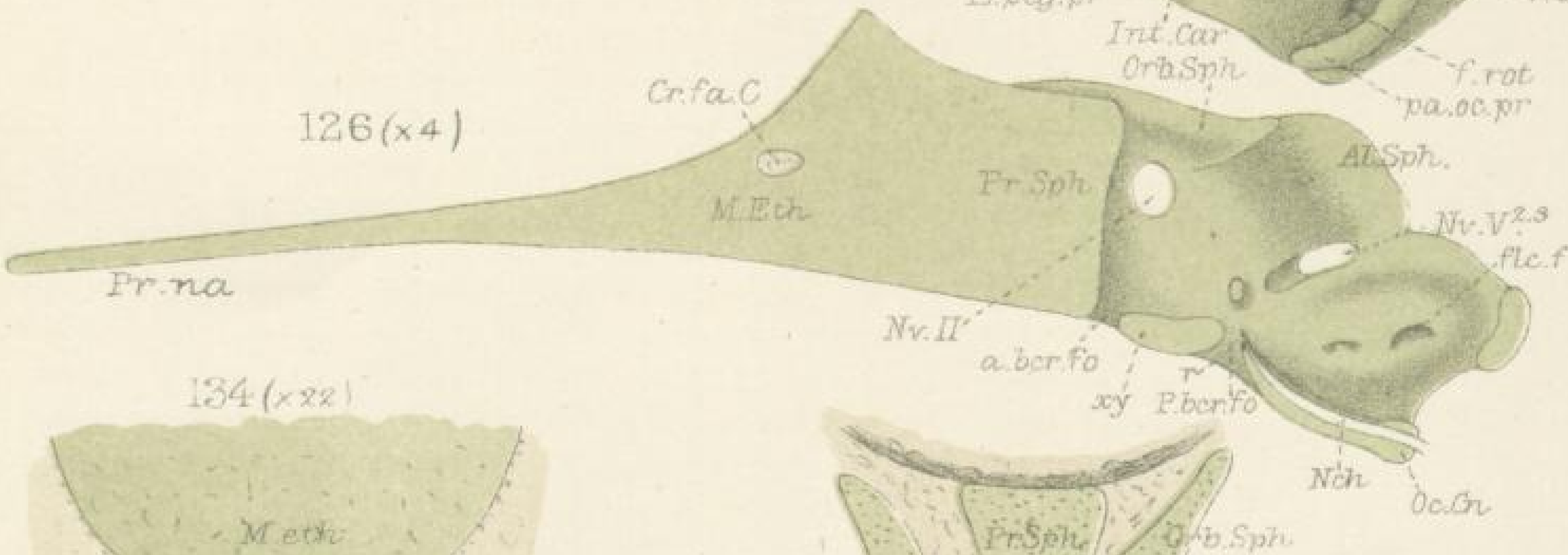
126 (×4)


137 (×9)

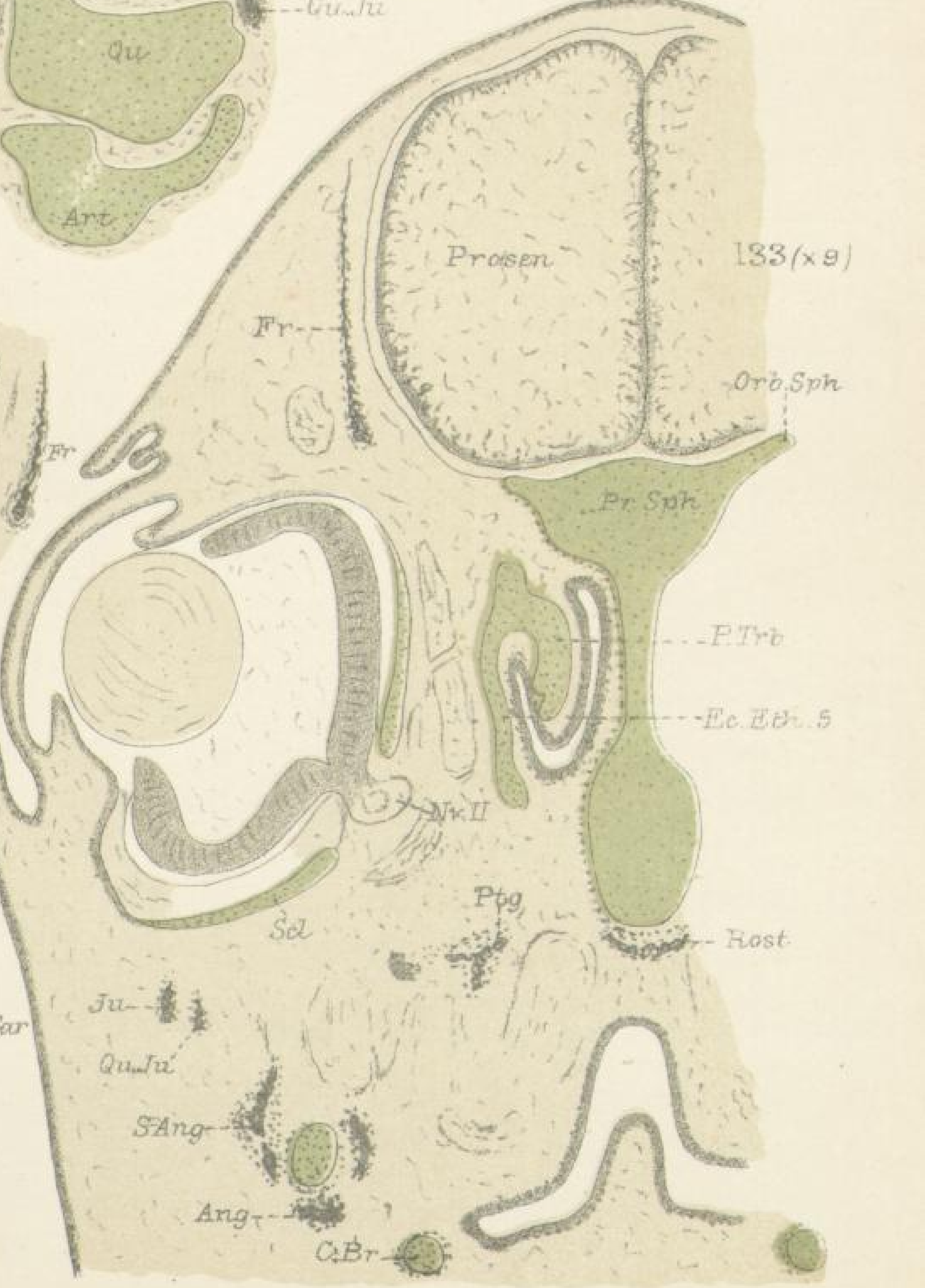
133 (×9)


134 (×22)

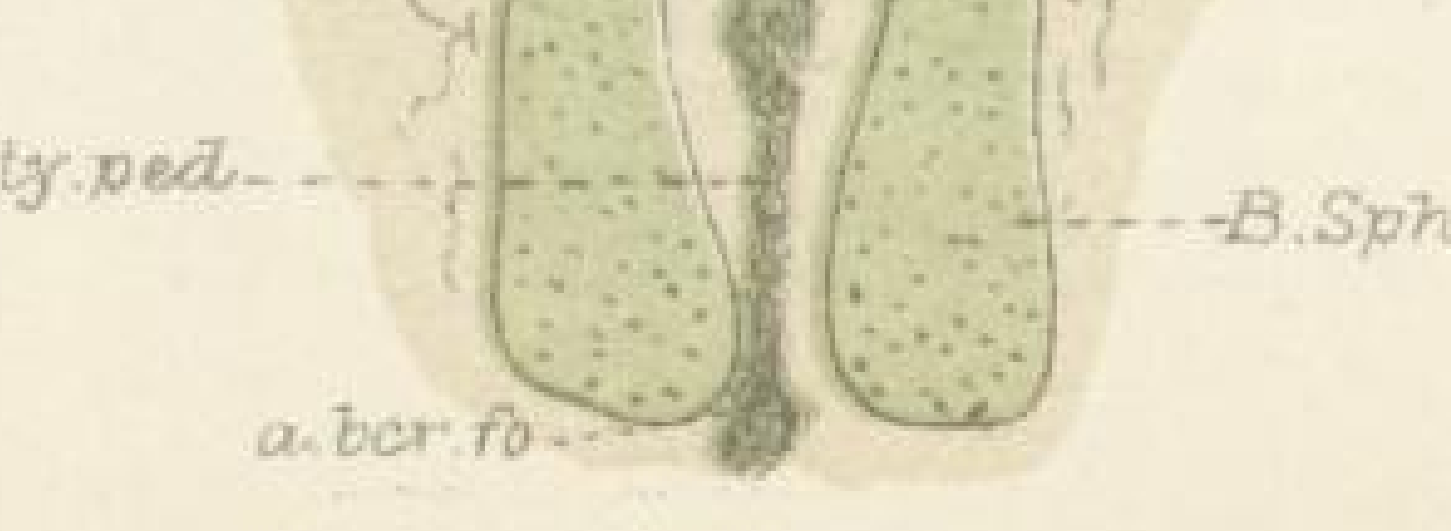
135 (×9)

APTERYX. Skull: Stage G.

138 (× 9)

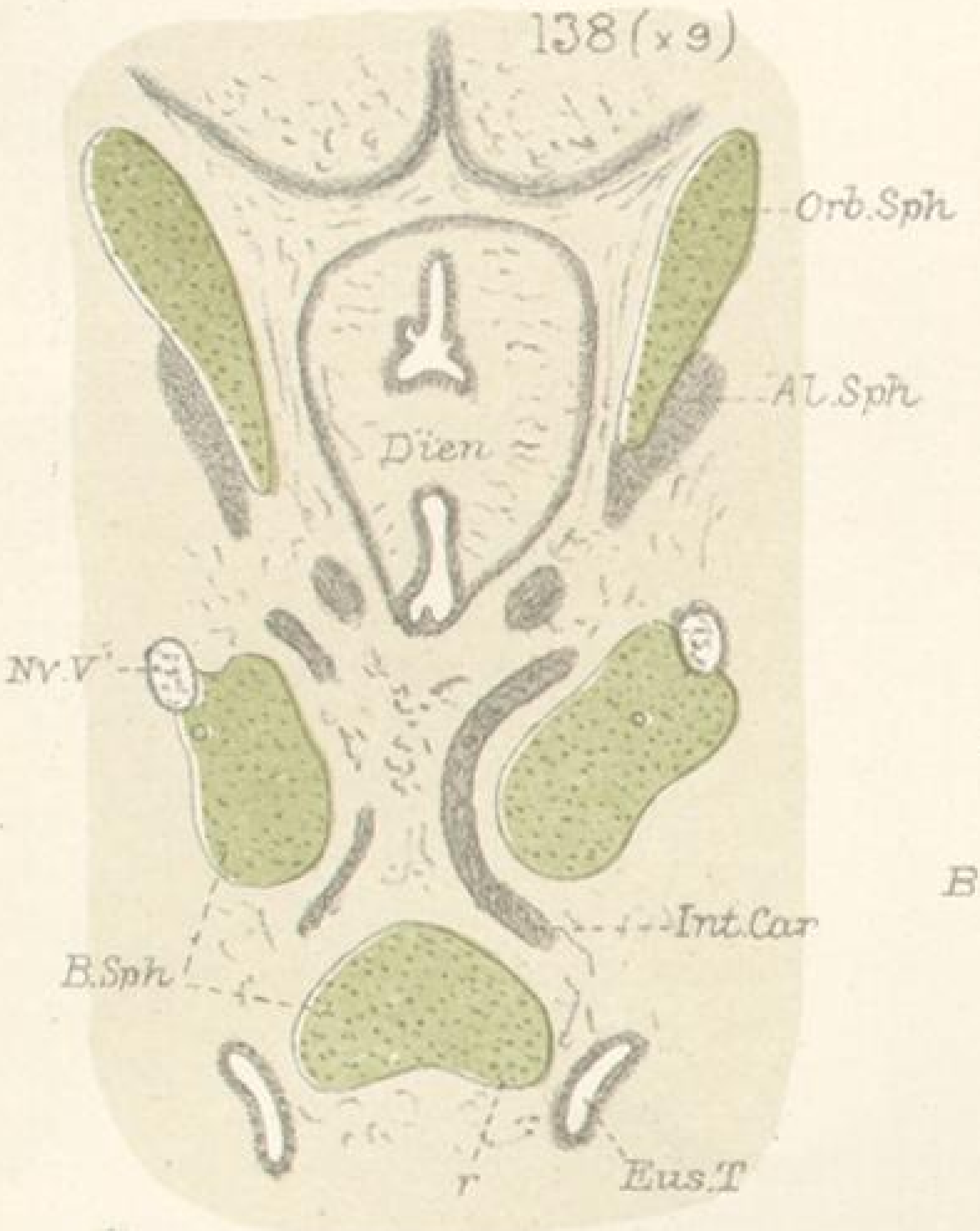

140 (× 9)

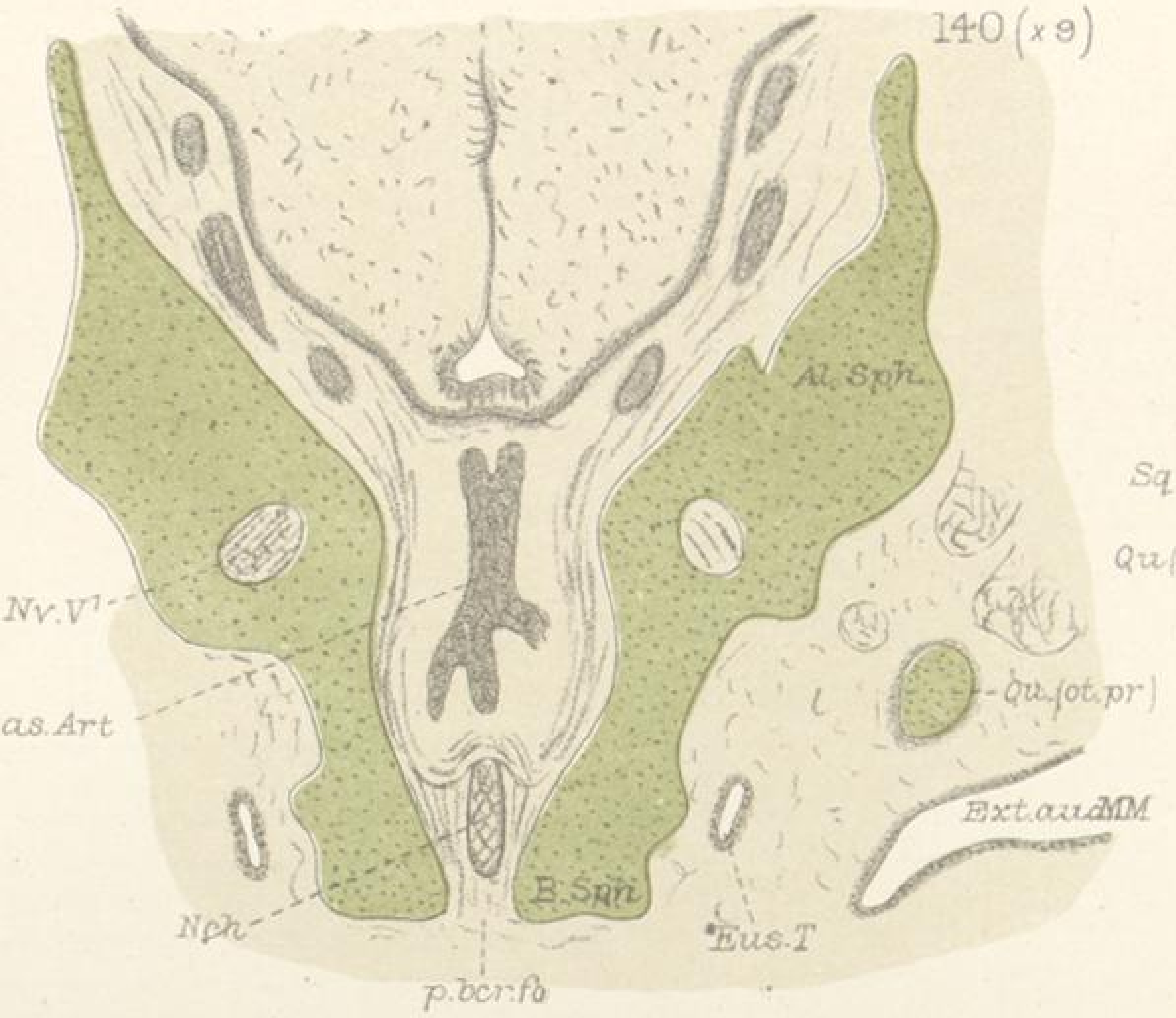

141 (× 9)

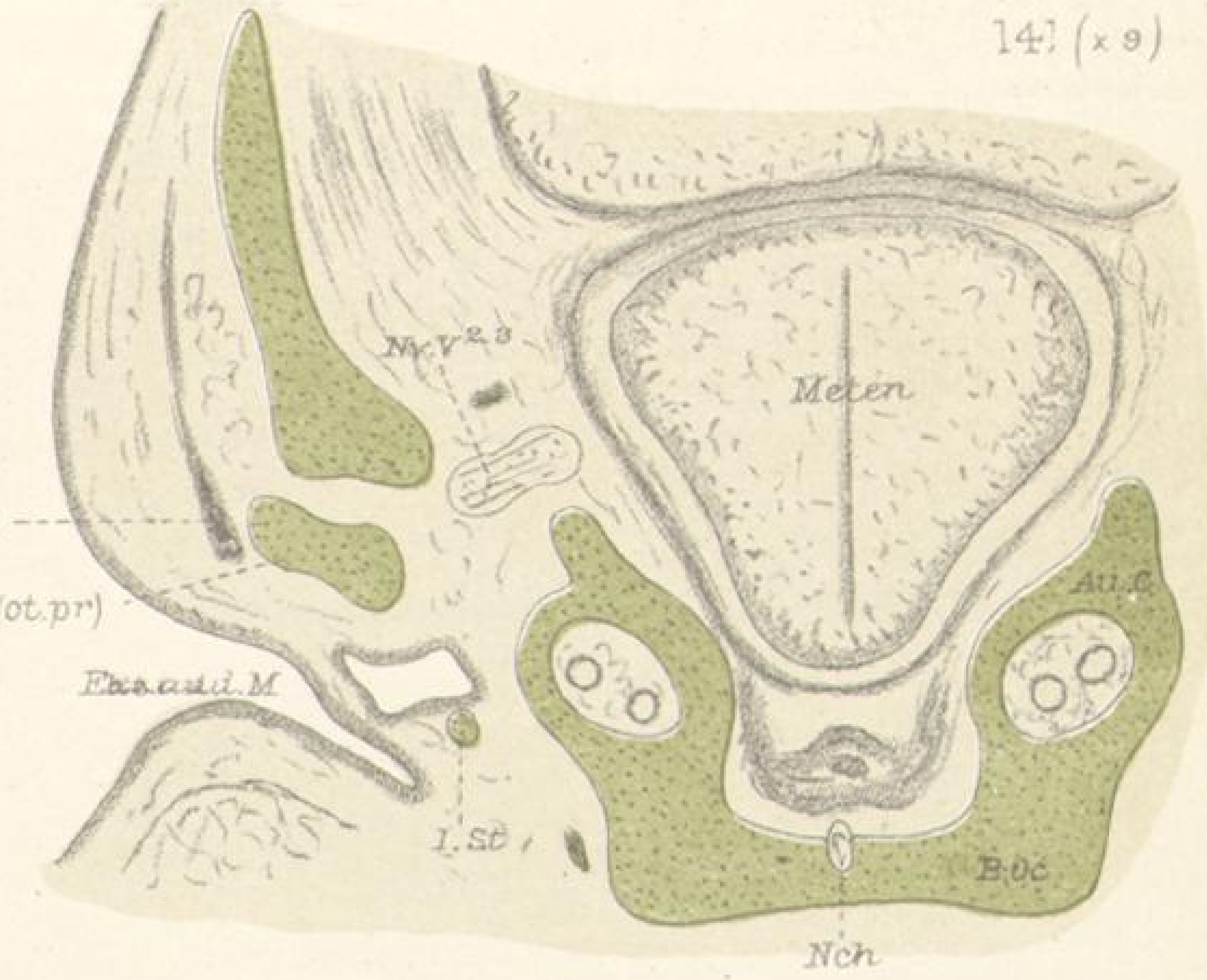

139 (× 9)

142 (× 9)

143 (× 9)

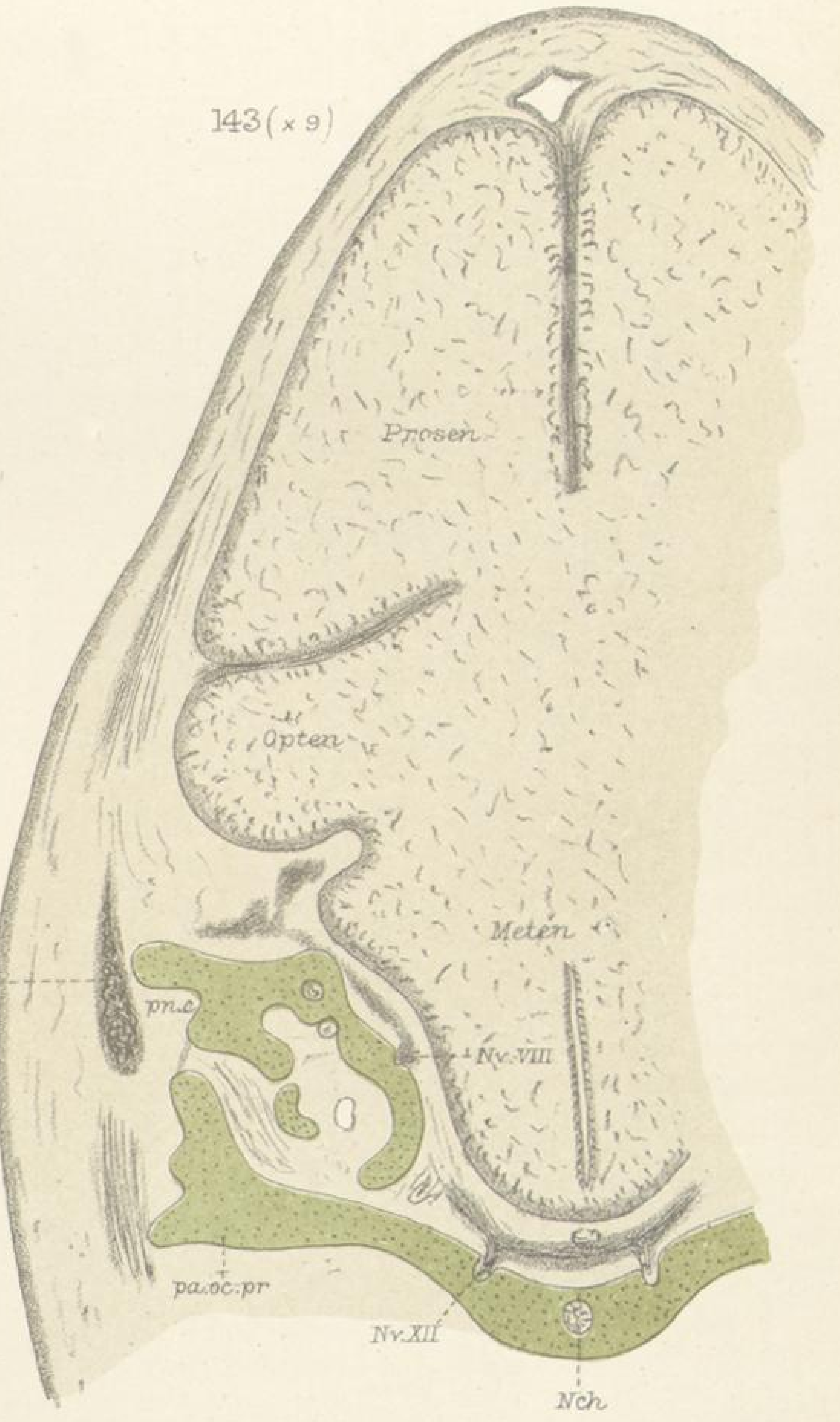

145 (× 9)

144 (× 9)

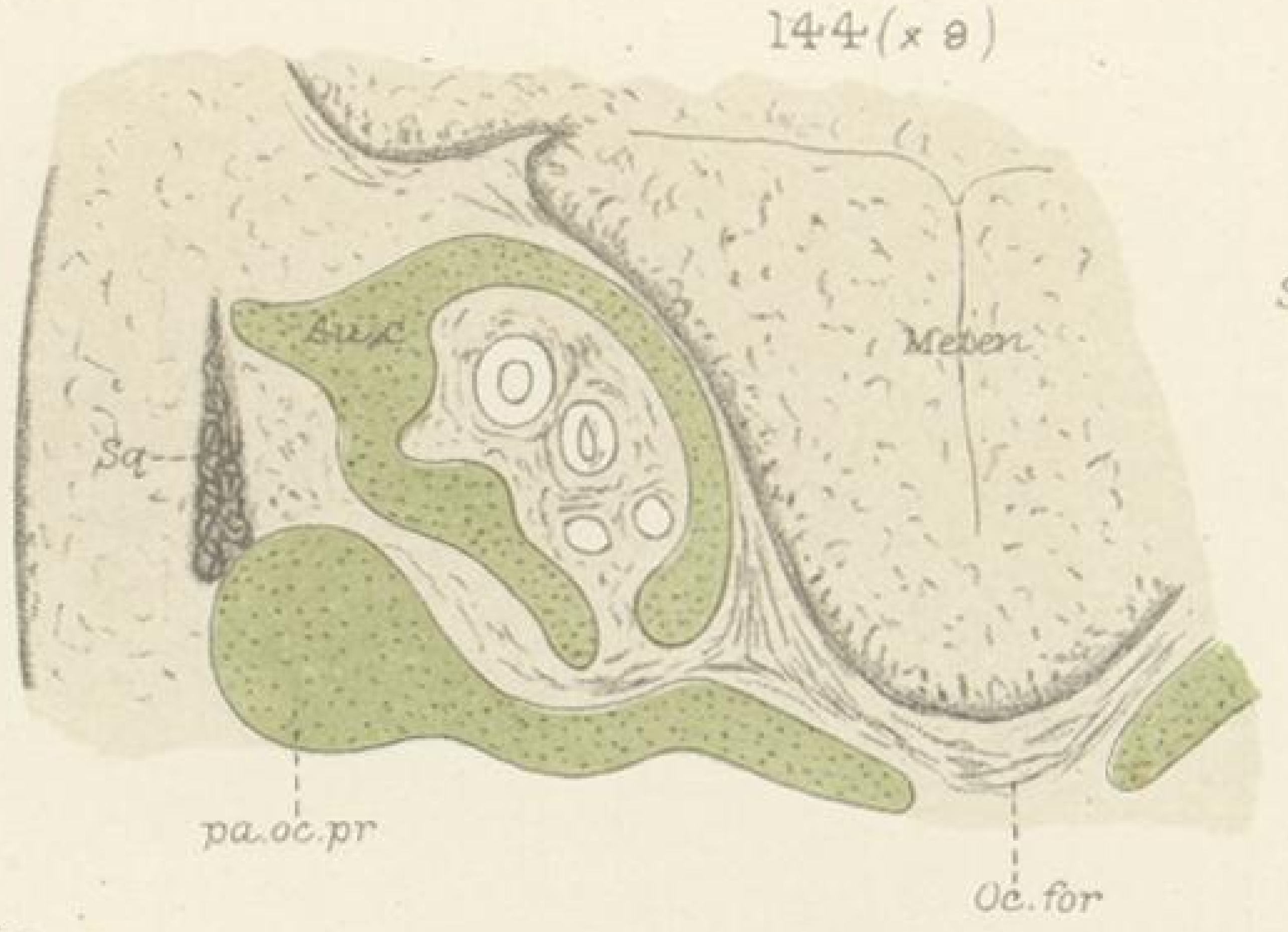

146 (× 2)

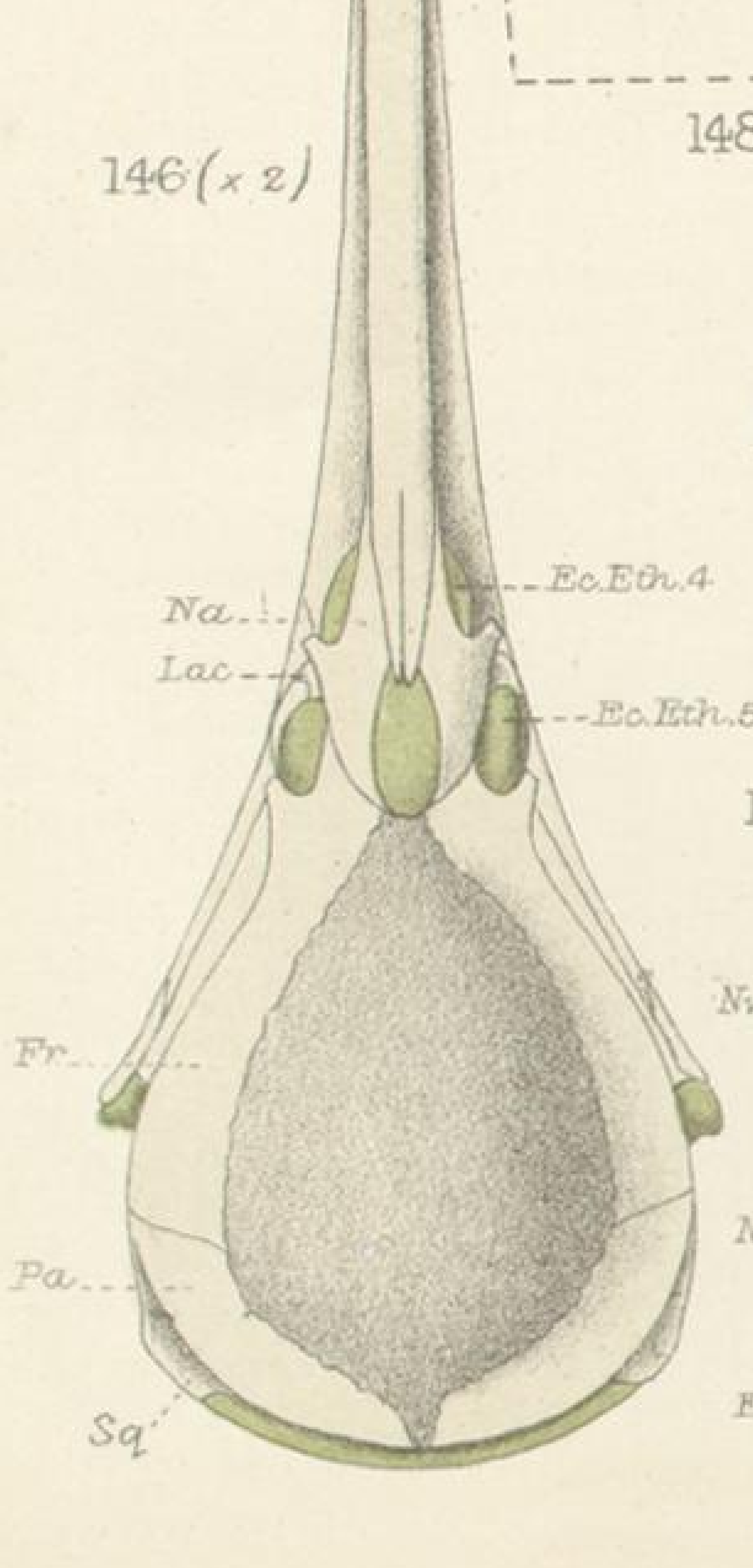

148 (× 2)

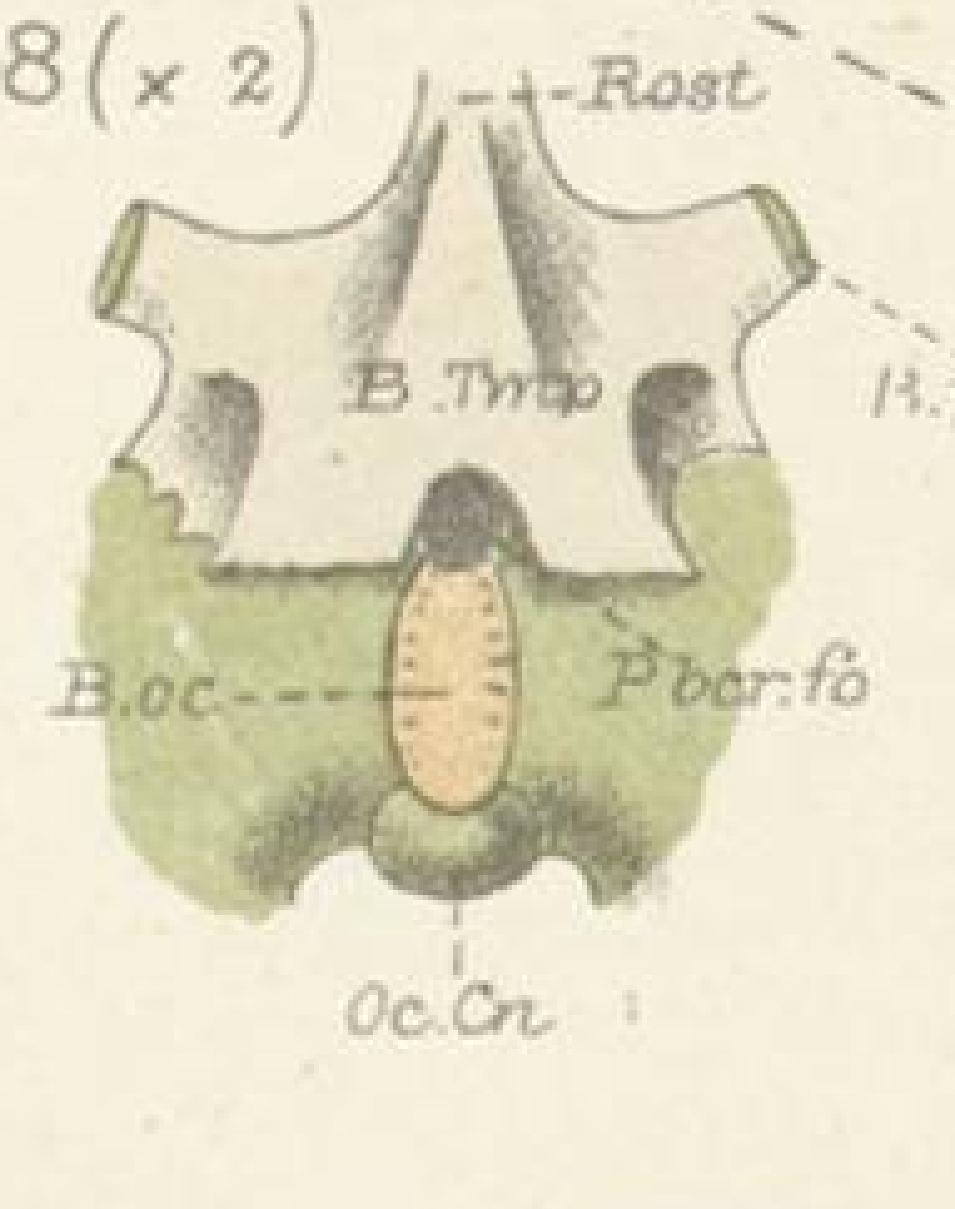

147 (× 2)

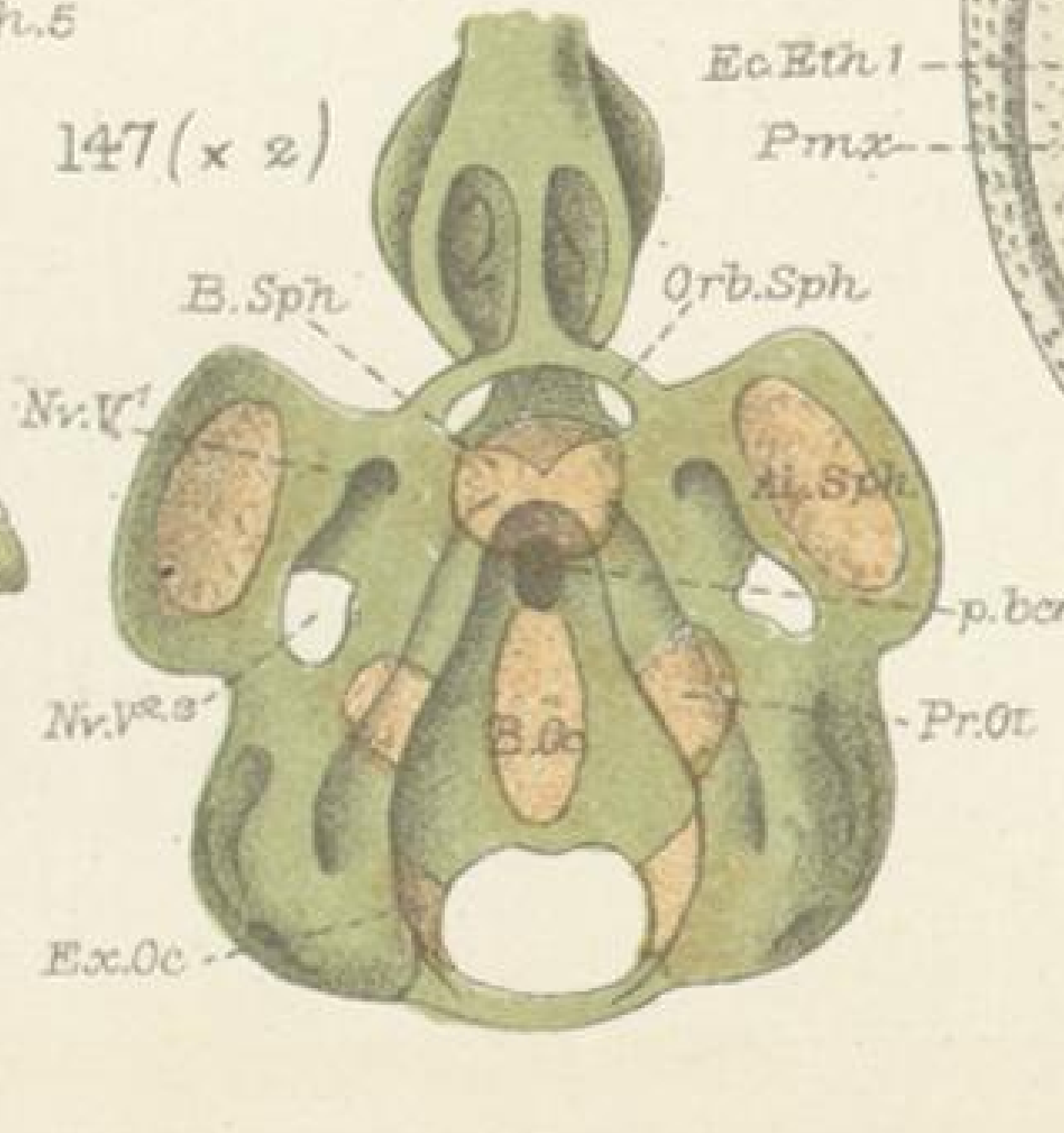

149 (× 22)

150 (× 22)

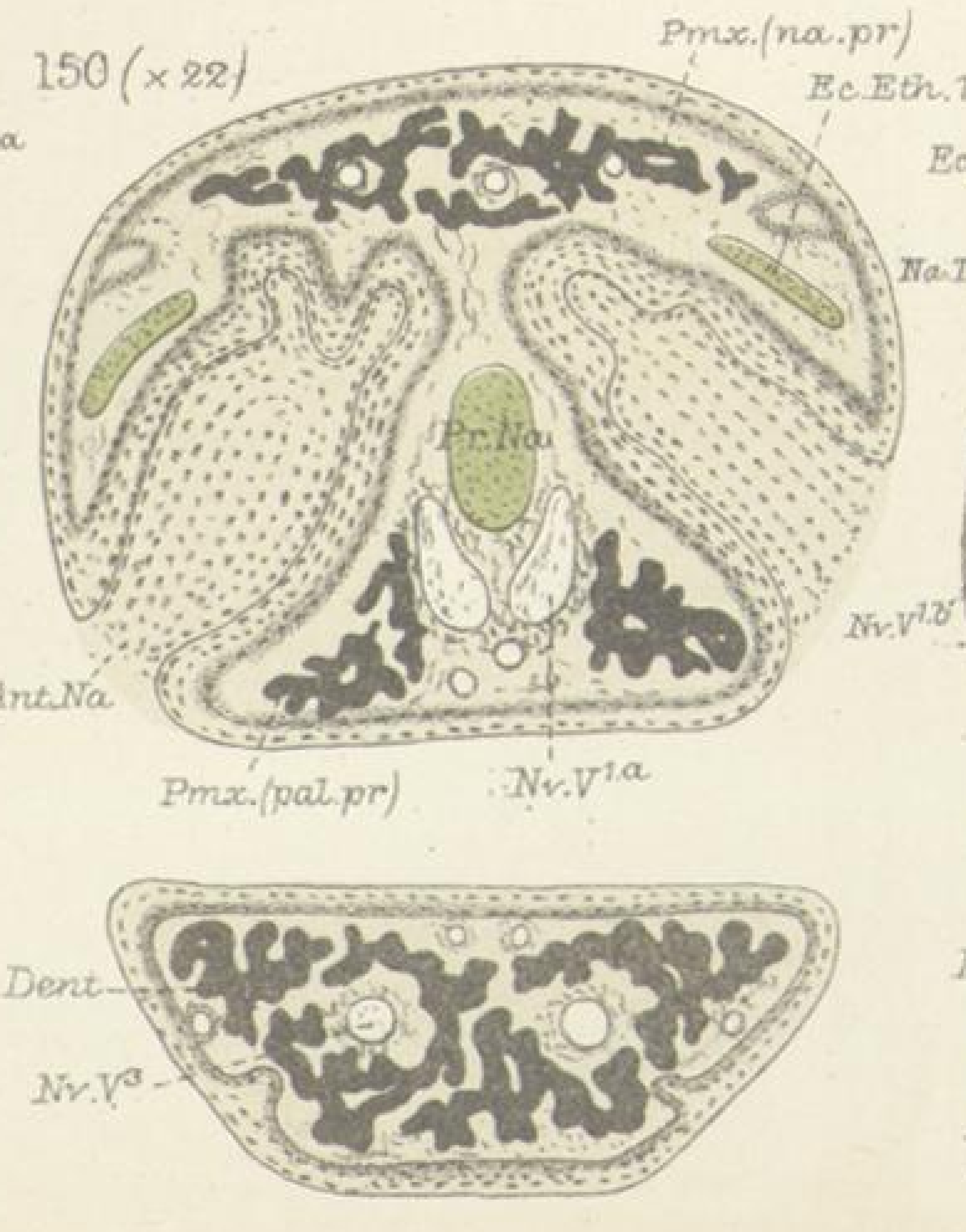

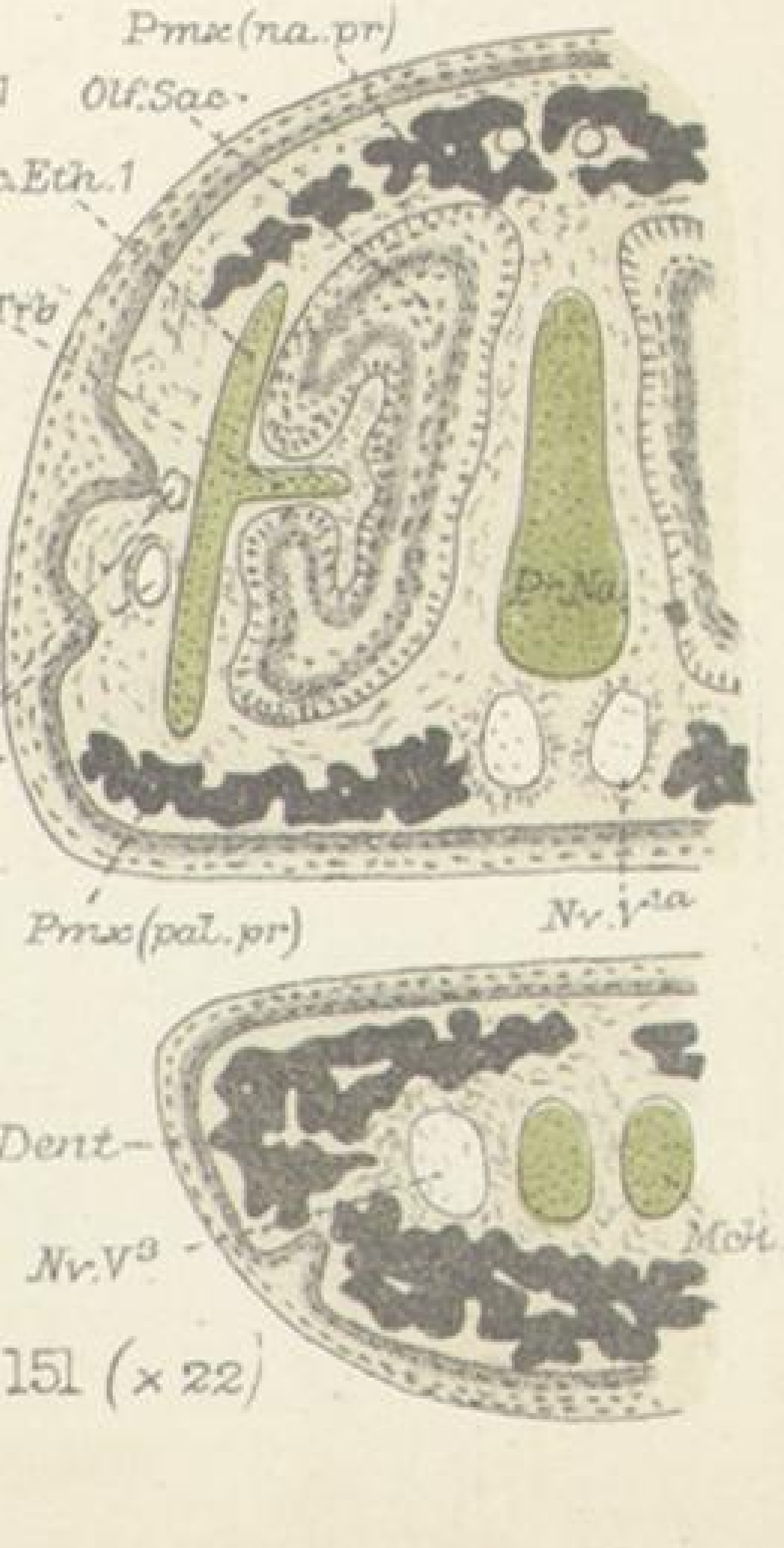

151 (× 22)

APTERYX. Skull: Stages G and H.

152 (×22)

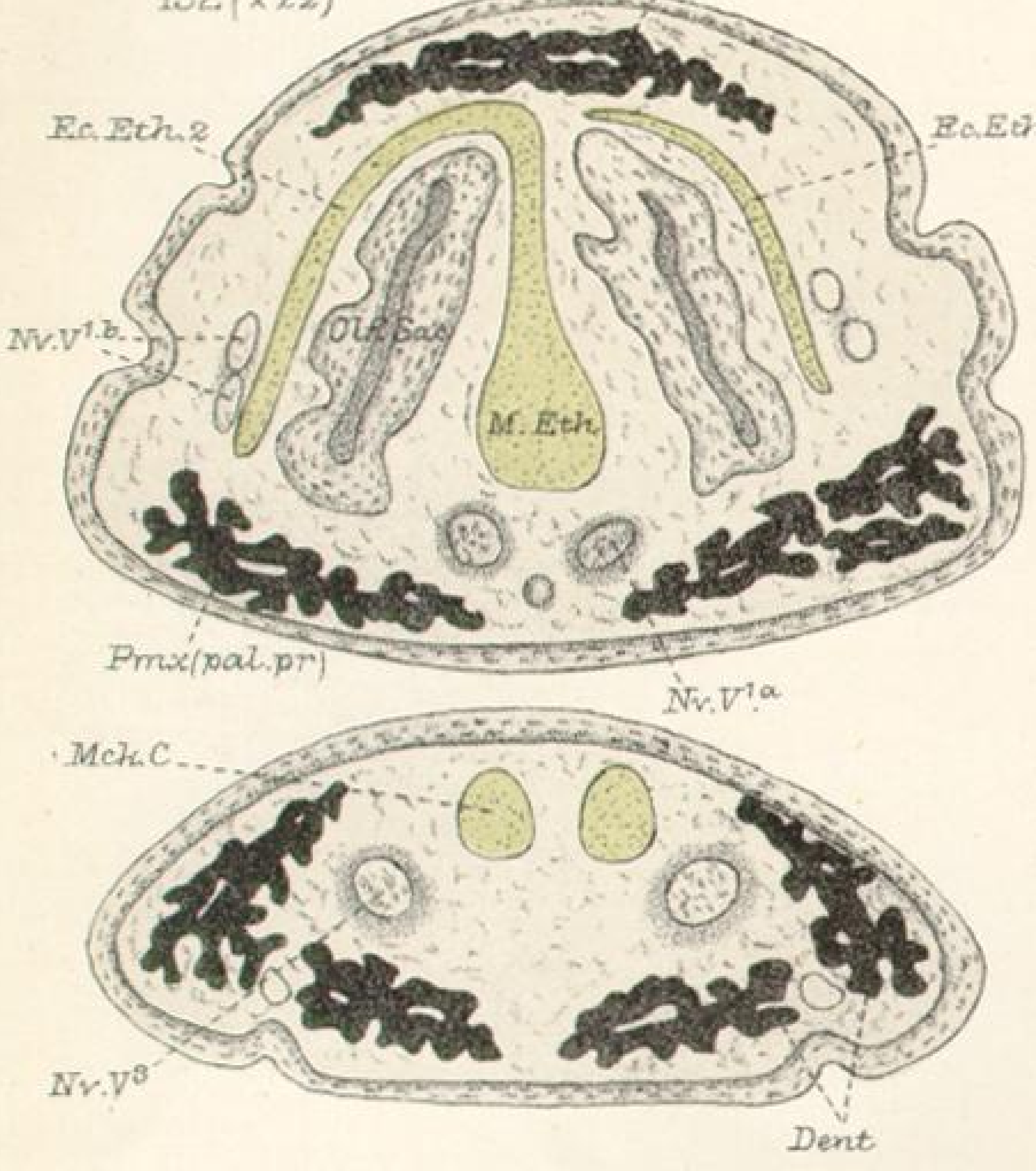

153 (×9)

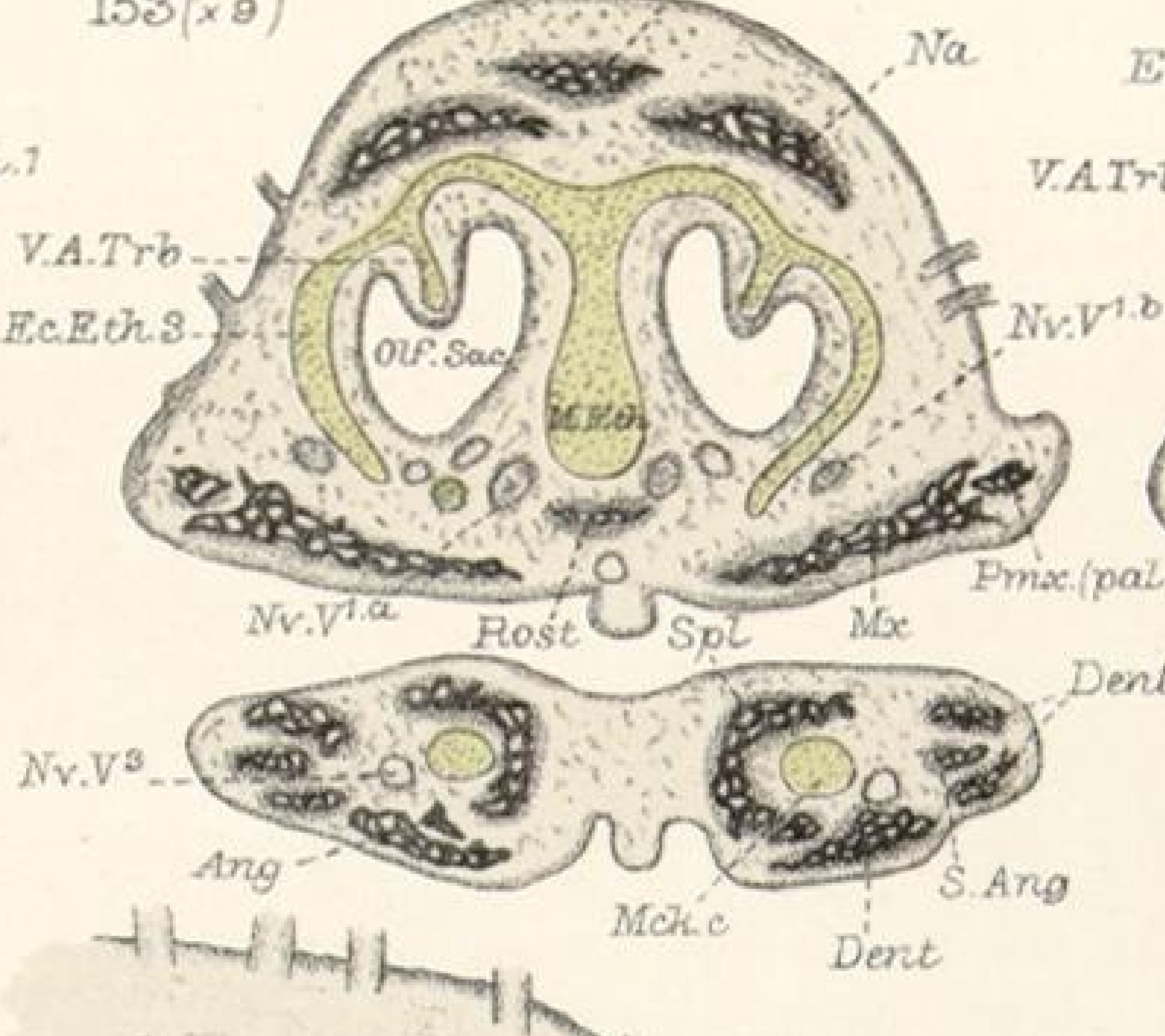

154 (×9)

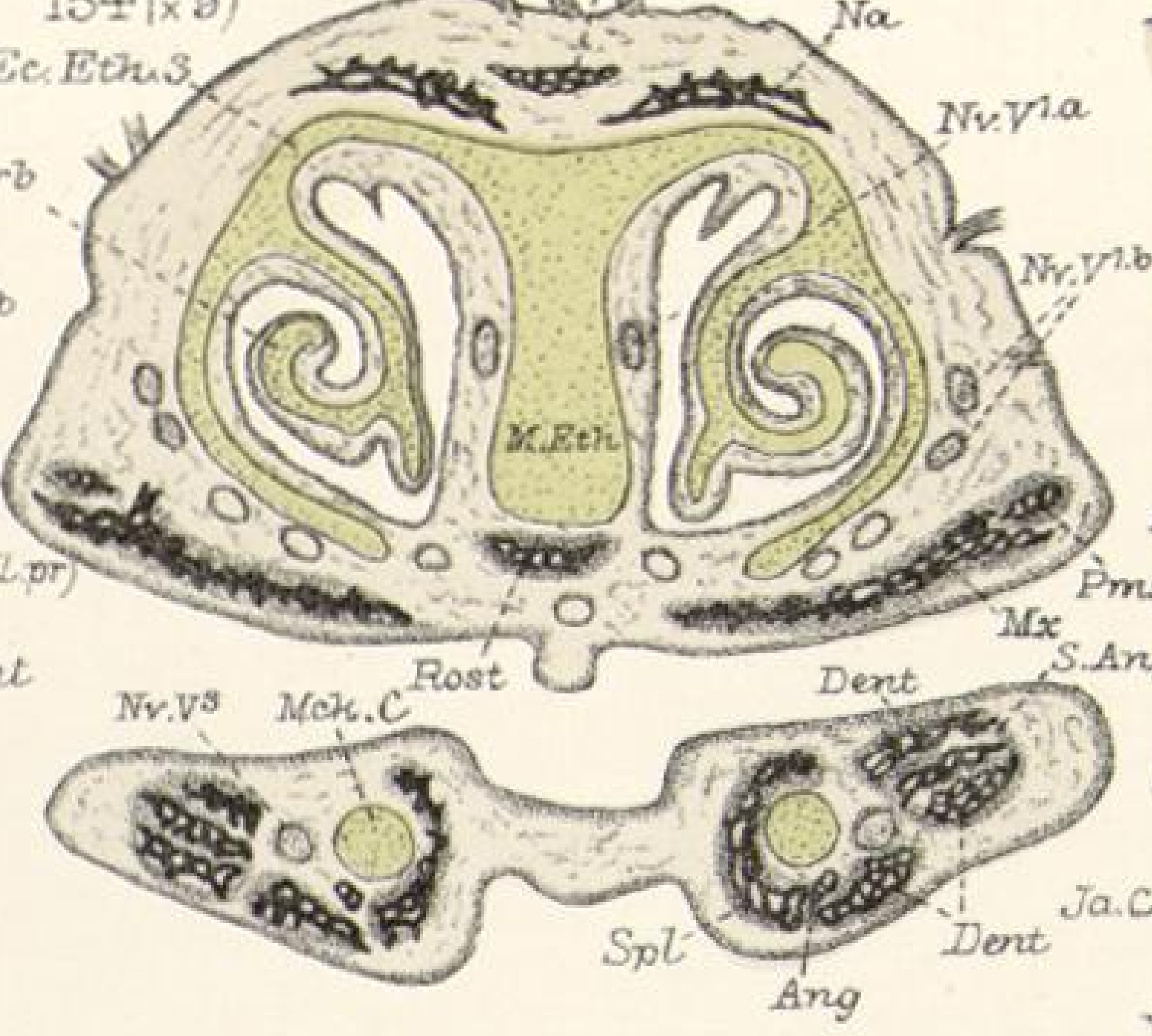

155 (×9)

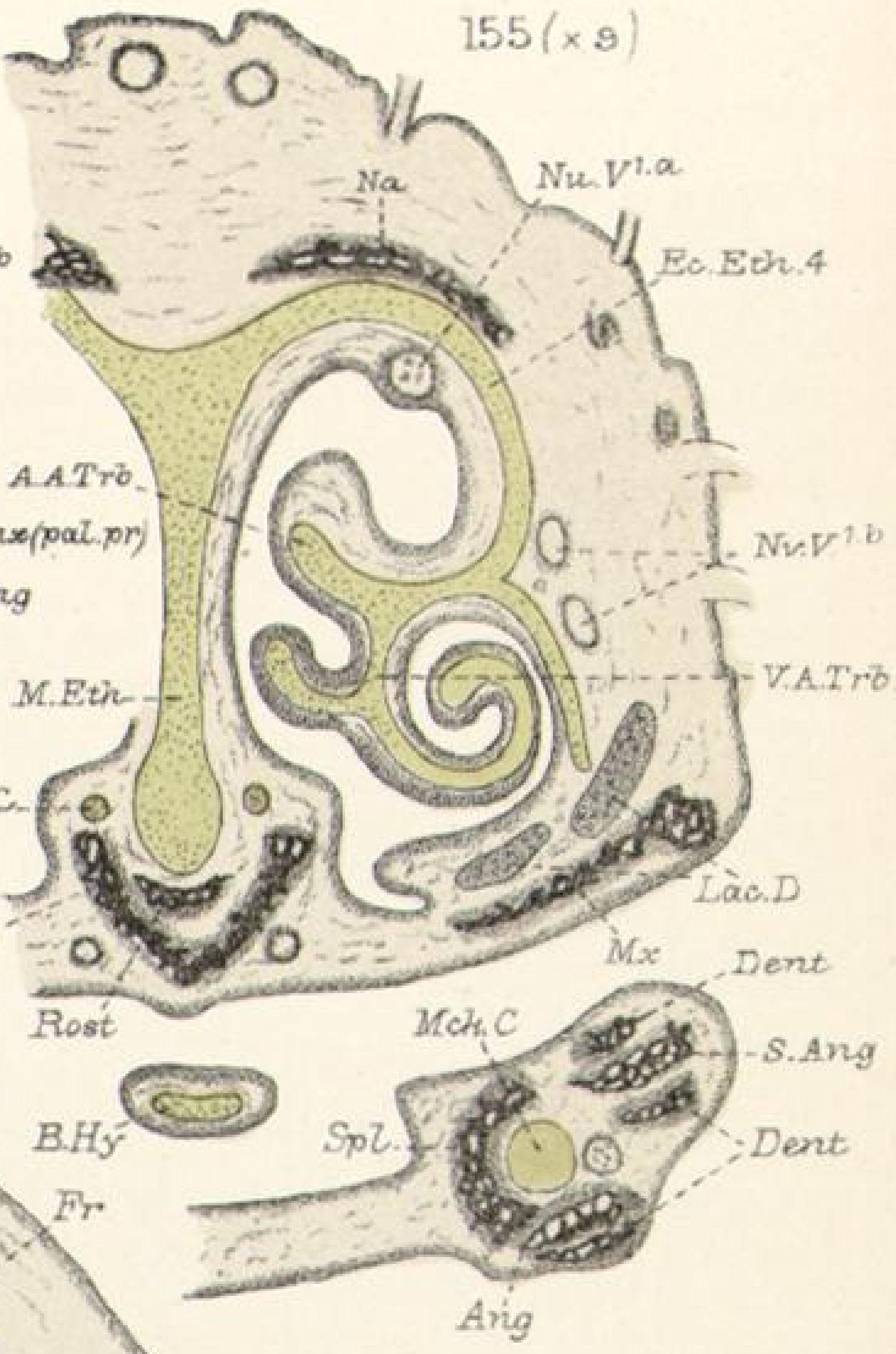

156 (×9)

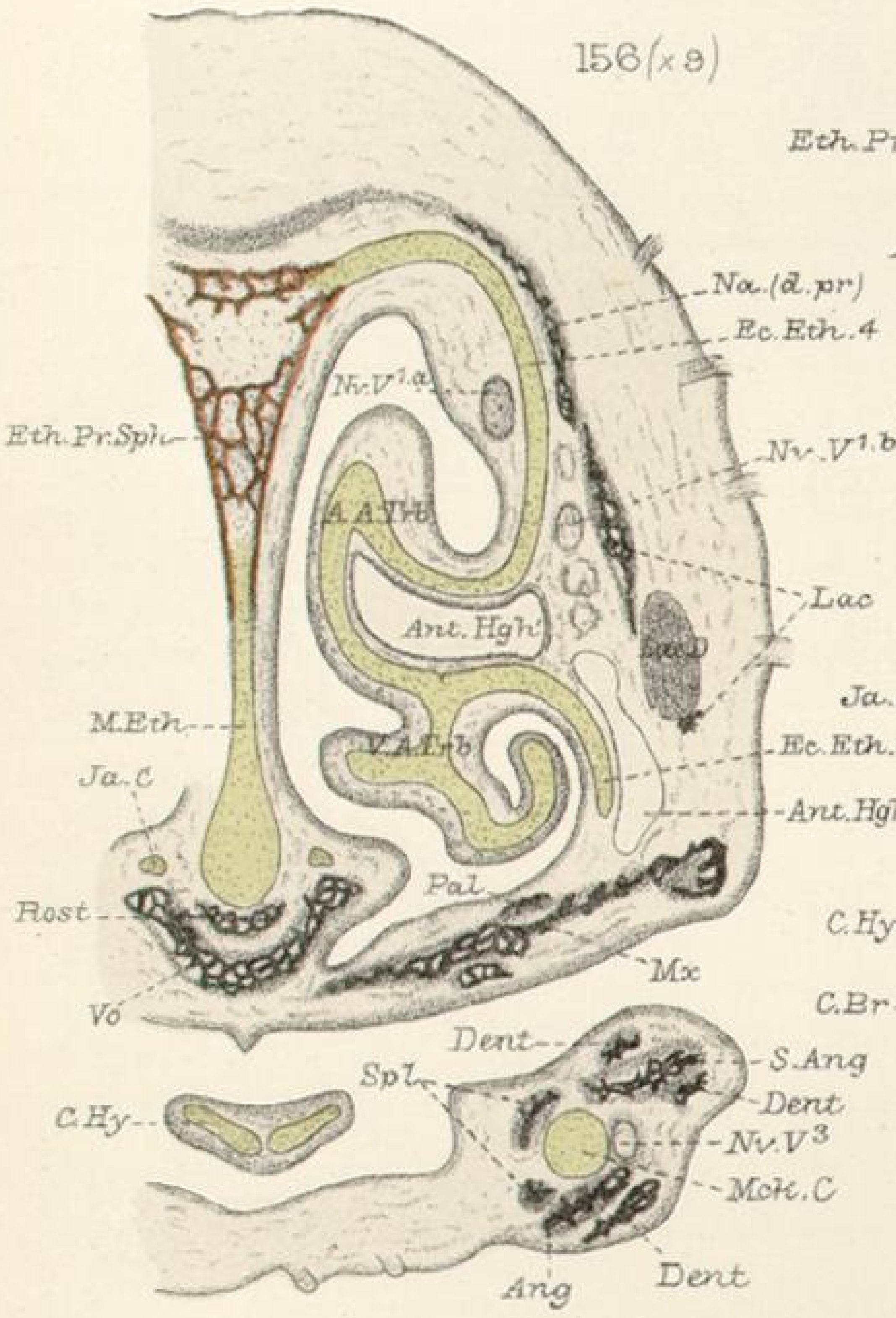

157 (×9)

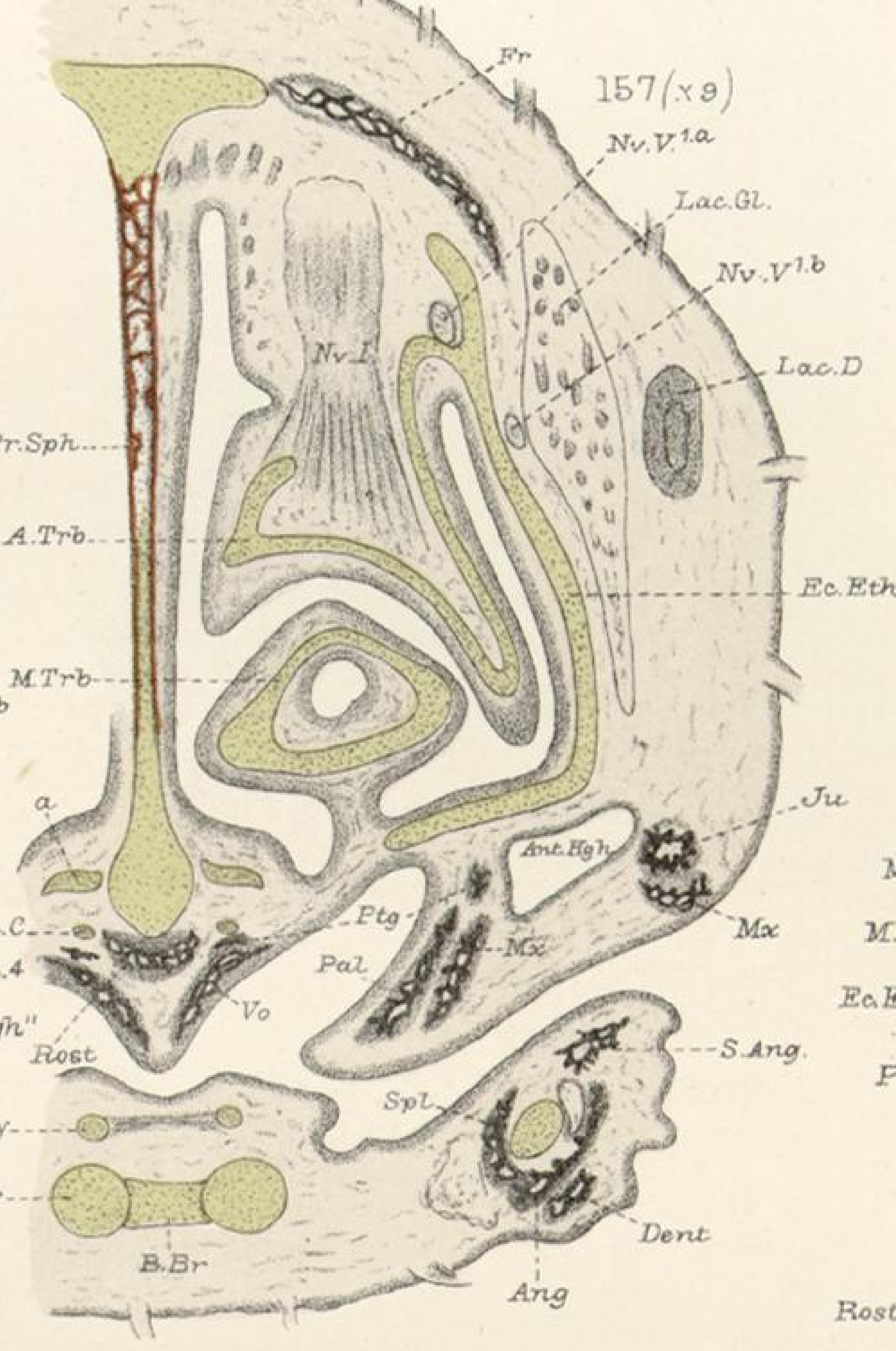

158 (×9)

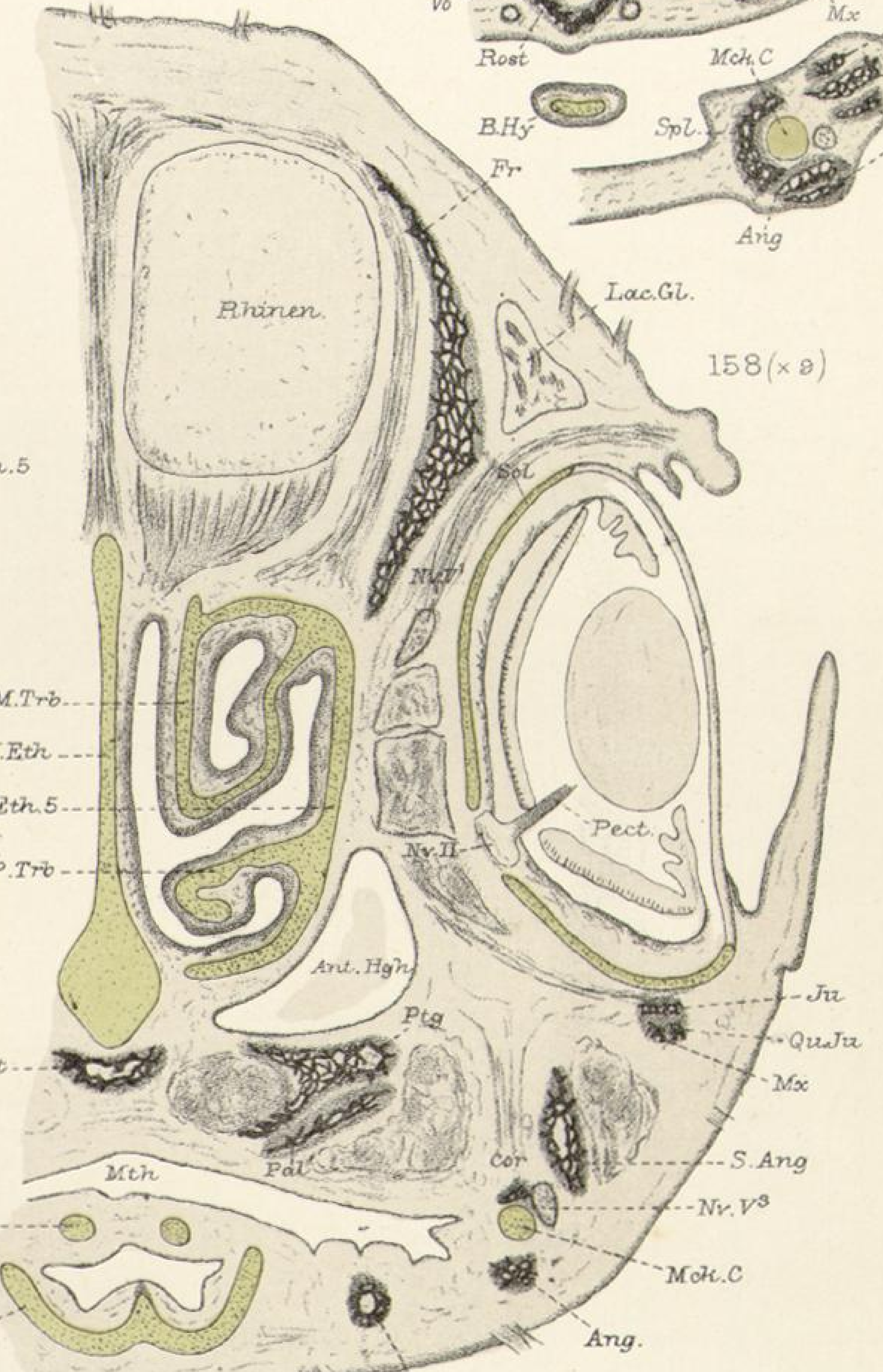

160 (×9)

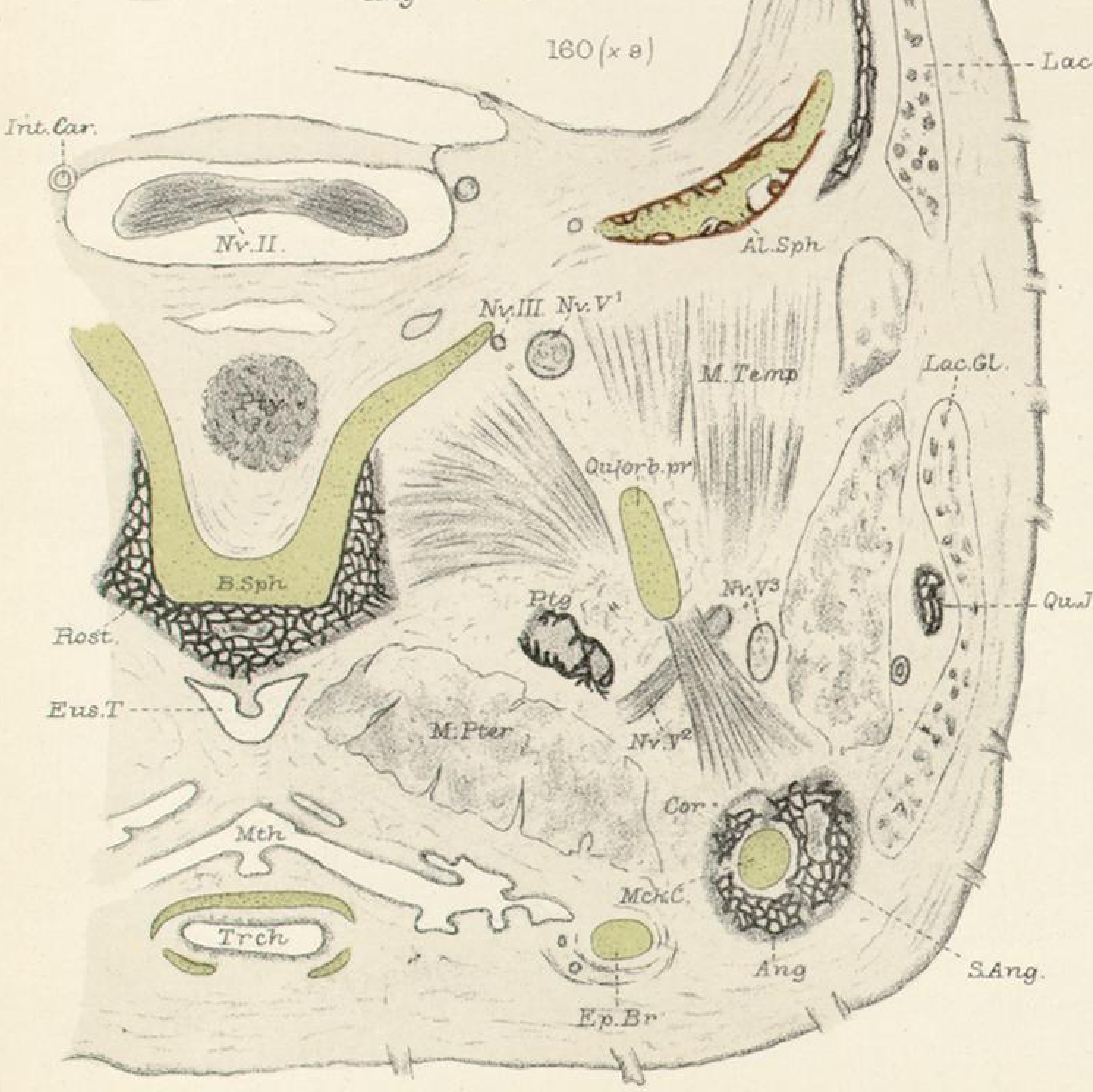

159 (×9)

161 (×9)

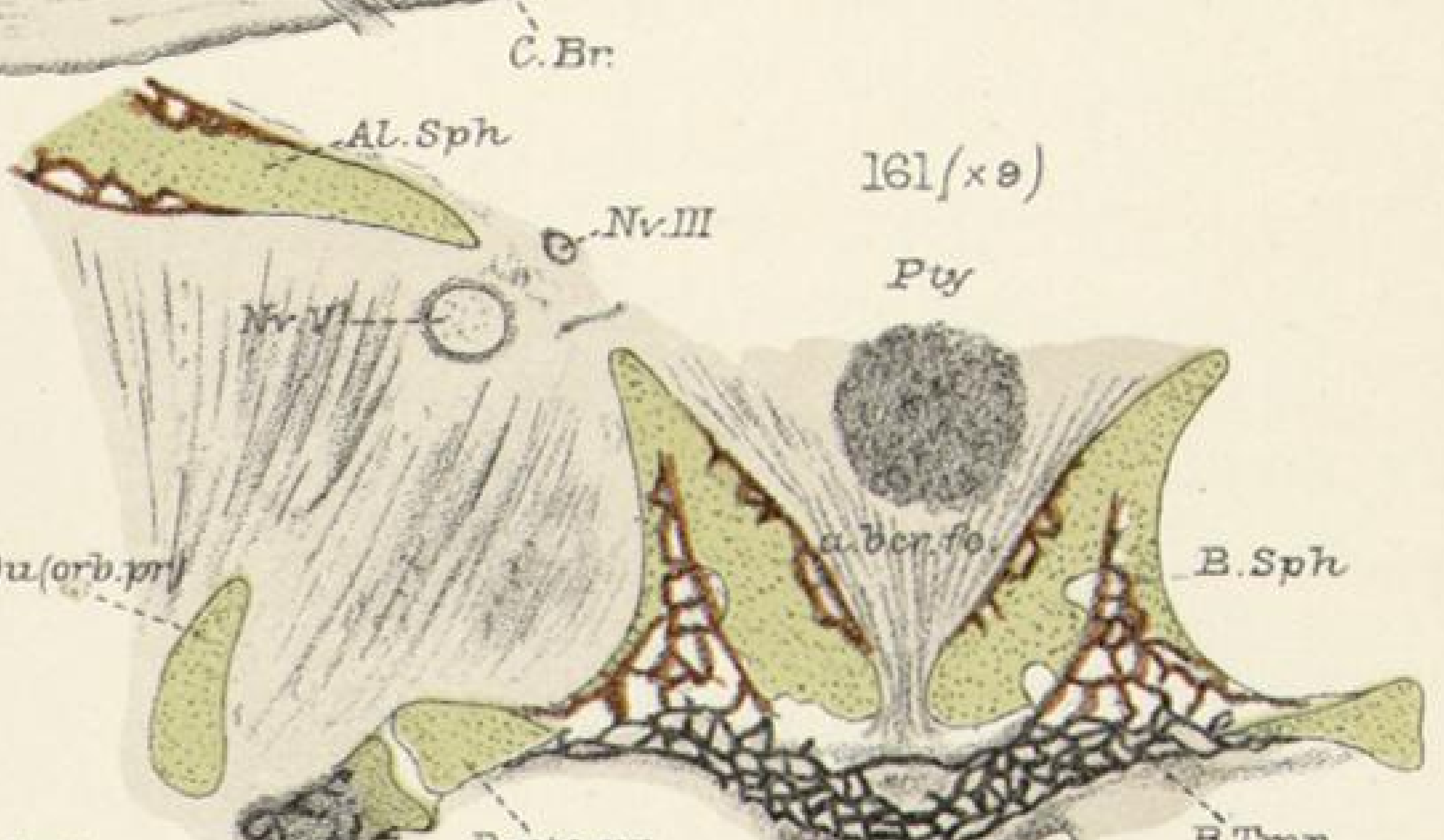

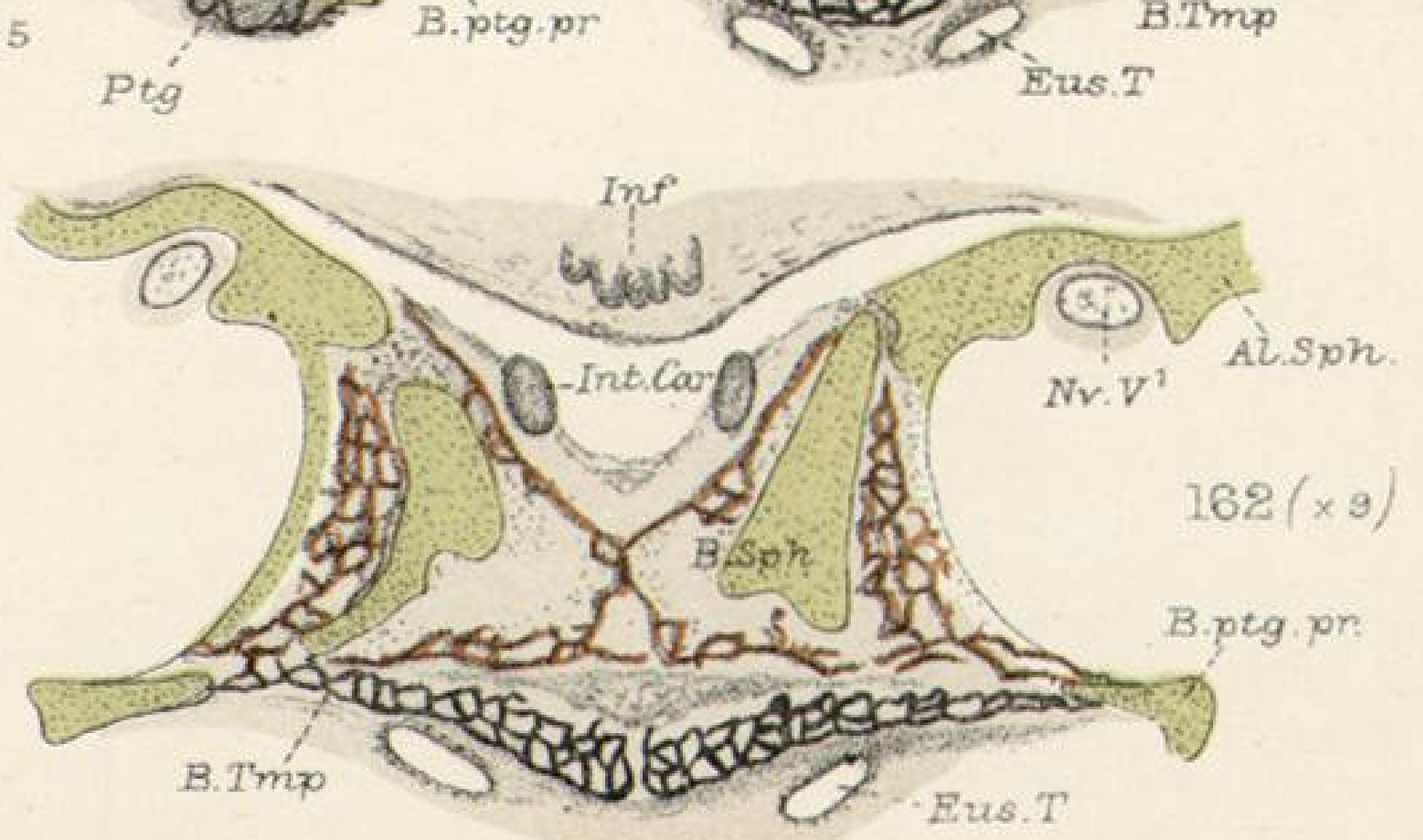

162 (×9)

APTERYX. Skull: Stage H.

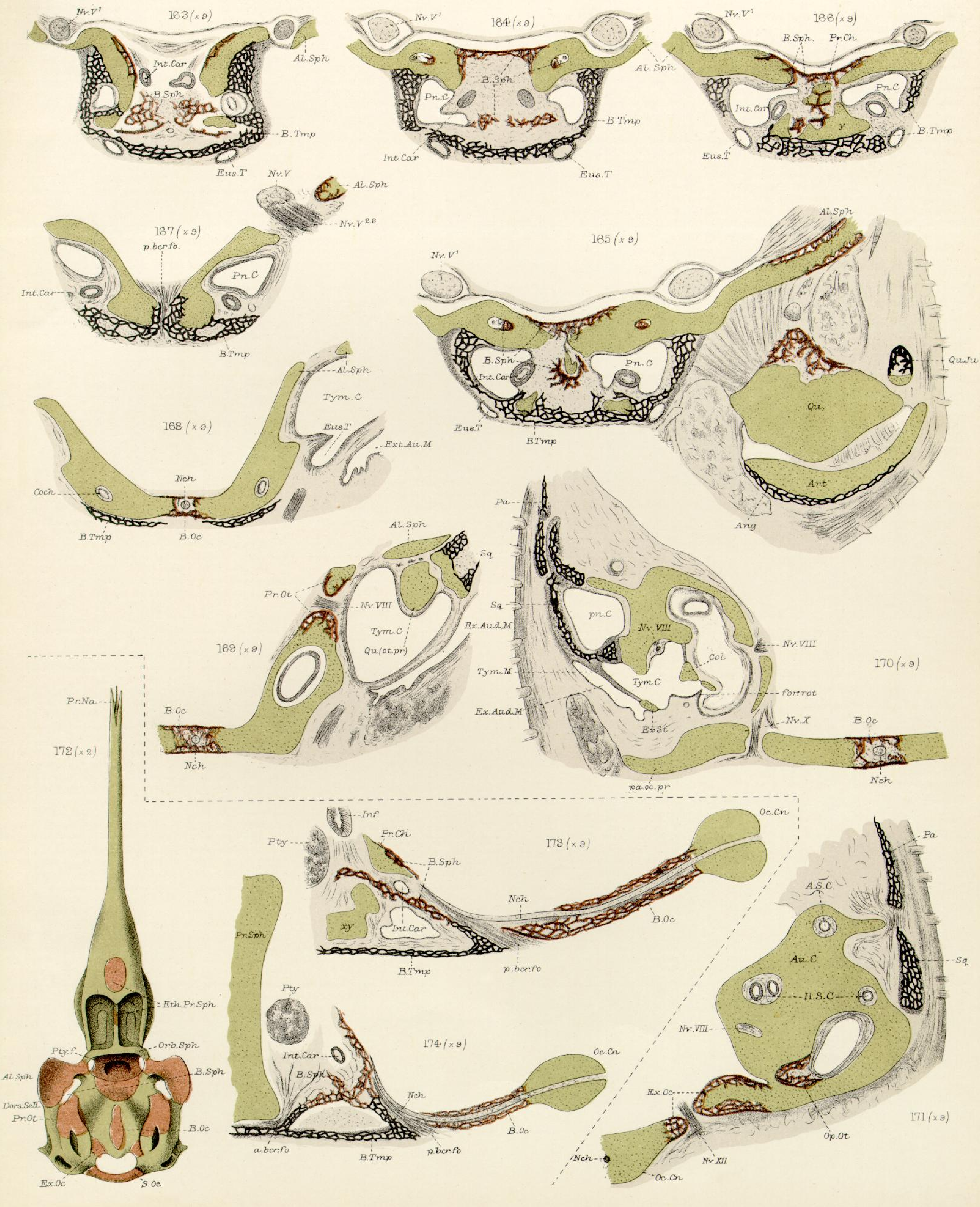

APTERYX . Skull : Stages H and I.

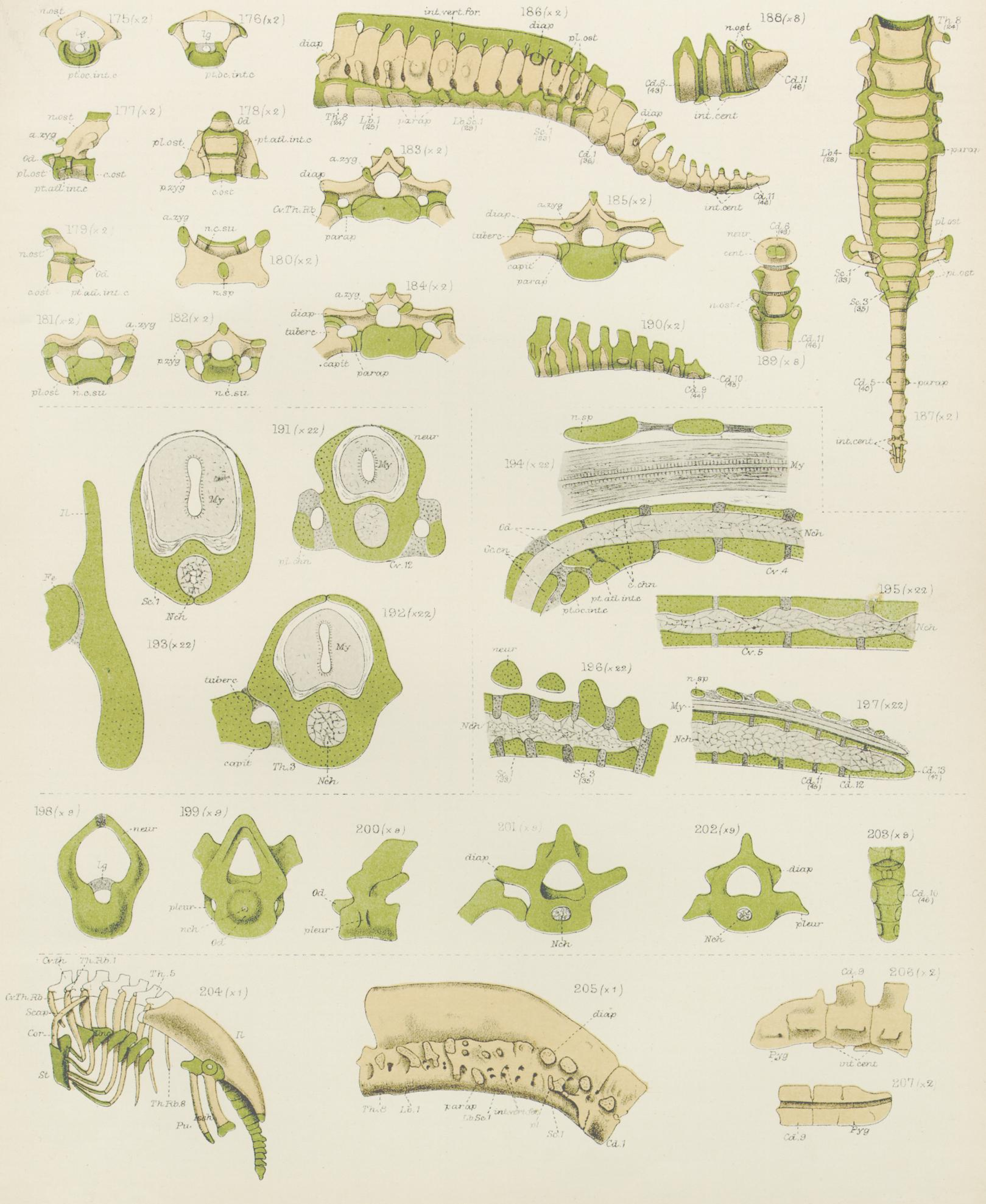

APTERYX. Vertebral column & ribs.

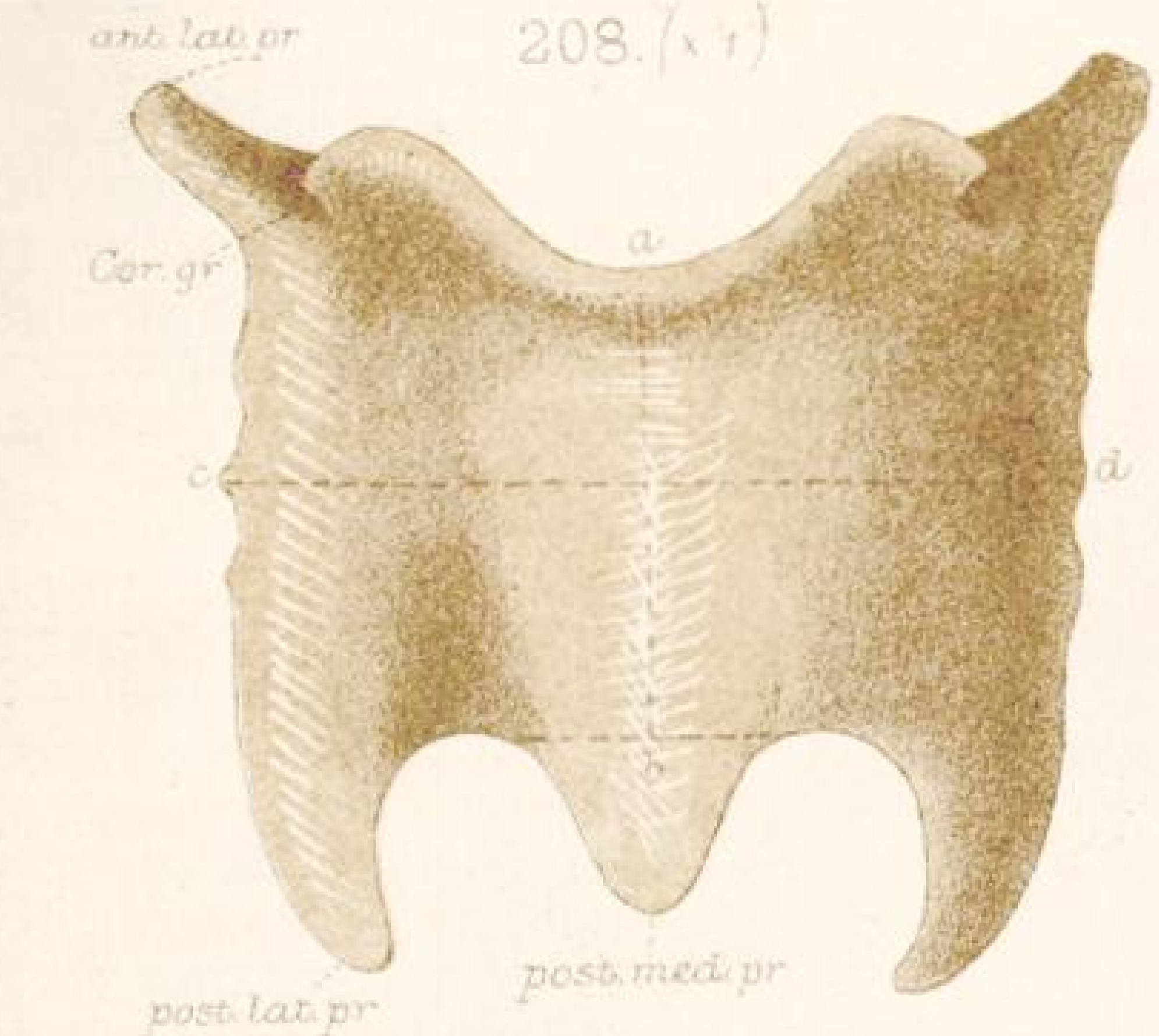

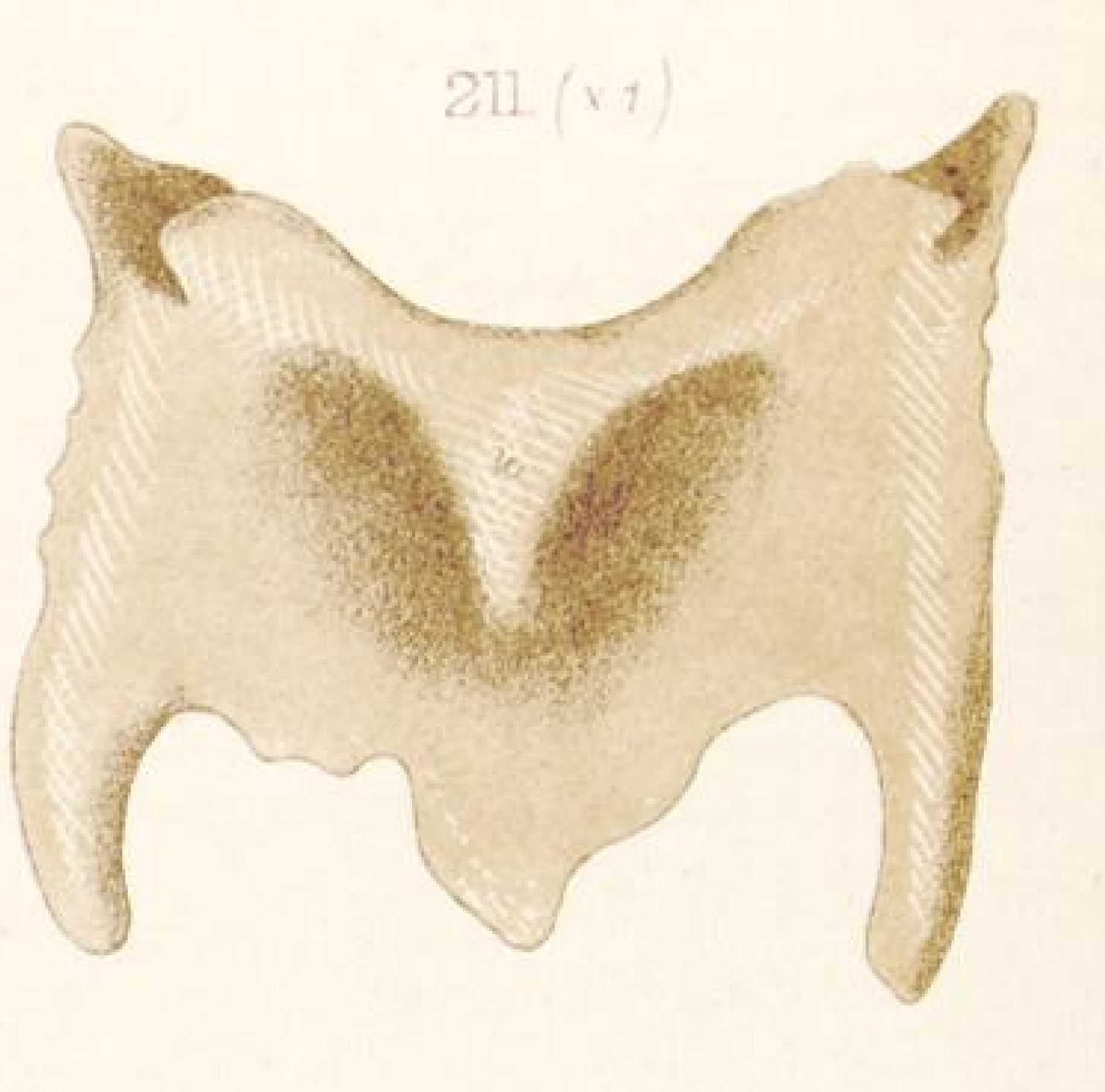

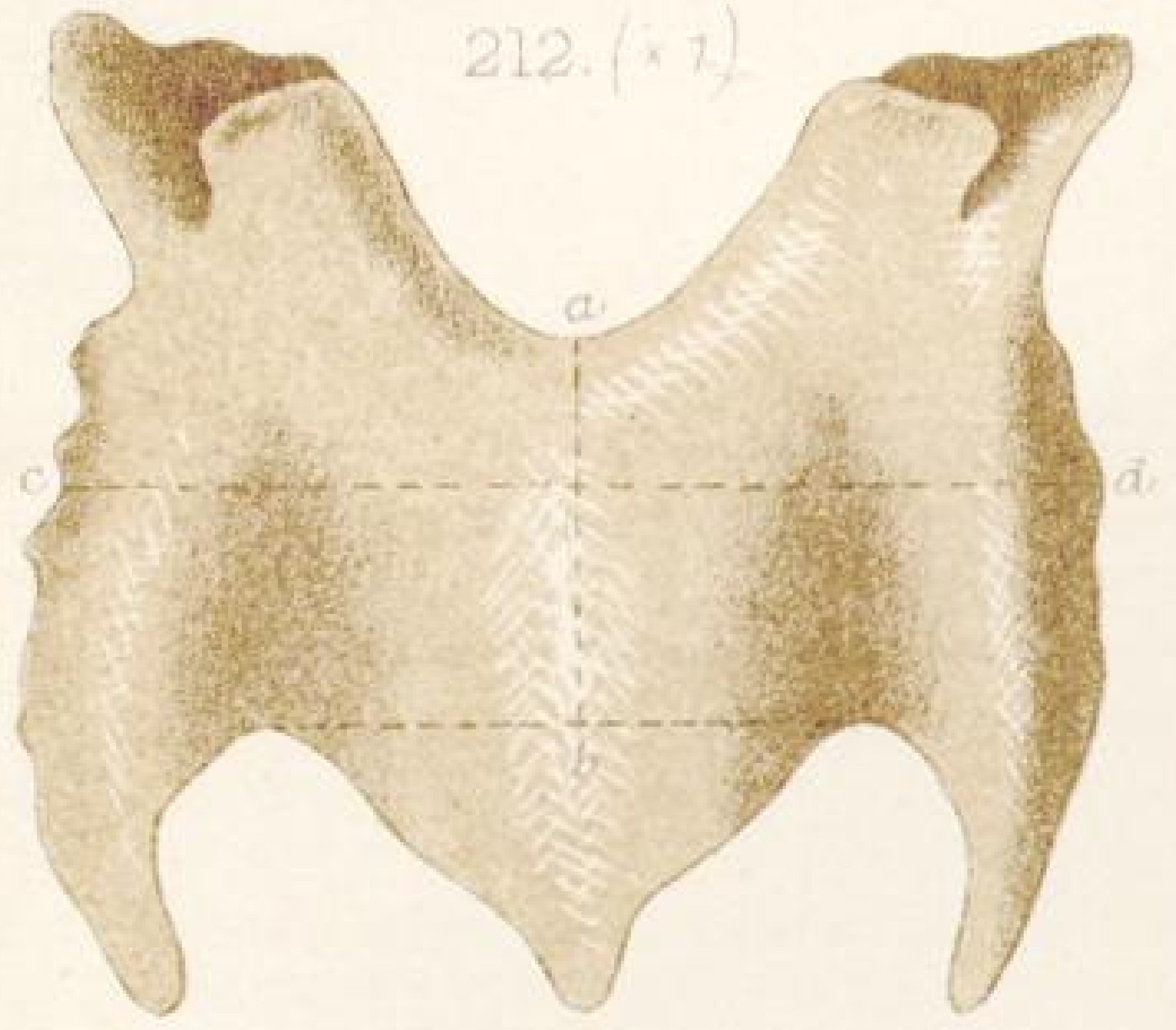

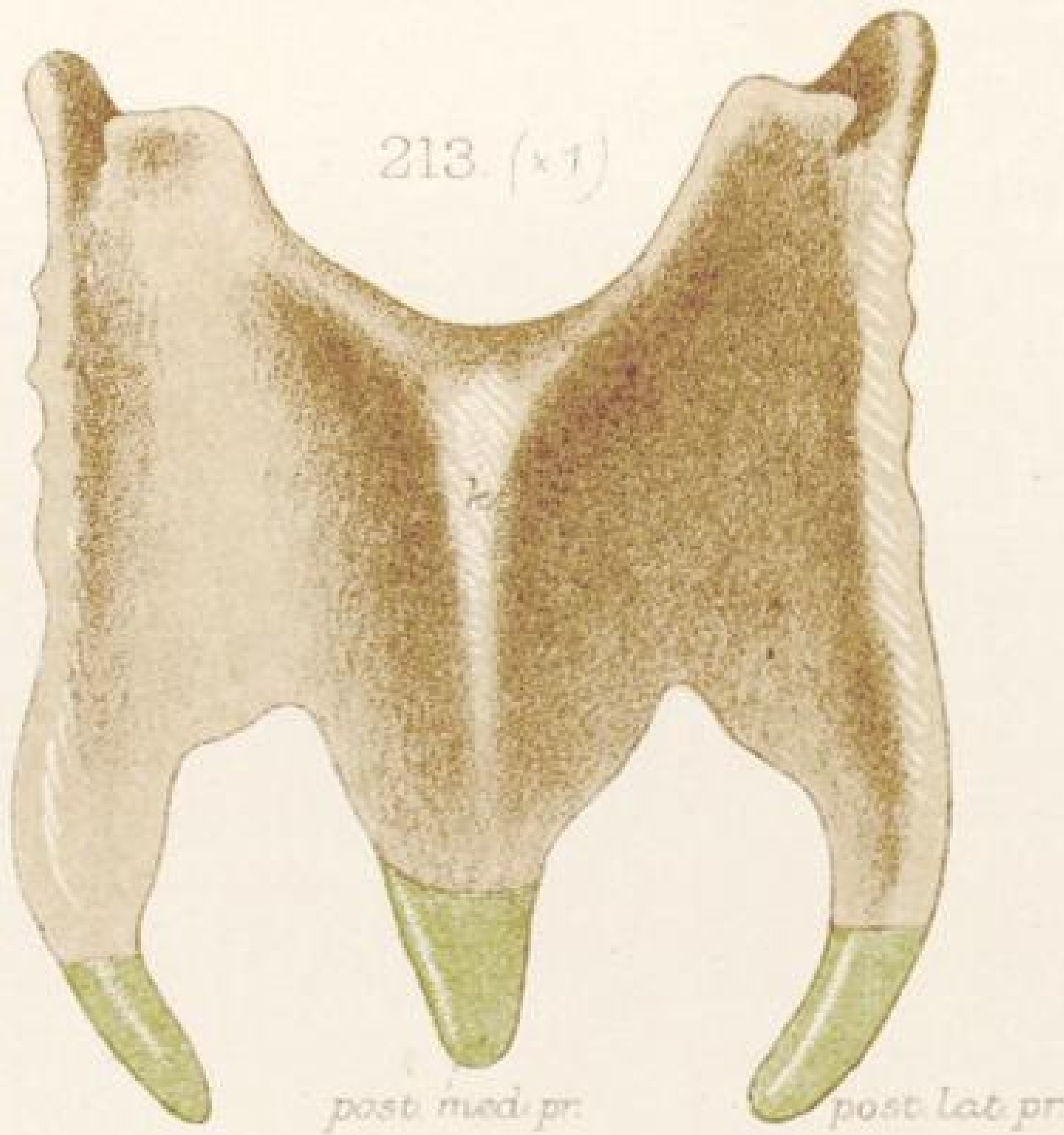

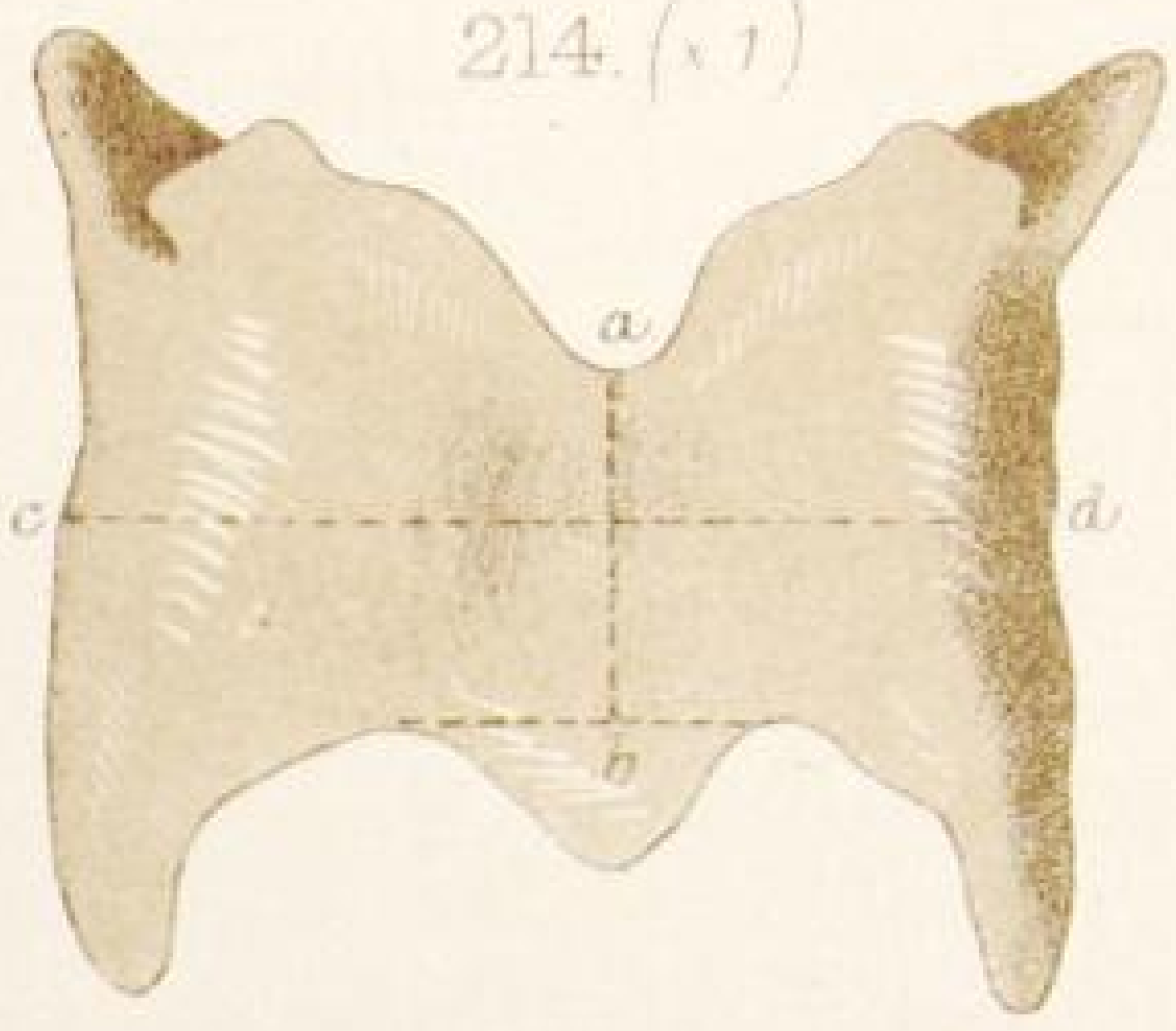

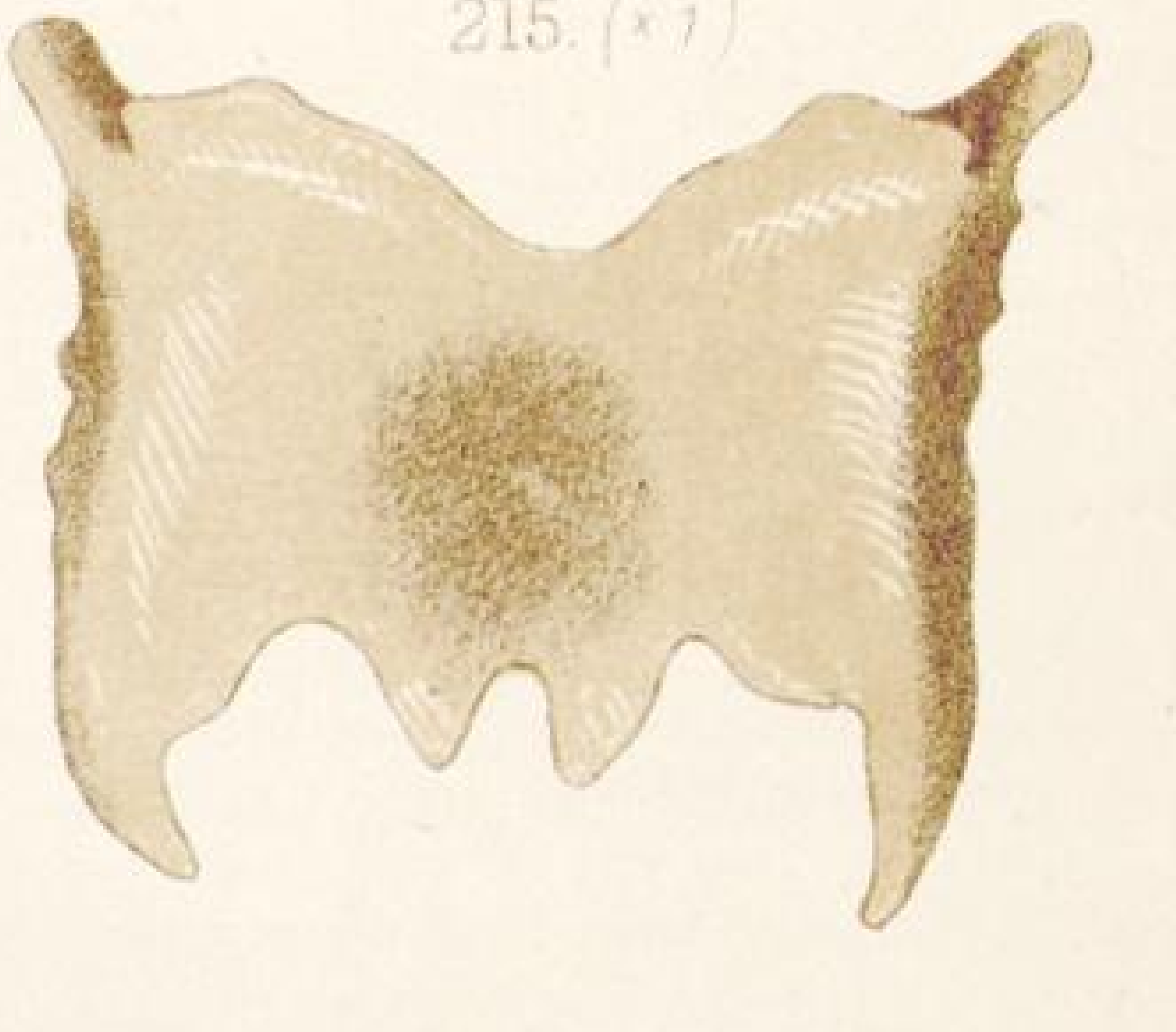

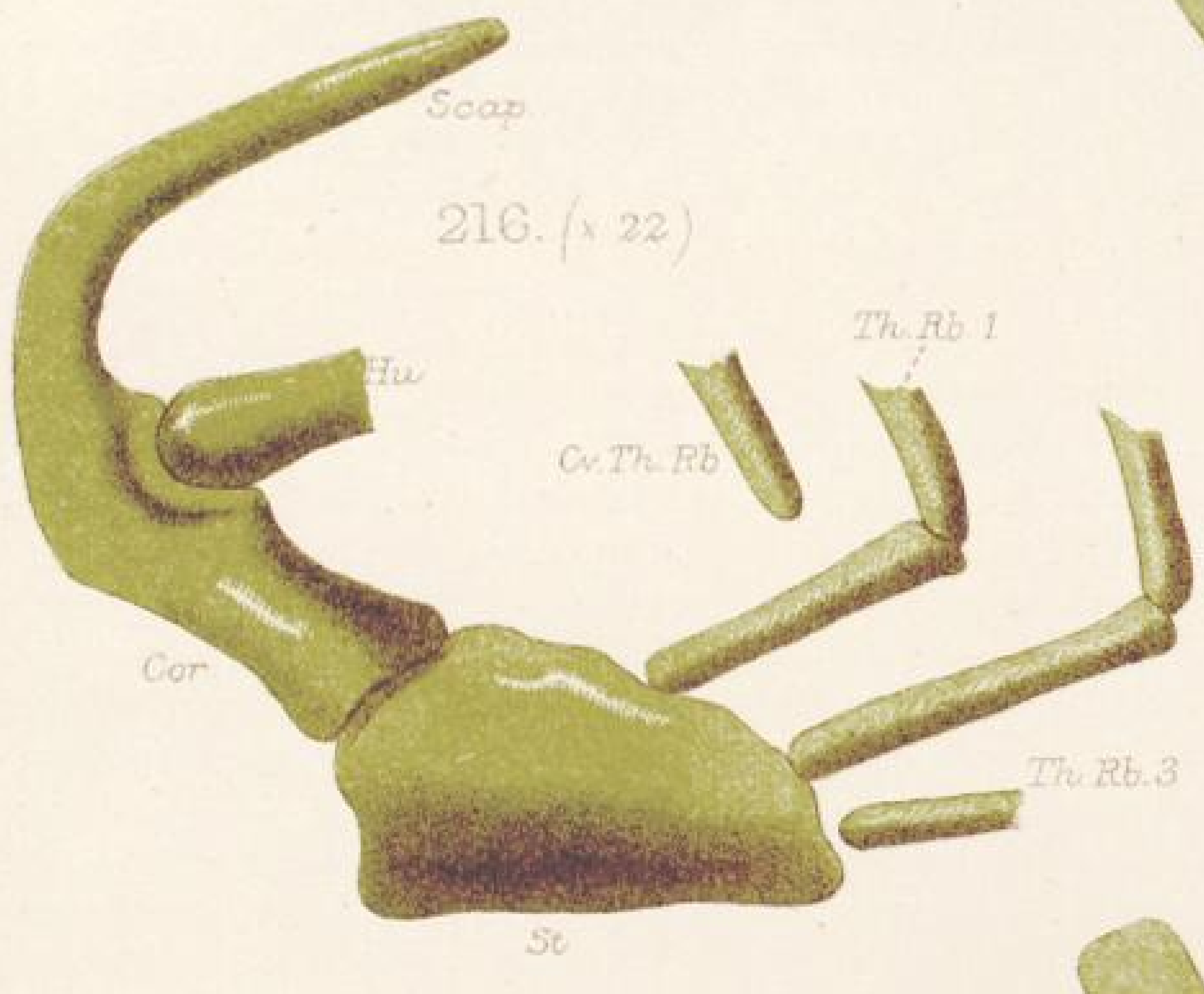

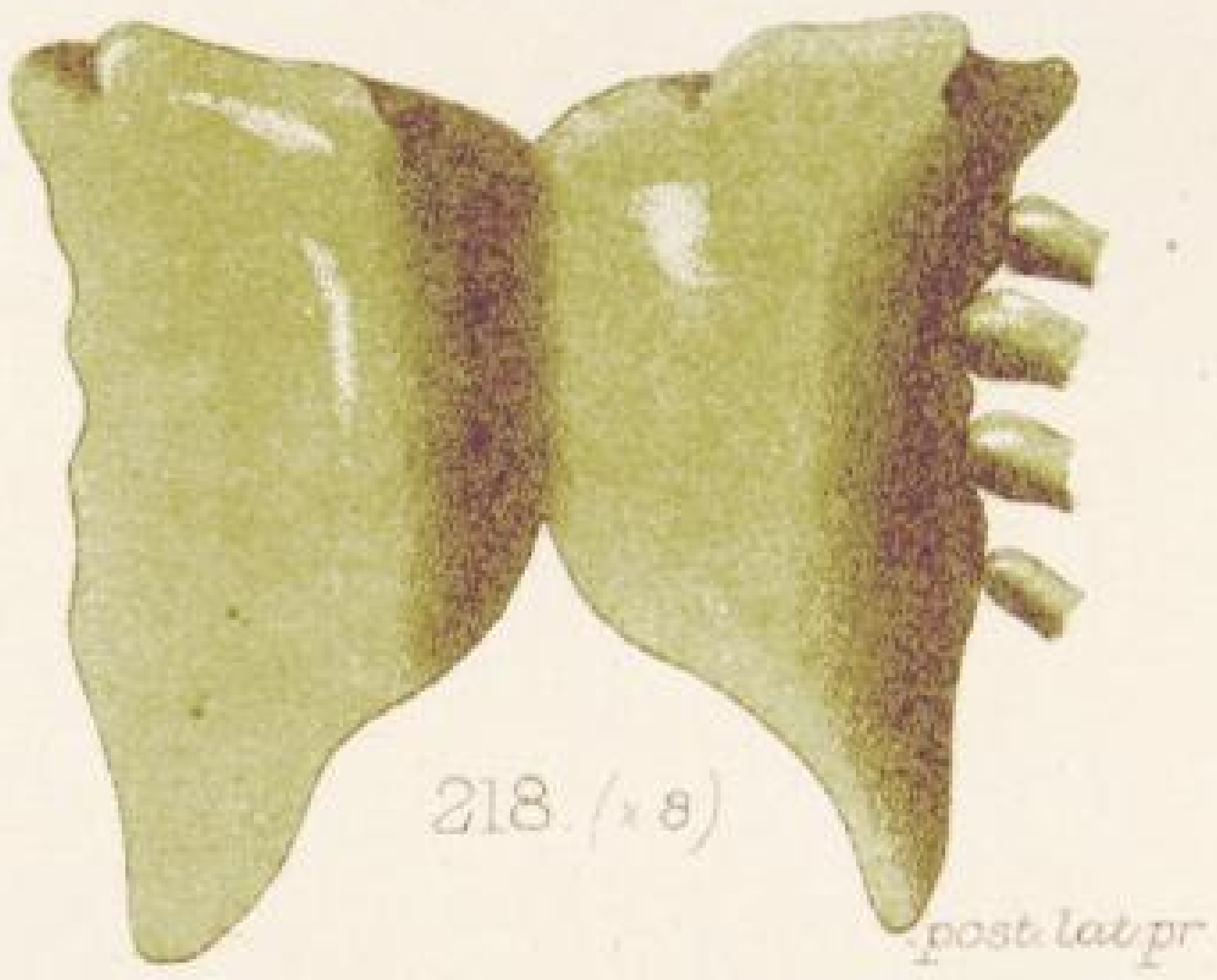



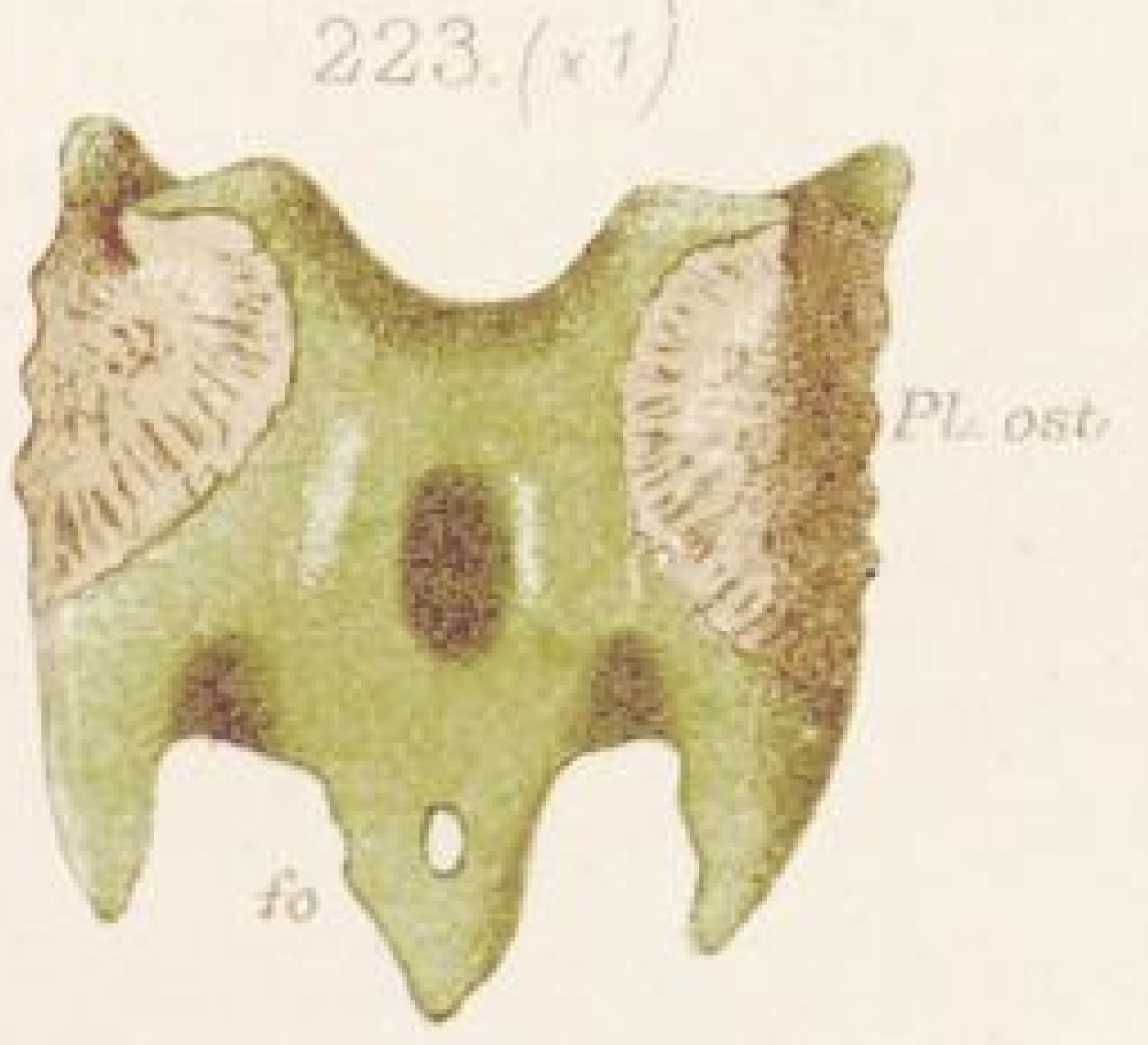

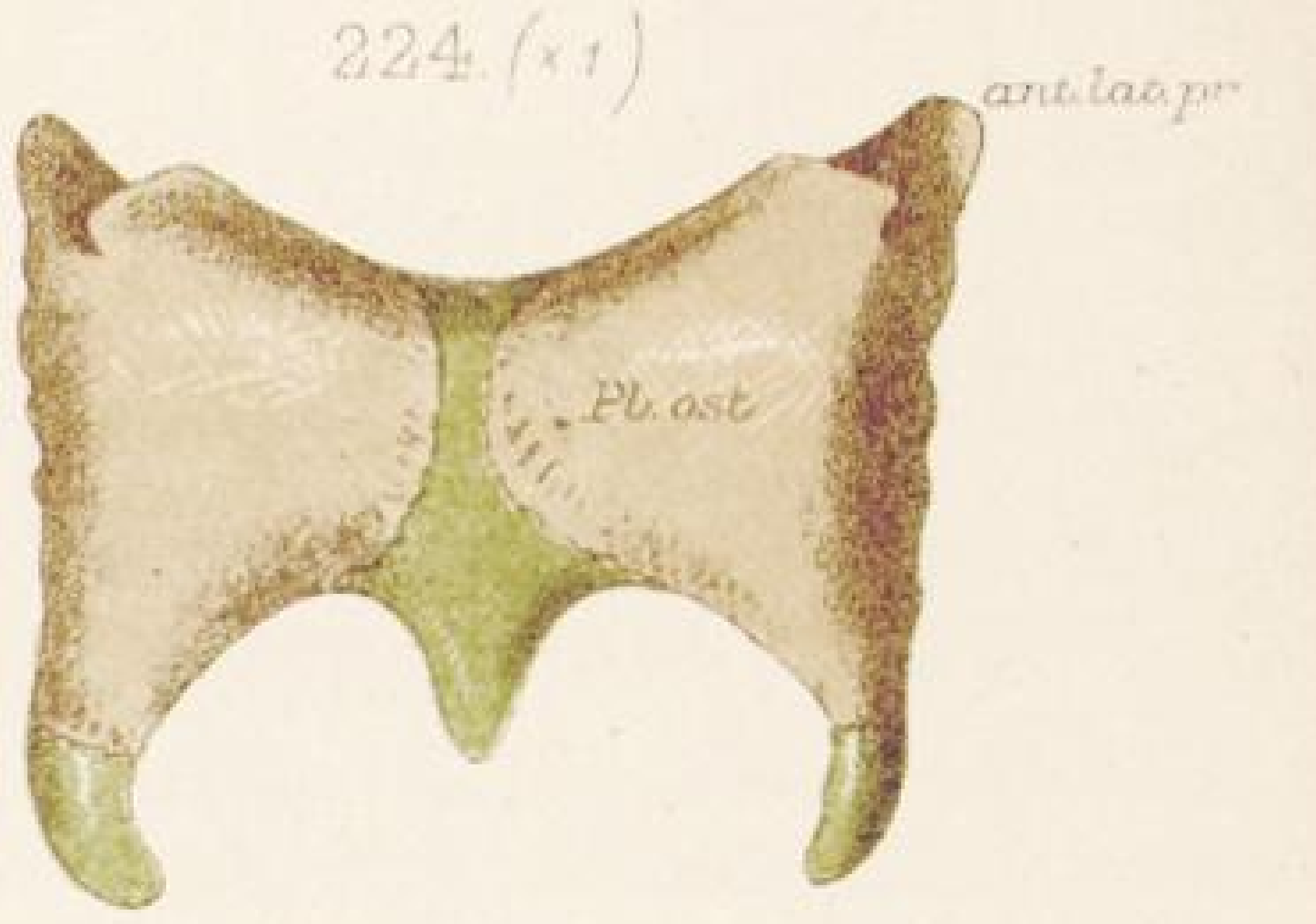

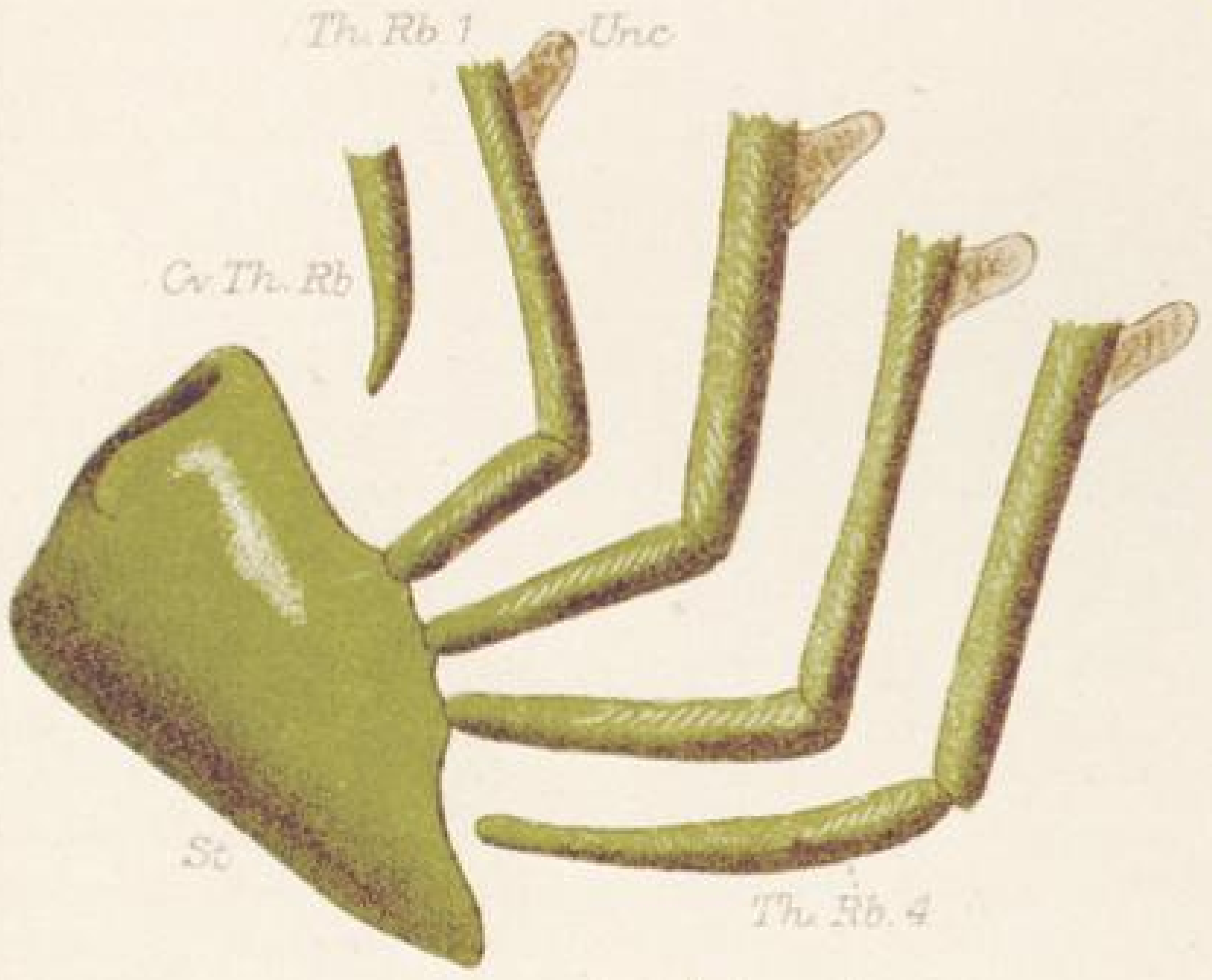

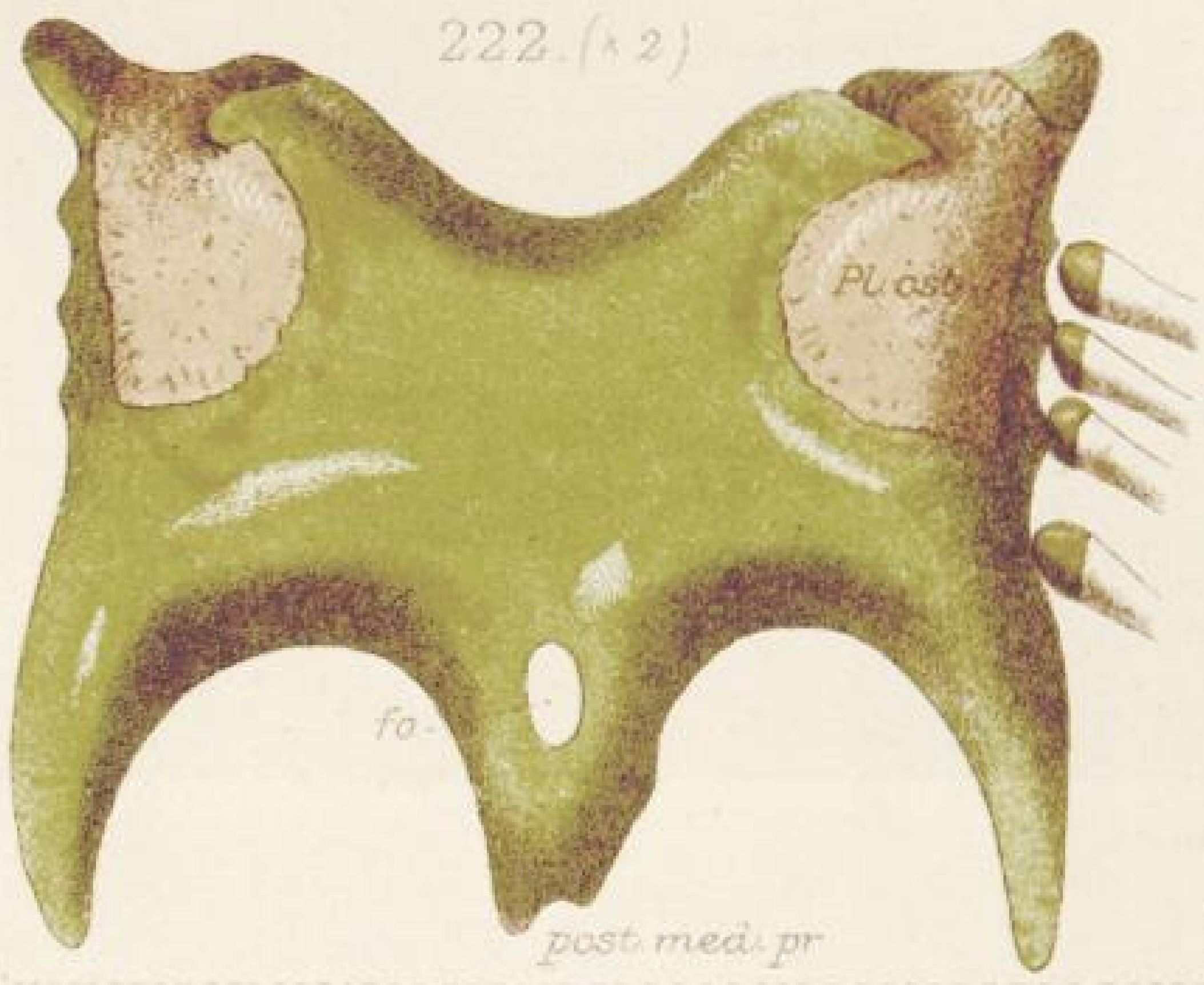

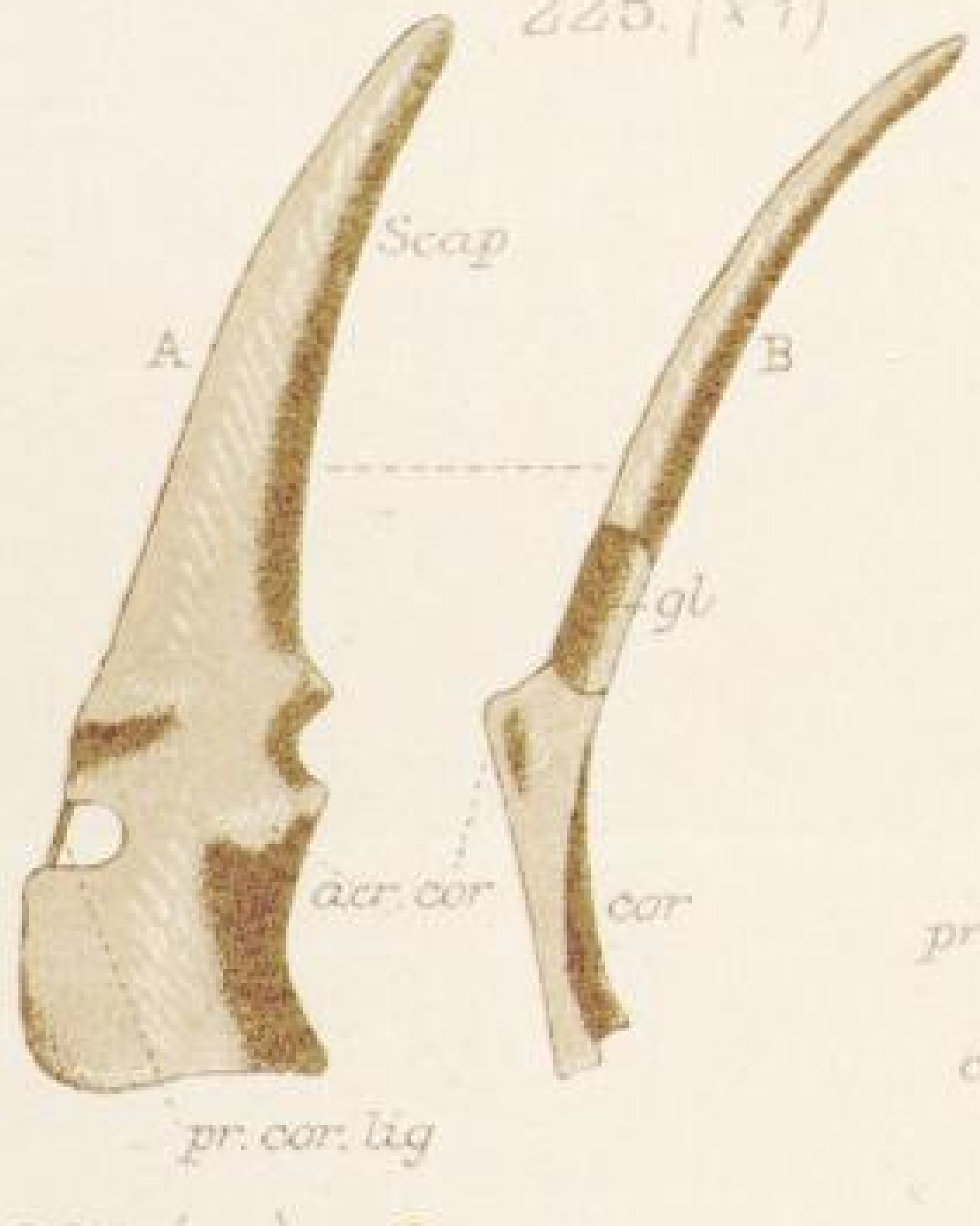

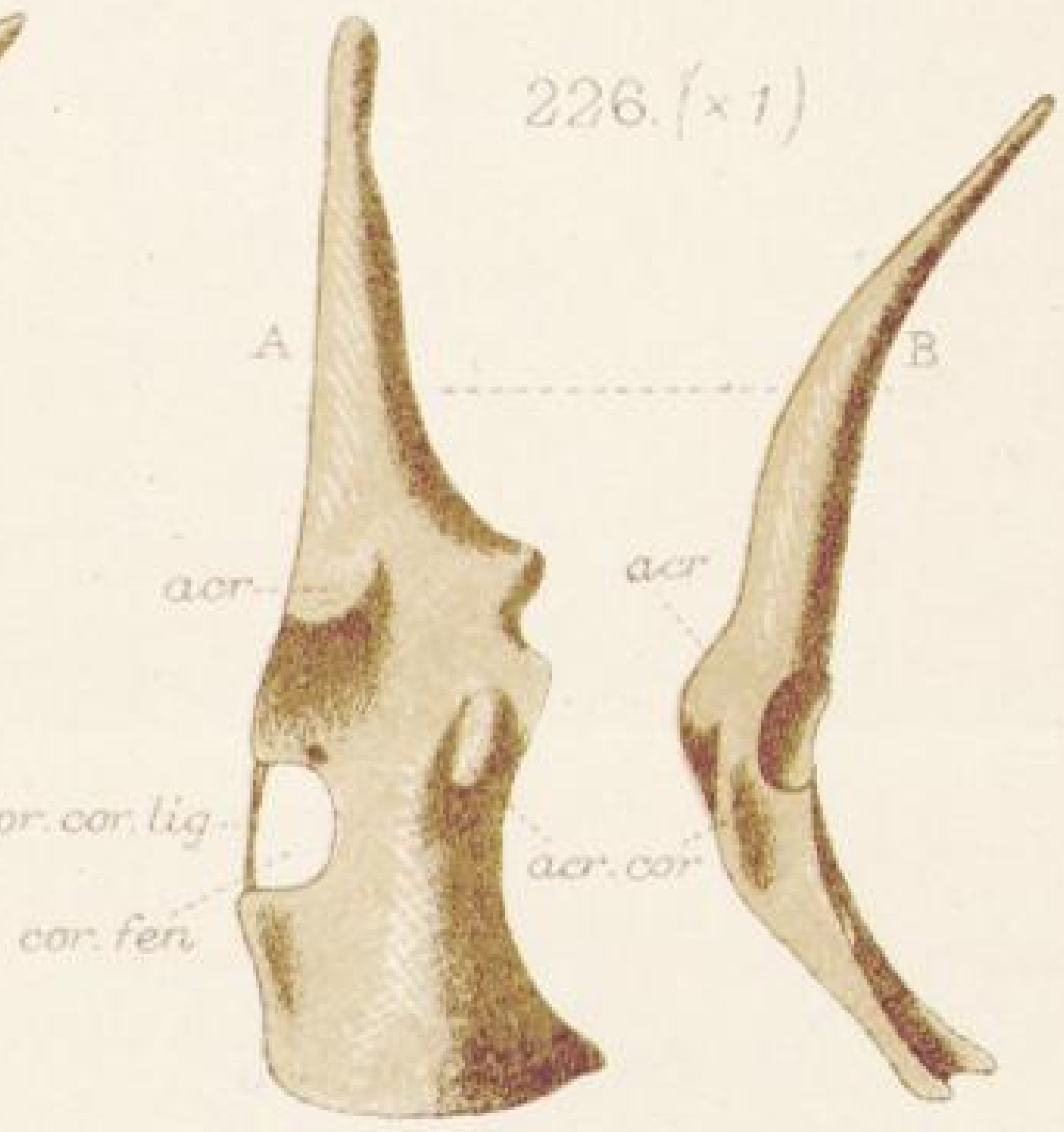

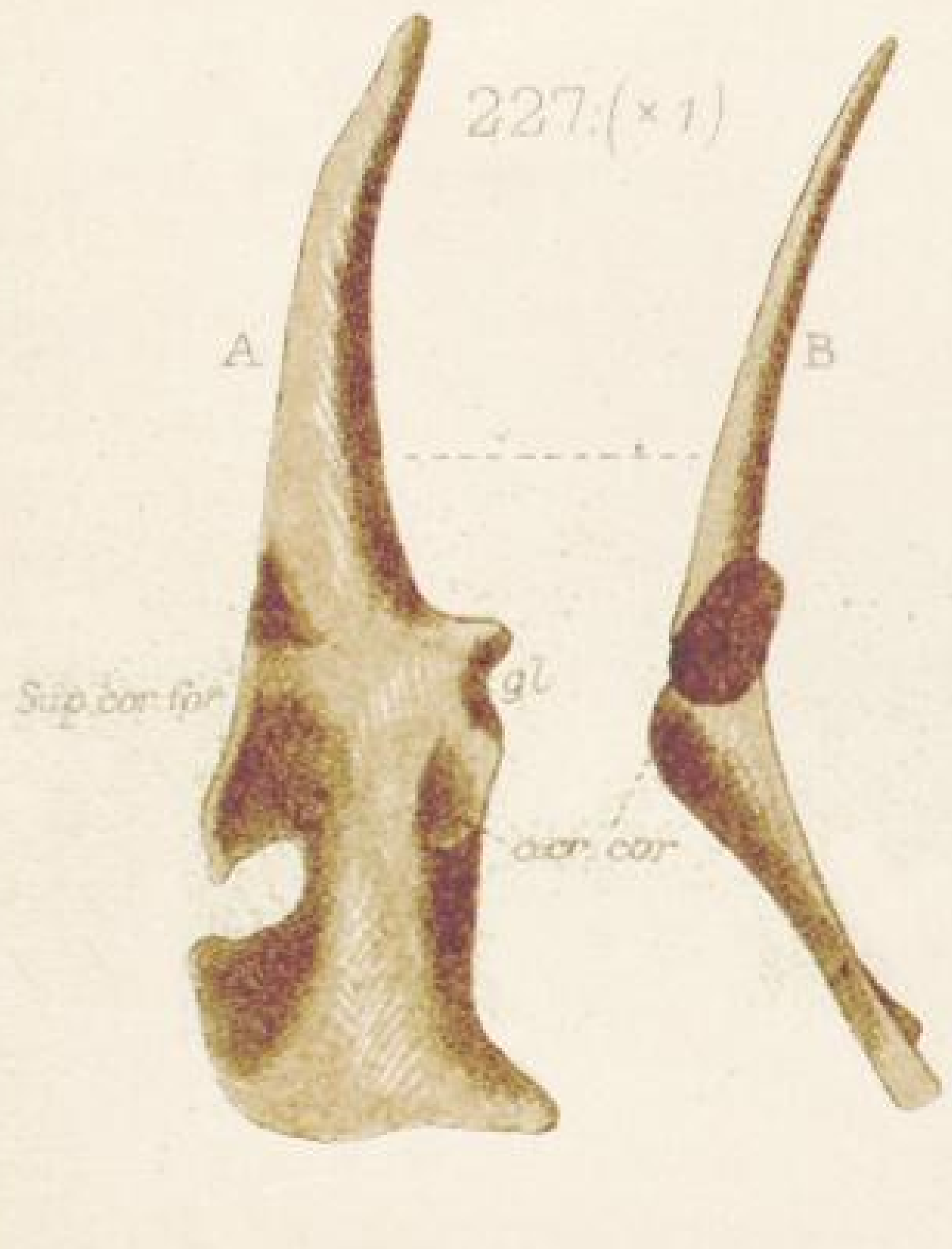

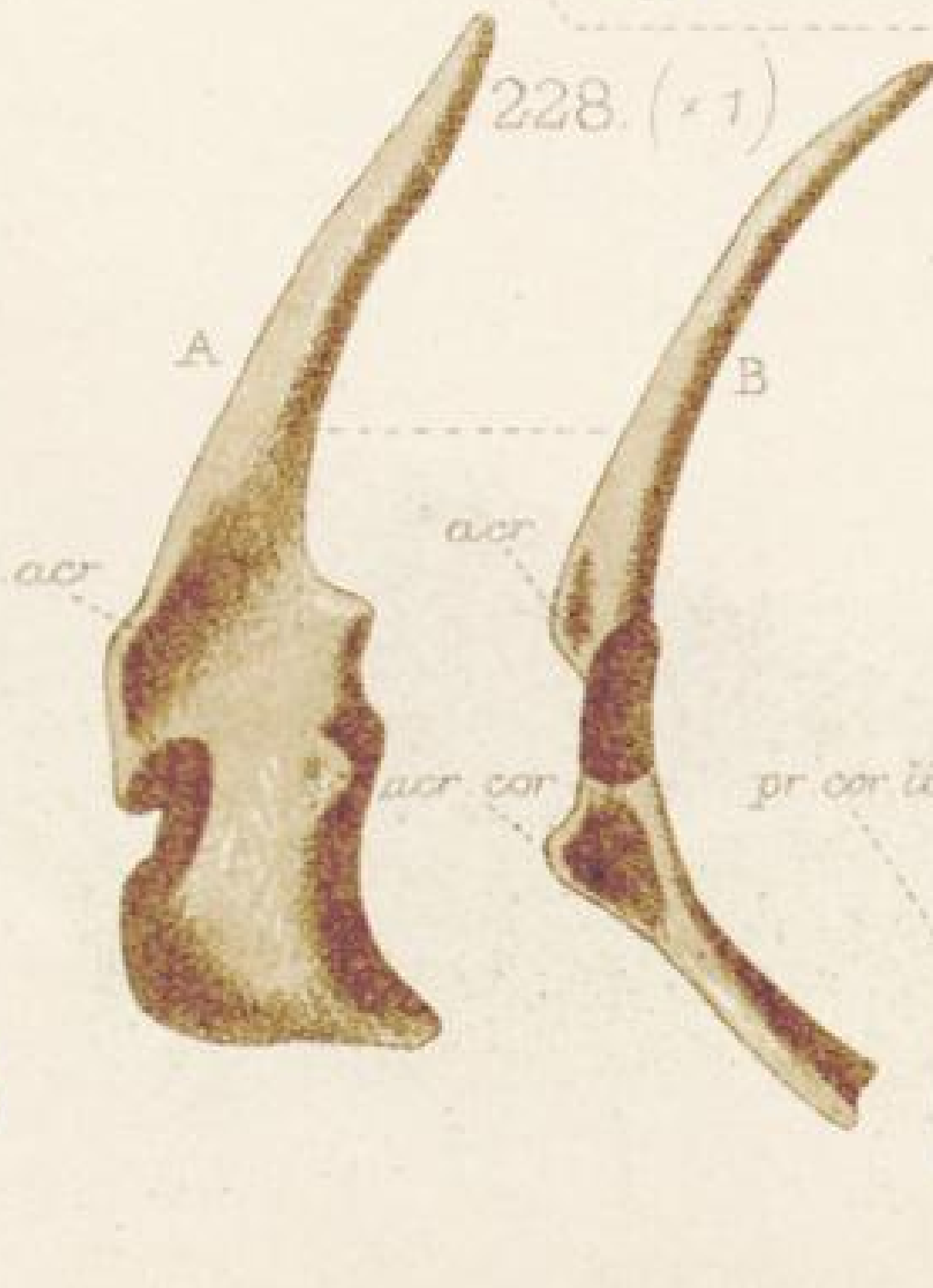

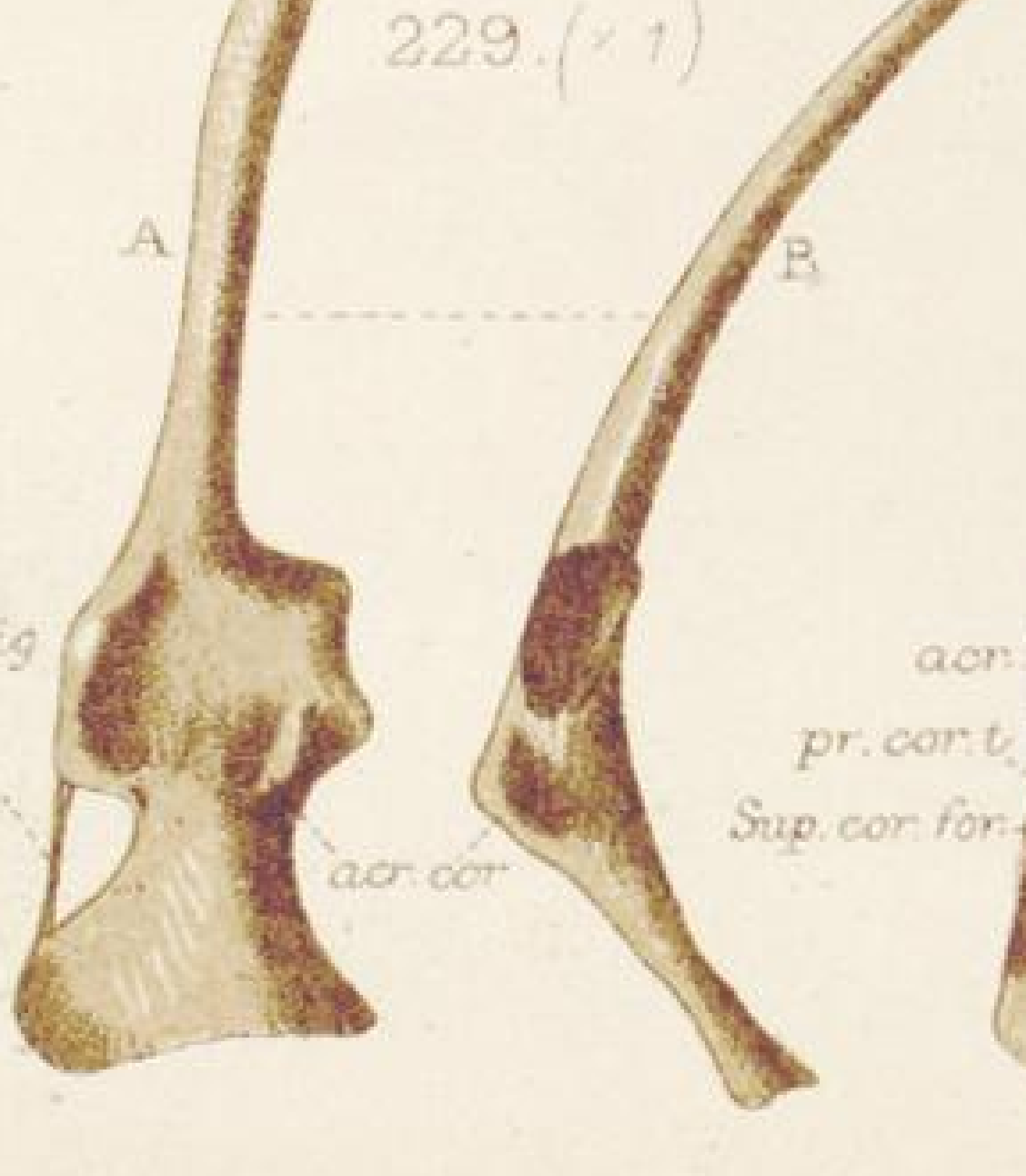

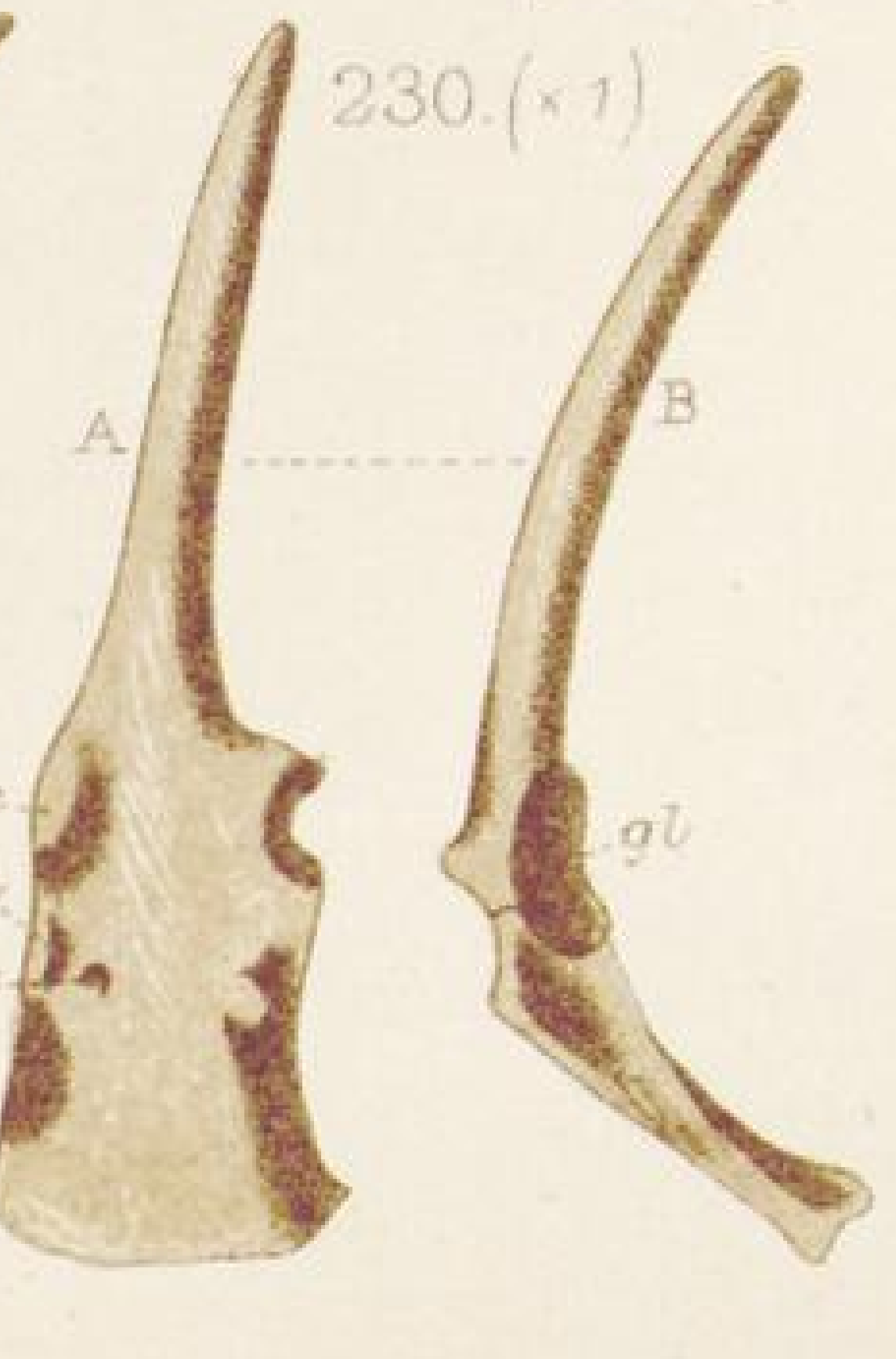

APTERYX Sternum and Shoulder-Girdle.

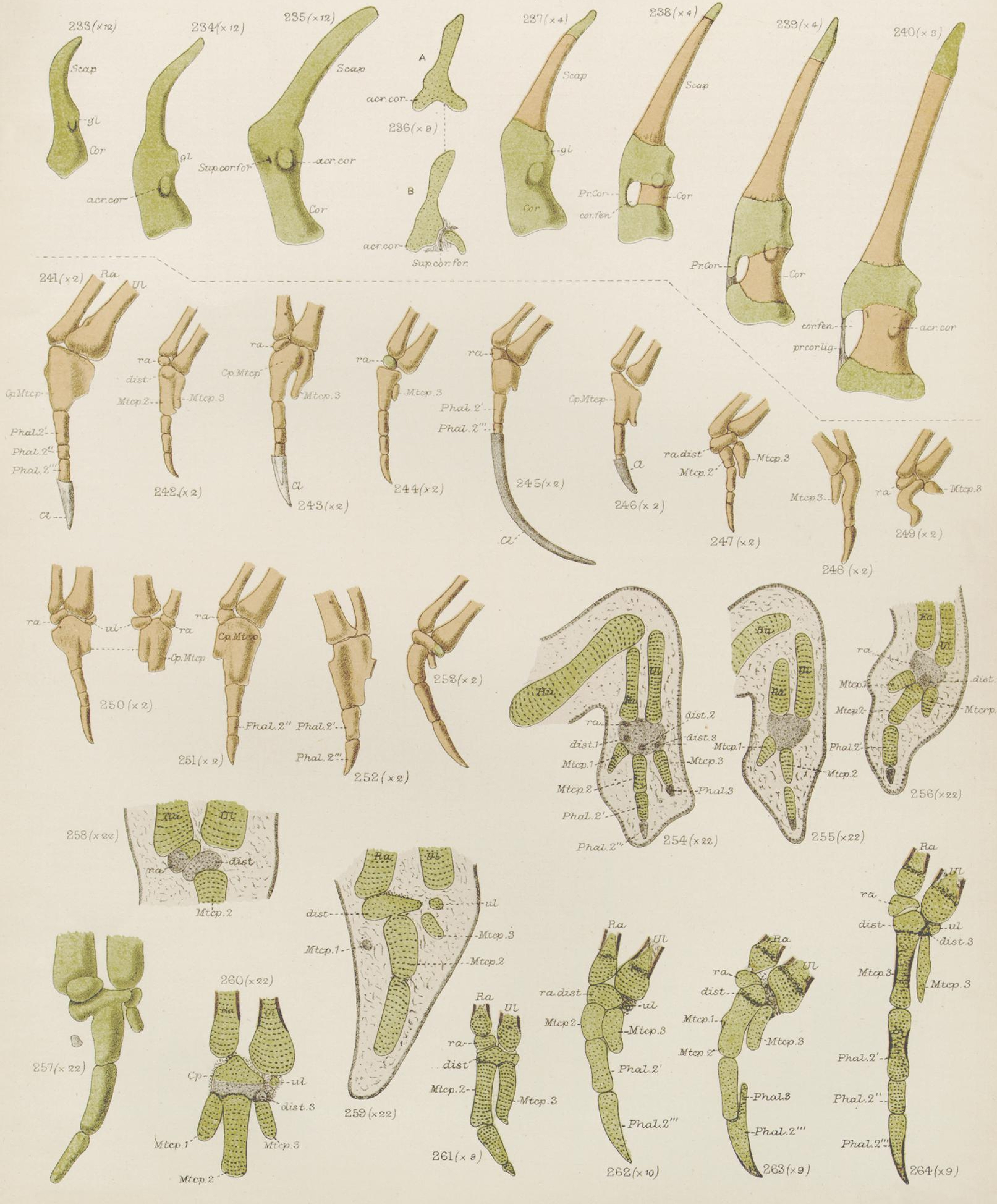

APTERYX. Shoulder-Girdle and Fore-limb.

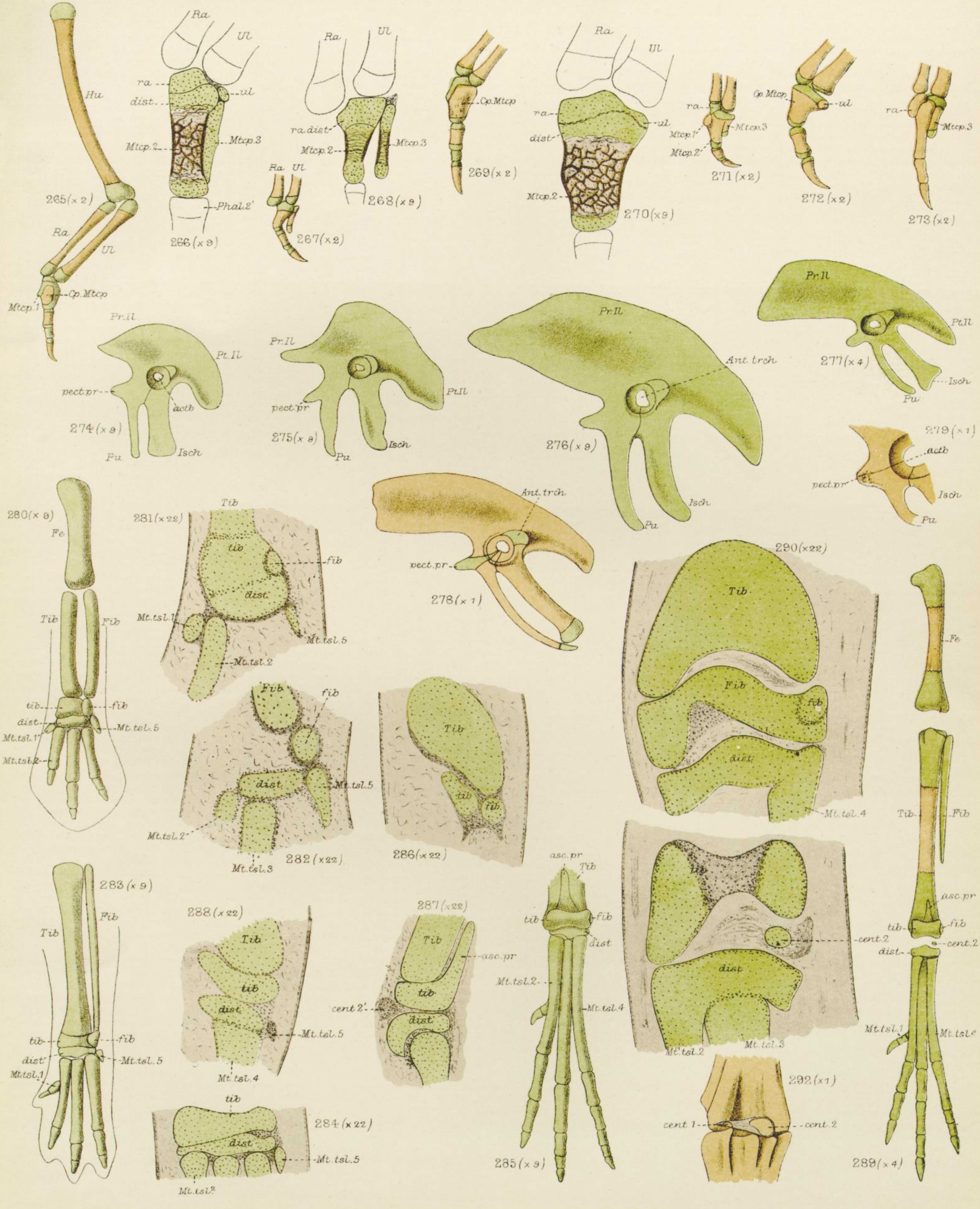

APTERYX. Fore-limb, Pelvic Girdle, and Hind-limb.

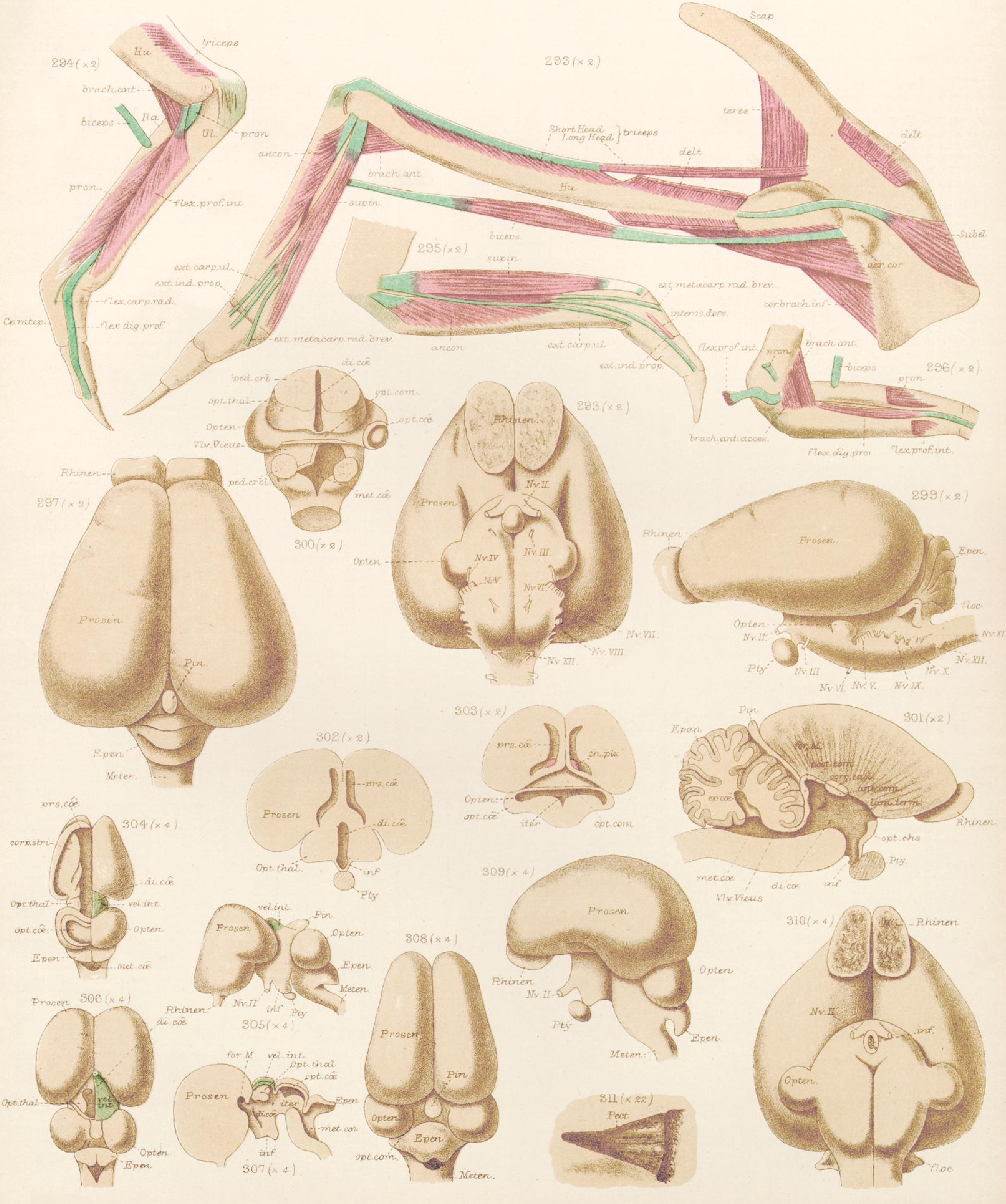

APTERYX. Muscles of Wing Brain, and Pecten.